

MMED DISSERTATION

TITLE

**SEROPREVALENCE OF ANTI-TOXOPLASMA IgG
ANTIBODY IN HIV PATIENTS WITH NEUROLOGICAL
MANIFESTATIONS**

By

**Dr. ABUCAR NOOR ALI FARAH
(MB BS)**

A Dissertation submitted to the University of Zambia in a partial fulfillment of the
requirement for the degree of Masters of Medicine in Internal Medicine

(School Of Medicine)
The University of Zambia
LUSAKA

July 2010


DECLARATION

I, *Dr. Abucar Noor A. Farah* do hereby declare that this dissertation represents my own work and has not been previously been submitted for any other degree, diploma or any other qualification at this or any other University.

A handwritten signature in cursive script, appearing to read 'A. Farah', written in black ink.

Signed

(Candidate)

A handwritten signature in cursive script, appearing to read 'Dr. A. Farah', written in black ink.


Signed

(Supervisor)

APPROVAL PAGE

This dissertation of **ABUCAR NOOR ALI FARAH** has been approved as fulfilling the requirements or partial fulfillment of the requirements for the award of Master of Medicine in **Internal Medicine** by the University of Zambia on the **13th of July 2010**


Dr B Andrews
External examiner




Dr S Lakhi
Internal examiner




Dr G Silumbe
Internal examiner




Prof Atadzanov
Observer



Dr O. Chiyenu
Observer



Dr N. Lambwe
Observer



DEPARTMENT OF INTERNAL MEDICINE

ABSTRACT

Neurological complications of HIV disease secondary to opportunistic infections are significantly common. At least one third of patients with advanced HIV disease will present with neurological complications possibly secondary to opportunistic Infections such as Cerebral Toxoplasmosis.

In patients with the acquired immunodeficiency syndrome (AIDS), toxoplasmic encephalitis (TE) is usually a presumptive diagnosis based on positive anti-toxoplasma Antibody (Ab), clinical manifestations and characteristic neuroradiological abnormalities.

One hundred and nineteen patients were recruited in to this study; all of the participants were sero-positive for HIV, with a history suggestive of opportunistic infections of CNS or obvious neurological symptoms and signs such as headache and confusional state, meningeal irritation, cranial nerve deficits, adult onset seizures and hemiplegia. The aim of the study was to determine seroprevalence of anti-toxoplasma IgG Ab in HIV/AIDS patient with neurological manifestations, and to establish a rational means for the clinician facing decision making concerning empiric anti-toxoplasma therapy.

The Study was conducted between November 2008 and January 2009 at the University Teaching Hospital, a major teaching hospital in Lusaka, Zambia, that still offers out-patient as well as inpatient health care to a wide spectrum of population.

The study looked at male and female HIV positive adults regardless of whether or not they were on treatment with Highly Active Anti-retroviral therapy (HAART), who presented with central nervous system manifestations/ abnormalities.

After obtaining informed consent from the participant or next of kin, history was obtained including demographic factors and anti-retroviral therapy state. Clinical examination was conducted for every participant with special emphasis on neurological examination. Blood samples were collected for serology test for Anti-toxoplasma IgG Ab using TOXO Direct Latex which is rapid slide agglutination procedure, developed for the direct detection of Anti-toxoplasma Ab in human serum.

The seroprevalence of toxoplasmosis was 11.8%, total number of specimen tested were 119 with frequency of 105 negative (88.2%) and 14 positive (11.8%).

The majority of the patients were males 61(52.6%), the total number of female participants was 55 (47.4%).

Most of the patients 94 (79.0%) were HAART naïve/pre-HAART, and 25 (21.0%) were on HAART.

Common clinical manifestations of the patients enrolled were headache, neck-ache/stiffness, confusion, convulsion, fever and focal neurological lesions (hemi-plegia & cranial nerve deficit).

Seroprevalence of toxoplasma was quite low as compared to other studies though this could be explained by the small sample size. Further investigations were warranted to determine the diagnostic ability of utilizing the toxoplasma Ab test

DEDICATION

This dissertation is dedicated to my late maternal uncles **Advocate Omar Haji Bod, Dr.Hussein Haji Bod** and my dad **Noor Ali Farah**, many debts of gratitude to these men who has shaped my life.

ACKNOWLEDGEMENTS

I would like to thank my supervisors, Drs Shabir Lakhi, and Peter Mwaba who gave their time and expertise to advise me during the writing of this work.

I would also like to acknowledge Dr Ben Andrews for all the assistance provided to me.

Finally last but not the least my wife and my children for this work was on their time.

TABLE OF CONTENTS

DECLARATION	ii
APPROVAL	iii
ABSTRACT	iv
ACKNOWLEDGEMENTS	vi
DEDICATION	vii
Table of Contents	viii
ABBREVIATIONS	ix
BACKGROUND	1
STUDY JUSTIFICATION	5
RESEARCH HYPOTHESIS	6
OBJECTIVES GENERAL & SPECIFIC	6
LITERATURE REVIEW	7
RESEARCH METHODOLOGY	18
RESULTS	24
DISCUSSION	27
LIMITATIONS OF THE STUDY	30
CONCLUSIONS AND RECOMMENDATIONS	31
REFERENCE	32
PATIENTS INFORMATION SHEET	40
CONSENT FORM	43
ETHICAL APPROVAL	44

FIGURES and TABLES

Figure 1.	Life cycle of <i>Toxoplasma gondii</i>	7
Figure 2.	Algorithm for testing serum for the presence of <i>Toxoplasma</i> IgG.	13
Table 1	CNS Manifestations of AIDS	3
Table 2.	Patient characteristics	24
Table 3.	Frequency of clinical findings	25
Table 4.	Clinical findings of 10 patients with positive <i>Toxoplasma</i> IgG	25
Table 5.	Association of <i>Toxoplasma</i> IgG positivity with clinical and demographic variables	26

ACRONYMS

AIDS	Acquired Immune Deficiency Syndrome
Ab	Antibody
ART	Anti-Retroviral Therapy
CAT	Cryptococcus Antigen Test
CDC	Centre for Disease Control
CD4	Cluster of differentiation. Located on the Cell surface of lymphocyte that is important in determining the recognition of antigen
CNS	Central Nervous System
CRAG	Cryptococcal Antigen test
CT SCAN	Computed Tomography
CXR	Chest X-Ray
TE	Toxoplasma Enecephalitis
FBC	Full Blood Count
ESR	Erythrocyte sedimentation rate

HAART	Highly Active Anti-retroviral Therapy
IgG	Immunoglobulin G. protein, a product of mature plasma cell
LFT	Liver function test
MRI	Magnetic resonance imaging
O Is	Opportunistic infections
P/HAART	Pre-HAART
PCNSL	Primary central nervous system lymphoma
RPR	Rapid plasma reagin
TAT	Toxoplasma Antibody Test
T. Gondii	<i>Toxoplasma Gondii</i>
TMP – SMX	Trimethoprin – Sulfamethoxazole

CHAPTER 1: INTRODUCTION

1.0 BACKGROUND

Central nervous system is a major target organ for HIV infection. Neurological disease is the first manifestation of symptomatic HIV in roughly 10 – 20 % of patients, while about 60% of patients with advanced HIV disease will have clinically evident neurological dysfunction during the course of their illness (levy *et al.*, 1985).

The Lente viruses are characterized by their tendency to follow a chronic course of disease, a long period of clinical latency with involvement of central nervous system (Barret, 2007).

There are two major targets of HIV – the immune system and the central nervous system. In addition to the lymphoid organs such as lymph nodes, the virus is localized, and infected the T cells that reside at these locations. The macrophages and cells belonging to the monocytes and macrophage lineage (microglia) in the brain are infected with HIV.

The likelihood of a particular neurological syndrome correlates with the clinical stage of HIV infection as reflected by viral load, immune response and CD4+ lymphocyte counts (Barret, 2007). This in turn, is related to the severity of immunodeficiency and autoimmunity and to serum and tissue cytokine levels. The central nervous system disorders in the setting of HIV disease categorically are:

- Primary infections of the brain by HIV,
- Opportunistic infections by parasites, fungi; viruses; bacteria; and
- Neoplasm (James, 2001).

Progressive immuno-suppression in HIV-infected patients is associated with a wide variety of opportunistic infections. Characteristically, most of them occur at late stage and in advanced HIV infection, when CD4+ count is less than 100/mm³. At least one third of patients with advanced HIV disease will present with a neurological complications possibly secondary to opportunistic infections, especially in the sub-Saharan Africa. As HIV/AIDS become a more chronic, otherwise manageable disease, current evidence indicates that central nervous system complications due to HIV/AIDS will increase in significant as a cause of major morbidity and mortality (Hoffman *et al.*, 2006).

Global cerebral diseases can present with altered mental status or generalized seizures, where as Focal disease often produce hemi-paresis, hemi- sensory loss, visual field impairment, or disturbance in language use. Fungal, viral, and mycobacterium meningo-encephalitides are the most common causes of global cerebral dysfunction where as progressive multifocal leucoencepalopathy (PML), primary central nervous system lymphoma (PCNSL), and toxoplasma encephalitis (TE) accounts for the majority of focal presentations.

In developed countries opportunistic infections of central nervous system accounts for most of the reported neurological morbidity and mortality in AIDS patients. Toxoplasmosis, cryptococcal meningitis, and fulminant bacterial meningitis are among the most common CNS infections in HIV infected individuals in Africa. In the northern hemisphere, where antiretroviral drugs are relatively available, peripheral neuropathy and HIV associated cognitive dysfunction including AIDS dementia complex accounts for the greatest proportion of neurological disease burden.

The symptoms resulting from AIDS-related illness include almost all those related to nervous system dysfunction (Table 1). The common symptoms and signs associated with infectious clinical presentations, serology and results of neuro-imaging studies can aid in the diagnosis in patients with neuro-AIDS. For instance headache often accompanies the various types of meningitis, but also reported when no specific cause is determined (Price *et al.*, 1996). In determining the pathology of a patient with Brain disease due to HIV/AIDS, it is vital to find whether the patient's presentation is focal or Non-focal (Zumla *et al.*, 1991). The basic diagnostic approach is neuroanatomic localization. Most of the HIV/AIDS related CNS diseases have predilection for particular sites of the brain and spinal cord and therefore resulting anatomically defined picture.

Table I CNS Manifestations of AIDS (Rosenblum *et al.*, 1988)

- *Focal neurological lesions*
- *Headache & Neck stiffness*
- *Altered consciousness and cognition/Impairment alertness*
- *Focal and general Seizures (new onset)*
- *Focal neurological lesions*
- *Cranial nerve neuropathies*
- *Behavioral change.*

Common differential diagnosis of focal brain disease in HIV/AIDS is Toxoplasmosis, progressive multifocal leucoencephalopathy (PML), and Primary CNS Lymphoma (PCNSL). Other lesions include tuberculous meningitis (TBM) and cryptococcoma (Naveet *et al.*, 1985).

Depending on the advancement of immunosuppression, toxoplasmosis and lymphoma usually present with advanced HIV disease where as tuberculosis in earlier HIV disease.

This study was carried to determine the sero-prevalence of *Toxoplasma gondii* antibodies among HIV-infected patients with neurological abnormalities so that the prevalence of toxoplasmosis could be inferred at University Teaching Hospital (UTH).

1.1: STUDY JUSTIFICATION

It is presumed that the incidence of CNS Opportunistic Infections in HIV/AIDS patients admitted to the University Teaching Hospital (UTH) is high.

There are large numbers of patients presenting with features suggestive of Central Nervous System dysfunction secondary to HIV/AIDS related opportunistic infections such as cerebral toxoplasmosis among other infectious neuro-AIDS. Most of these patients have been diagnosed mainly on clinical grounds, with some supported by lab evidence such findings in cerebrospinal fluid (CSF) analysis for anti-toxoplasma Ab, Cryptococcal antigen CRAG, few with C-T Scan findings and substantial number of these cases confirmed by empirical therapy of the suspected strain.

A Study has yet to be carried out to evaluate or determine the role of anti-Toxoplasma IgG for patients presenting with HIV/AIDS related neurological deficit which is less invasive, affordable and faster test.

It will also help to determine the proportion of HIV patients with neurological manifestations and who are positive for IgG Ab for Toxoplasma. More importantly empirical cerebral toxoplasmosis therapy might be recommended in a patient who has not been receiving effective prophylaxis for Toxoplasma, and clinically presents with focal neurological lesion and low CD4 count.

Currently the diagnosis of Cerebral Toxoplasmosis is based presumptive without any lab support, apart from clinical suspicion; therefore, Serology can be a useful method. In the same vein we can also avoid unnecessary treating patients without minimum lab evidence.

1. 2: RESEARCH HYPOTHESIS

Toxoplasmosis is one of the major causes of CNS manifestations in HIV/AIDS patients at UTH.

1.3: GENERAL OBJECTIVE

- To establish seroprevalence of Anti-toxoplasma IgG Ab in HIV/AIDS patient with neurological manifestations.

1.4: SPECIFIC OBJECTIVES

- To determine the proportion of HIV/AIDS patients with Neurological manifestation who are positive for Anti-toxoplasma IgG Ab.
- To detect clinical characteristics of cerebral toxoplasmosis in HIV infected patients
- To clarify diagnostic role for detection of Antibody to *toxoplasma gondii* in the serum
- To determine whether certain demographic variables have bearing the seroprevalence of Anti-toxoplasma IgG Ab in HIV patients with Neuro-Aids.

CHAPTER 2. LITERATURE REVIEW

Toxoplasmosis

2.1: Natural History

Toxoplasma gondii is an obligate intracellular protozoan and causes zoonotic infection. The life cycle of *Toxoplasma* (Fig. 1) was described only in 1970, when it was discovered that the definitive hosts are members of the family felidae, including domestic cats (J. P. dubey *et al.*, 1988) *Toxoplasma Gondii* is transmitted by three known mode: Congenitally, through the consumption of undercooked Meat, & via Fecal matter.

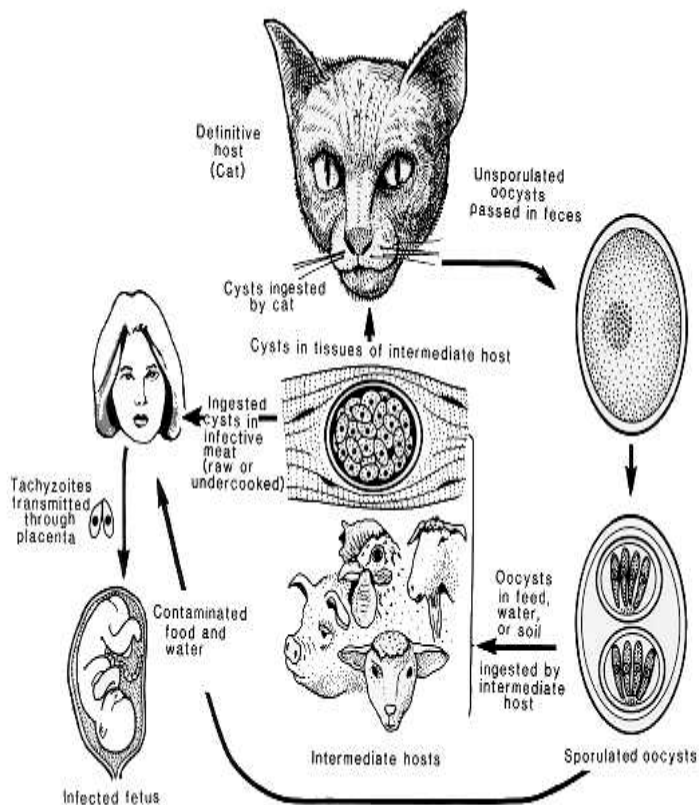


Figure I. Life cycle of *Toxoplasma gondii*.

From Dubey JP, Toxoplasmosis. J Am Vet Med Assoc 189:166, 1988

With the advent of the Human Immunodeficiency Virus (HIV) pandemic, toxoplasma encephalitis has become one of the frequent opportunistic infection and the most common cause of focal brain lesions, complicating the course of AIDS (Veeranoot Nissapatorn *et al.*, 2004, Luft *et al.*, 1992, israelski DM, in Sande *et al.*, 1992). It has been reported that Toxoplasmosis is the commonest opportunistic infection in HIV/AIDS patients in the developed world (Winstanley P *et al.*, 1995, McCabe-R *et al.*, 1993).

In US 10-40% of adults with AIDS are seropositive for Toxoplasmosis (Partisani M. *et al.*, 1991). In Europe, Latin America and Africa the incidence of latent toxoplasma infection is between 75% - 90%, so the number of AIDS patients who develop toxoplasmic encephalitis may be 3 -4 times more than US (Raffi F. *et al.*, 1997).

After an acute infection with the organism there is development of immunity which controls the infection but does not eradicate, and the protozoan remains latent. When favorable condition develops which is the fall of immunity, the immune-suppressed individuals such as HIV/AIDS patients are at risk for reactivation of the infection and primarily manifest as TE.

The commonest manifestation in HIV infected patients is encephalitis, and always it is due to reactivation of latent infection as a result of progressive loss of cellular immunity, although pneumonitis and chorioretinitis can occur. Most of the cases occur when the CD4 count is less than 100/mm³ (John G. Bartlett, 2007; Schnapp *et al.*, 1992; Friedman *et al.*, 1990; Grant I *et al.*, 1990)

2. 3: Patho-physiology

CNS Toxoplasmosis results from infection by the intracellular parasite *Toxoplasma Gondii*, due to reactivation of old CNS lesions or to haematogenous spread of a previously acquired infection, rarely it results from primary infection (Suur Biliciler, 2005).

The parasite can attach to any host cell in the body except non-nucleated RBCs, and they can become invaginated, forming a parasitophorous vacuole in which the organism resides.

Cats and other members of the definite hosts, sexual reproduction leads oocyst development in the intestinal lining. These oocysts are infective, and infection may occur when human-beings ingest (or any secondary host) ingest the oocysts. After intestinal transit, parasitemia and widespread dissemination occur throughout the body. This acute phase is followed by a latent phase during which encystation occurs in various tissues, particularly in the brain but also in the cardiac and skeletal muscles. Once within the host tissue, asexual multiplication ensues.

In AIDS, patients are at particular risk for developing disseminated toxoplasmosis, which more often manifests as central nervous system abnormalities, such as encephalitis, focal brain lesion (Ali Nawaz Khan, 2004).

The mechanism by which HIV induces susceptibility to opportunistic infection including toxoplasmosis is likely to be multiple. These include depletion of CD4 T cells; impaired production of IL - 2, IL - 12 and IFN - gamma; and impaired cytotoxic T-Lymphocyte activity (Cohen O *et al.*, 1999).

Cells from HIV infected patients exhibit decreased in vitro production of IL - 12 & IFN - gamma in response to *Toxoplasma gondii* (Murray HW *et al.*;

1984, Subauste CS, *et al.*, 1984). These deficiencies may play a role in the development of Toxoplasmosis associated with HIV infection.

2. 4: Clinical Presentation

Toxoplasma Encephalitis is one of the most common causes of focal brain lesions, even in underdeveloped countries where Tuberculosis is endemic. Bruce B James stated that "All focal brain lesions are cerebral toxoplasmosis until proved otherwise". About 50 to 60% of patients complain or demonstrate focal neurological symptom and signs (Murray, 1999). Occasionally, *Toxoplasma* may also present diffuse encephalitis (Renold *et al.*, 1992).

It has been found that about a third of patients with HIV infection and latent *T Gondii* will develop Toxoplasmosis in its natural course.

Toxoplasmosis encephalitis presents as focal necrotizing encephalitis with one or more intra-cerebral mass lesion. It can also present as meningo-encephalitis.

Clinical manifestations include Focal deficit usually with Fever 70%, Headache up to 66%, occasionally confusion up to 40% and Seizure approximately 25% (John G. Bartlett *et al.*; 2007).

Although Pneumonitis and chorioretinitis can occur, the commonest manifestation in HIV infected patients is encephalitis and it is almost always due to the reactivation of a chronic infection (Schnap L, *et al.*, 1992; Friedman AH, *et al.*, 1990; Grant I *et al.*, 1990).

Other common clinical presentations of *Toxoplasma Encephalitis* are motor weakness, speech disturbance, Cranial nerve lesions, vision and sensory disturbances, cerebral and movement disorders and neuropsychiatry manifestations (Navia B A., *et al.*, 1986; Renard C., *et al.*, 1992).

The common sites of these lesions are the frontal and parietal regions of the brain, particularly the cortico-medullary junctions and the basal ganglia. The lesions may also occur in the temporal and occipital regions, cerebellum or thalamus, both the gray and white matter may be involved.

Uncommonly cerebral toxoplasmosis may be accompanied by Retinitis, Pneumonitis and disseminated disease.

Ophthalmologic examination reveals extensive whitish infraction and inflammation with minimal intra-retinal haemorrhage. Outer retinal involvement may show brush fire advancement of infection.

Other findings on ophthalmoscopic manifestations are multifocal, bilateral lesions that are confluent, thick and opaque than those caused by Cytomegalo virus (Rebound C., *et al.*, 1994; Mansour SE., 1997).

The pneumonia caused by *T gondii* is most often accompanied by fever and dyspnea rather than cough; therefore it is at times difficult to differentiate from pneumocystis jiroveci pneumonia (Okenhendler E., *et al.*, 1990).

In addition to that patients may also present with fever, sepsis like syndrome with low blood pressure, disseminated intravascular coagulation, increased lactic dehydrogenase and pulmonary infiltrates (Reebaud, *et al.*, 1994; Oksenhendler E., *et al.*, 1990).

2. 5: Diagnosis

CDC criteria to diagnose clinical cerebral toxoplasmosis include:

- Clinical features of CNS involvement,
- Presence and rising of anti-toxoplasma IgG titers, &
- Typical CNS lesions on CT Scan/MRI (Raffi F., *et al.*, 1997).

A confirmed case (definitive diagnosis) requires identification of *Toxoplasma gondii* tachyzoites in brain samples obtained through biopsy or necropsy (CDC and prevention, 1993)

In clinical practice, the diagnosis of *Toxoplasma* encephalitis is usually made presumptively in an AIDS patient when CD4 count is less than 100 cells/mm³, positive *Toxoplasma gondii* IgG Abs, no recent prophylaxis against toxoplasmosis, and multiple ring-enhanced lesions on brain imaging (Howard M Heller, 2006).

Positive serologic results and Characteristic CT or MRI findings are indications for empirical therapy.

When an HIV/AIDS patient presents with focal neurological lesion, one approach is it is to investigate *T. Gondii*, and to have a baseline check for IgG antibody to toxoplasma (A. Zola *et al.*, 1991)

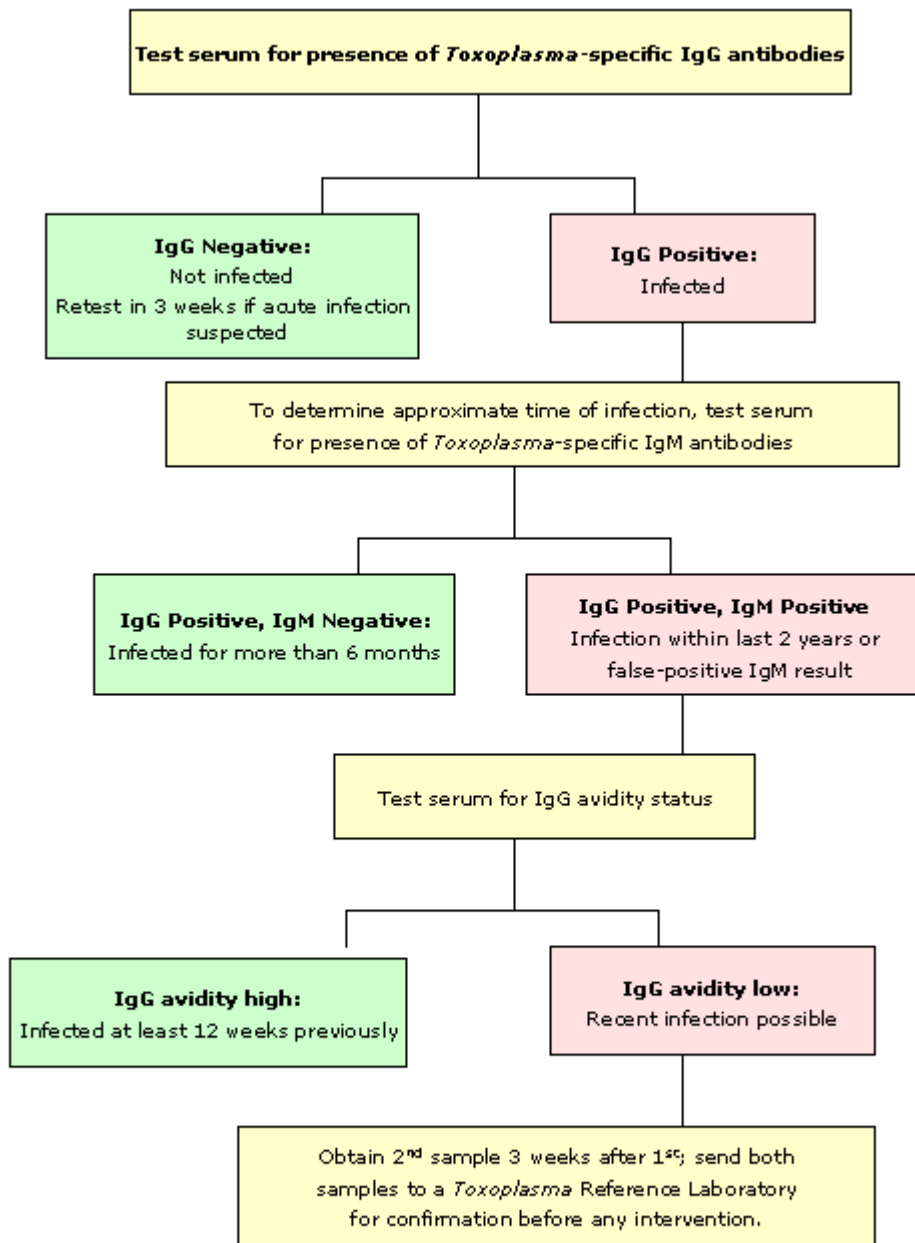


Figure 2. Algorithm for testing serum for the presence of *Toxoplasma* IgG. Clinical Use and Interpretation of Serology Tests for *Toxoplasma Gondii*. NCCLS document M36-A (ISBN 1 – 56238-523 – 2) USA, 2004

2. 6: Serological Detection of Antibodies

T. Gondii serology is useful to identify HIV- infected patients at risk for developing toxoplasmosis. HIV infected patients with *Toxoplasma* encephalitis are almost uniformly seropositive for anti-toxoplasma IgG antibodies (Derouin, *et al.*, 1996). Between 97% & 100% of HIV- infected patients with toxoplasmosis encephalitis have *Toxoplasma gondii* IgG antibodies (Grant, 1990).

Toxoplasmosis must be considered in the differential diagnosis in any immune-suppressed patient who has clinical evidence of damage of central nervous system. The organism is one of the most common latent infectious agents of man through out the world (Wistanley, 1992).

Toxoplasma Encephalitis should therefore be considered in patients with *Toxoplasma* IgG anti-bodies and CD4 count of less than 100 cells/mm³, who have presented with unexplained neurological disease (Kittredge, 2004).

Although a definitive diagnosis of cerebral toxoplasmosis requires the demonstration of parasites by histopathology other methods are more practical. Clinical and radiological data can be reliable. The role of immunological diagnosis is emphasized here, because it is less invasive, less costly, and rapid. A detection of toxoplasma-specific anti-body is the primary diagnostic method to determine infection with toxoplasma.

Reactivation of previously latent disease is usually the results of cerebral toxoplasmosis, therefore IgG Antibody detection is the first test to help determine if the lesions are related to toxoplasmosis (Brew, 2001).

Positive IgG titer of more than 1: 10 or 1 iu can be detected as early as 2 – 3 days after infection, reach maximum titer of 300 – 3000 iu with in two months, and then decline to new base line level that persist for life. It is necessary to measure the IgM titer together with the IgG titer to establish the time of infection. It appears that IgM appears with in a few days and reach a maximum titre with in four weeks. This test can turn negative 4 to 12 weeks. But IgM can be detected at very low titer, for months or even years in minority of patients, particularly with Elisa tests.

Toxoplasma serology assists in the diagnosis of patients presenting with neuro-AIDS, to identify patients for Toxoplasma prophylaxis, and those with sero-negative to be counseled on preventive measures. In patients with AIDS, presence of IgG and neurological findings consistent with toxoplasmosis are grounds for presumptive diagnosis (T. GONDII Ab levels in HIV infected pts for diagnosis of C. Toxopl., Microbiol. Inf. Diag).

The vast majority of patients with Toxoplasma encephalitis are seropositive for Anti-toxoplasma IgG Abs (Luft B J, 1984). Therefore, estimation of anti-toxoplasma IgG can be recommended as a screening test in all HIV/AIDS patients to detect latent infection. In patients with atypical radiographic findings or those with who are compliant with TMP/SMX prophylaxis, the positive predictive value drops considerably. It is rare for patients with toxoplasmosis to lack serum antibodies, a negative serology strongly argue against the diagnosis.

2. 7: Cerebrospinal Fluid (CSF)

CSF examination from a patient with cerebral toxoplasmosis may reveal mild pleocytosis of mononuclear predominance and protein elevation (Motoya JG, *et al.*, 2000).

The sensitivity of PCR test is extremely variable (11.5 to 100%), but specificity is high (96 to 100%) (Dupon *et al.*, 1995).

2. 8: Histological Findings:

Definitive diagnosis is made by open or stereotactic brain biopsy. Hematoxylin and eosin are used to demonstrate the organisms. In order to increase the diagnostic sensitivity immunoperoxidase staining is very useful (Howard M Heller; UpToDate, 2006).

Histologically there is Lymphocytic meningitis, individual cyst containing lesions. Astroglial and microglial nodules. Associated lymphocytic vasculitis, and diffuse encephalitis (Suur Billiciler, 2005).

2. 9: Neuro-radiological Studies

For the management of patients with TE imaging studies of the brain are essential. Computed tomography (CT) scan reveals multiple, bilateral, hypodense, contrast-enhancing focal brain lesions in 70 – 80% of patients (Post MJ, *et al.*, 1985; Levy RM, *et al.*, 1986).

These lesions tend to involve the basal ganglia and hemispheric corticomedullary junction. Contrast enhancement often creates a ring like pattern surrounding the lesion. Toxoplasma encephalitis may less frequently present with a single lesion or without a lesion on CT scan.

MRI is more sensitive than the CT scan and it is more preferable especially patients without focal neurologic abnormalities (Levy RM, *et al.*, 1990; Ciricillo SF, *et al.*, 1990).

TE can at times or occasionally cause a single brain lesion on MRI; such findings suggest an alternative diagnosis such as PCNSL (Ciricillo, *et al.*, 1991).

2. 10: Treatment

In patients with AIDS, presence of IgG and neuroradiological findings consistent with Toxoplasmosis are grounds for a presumptive diagnosis (Hellerbrand C, *et al.*,1996); and good therapeutic response is improvement of clinical condition, regression of neurological signs and symptoms, or improvement of CT scan (V Nissapatorn, *et al.*, 2003).

The standard treatment for Toxoplasma encephalitis is a combination of: Pyrimethamine and Sulphadiazine (South African Department of Health. Recommendations for the prevention & Treatment of Opportunistic & HIV related Diseases in adults. Directorate: HIV/AIDS & STDs. October 2000).

CHAPTER 3 METHODOLOGY

3.1: RESEARCH METHODOLOGY

3.0: Study Design

A cross-sectional study was carried out.

Study participants were recruited mainly from Internal medicine main admission ward, some from filter clinic and in-patient medical wards at the university teaching Hospital, Lusaka, a major referral hospital. The study included patients who presented with central nervous system manifestations of HIV/AIDS.

Approval was sought and obtained from the Research Ethics committee & University Teaching hospital management. Patients or next to their kin signed an informed consent.

Data was also collected on individual characteristics. In this way cross-sectional study has provided a Snap-shot of the out-come, at specific point in time.

3.1: Study Site

The study was carried out at the University Teaching Hospital (UTH), a tertiary hospital with 1863 bed capacity.

Patients were recruited from the Main admission ward, Medical wards, and Medical clinic.

3.2: Case Definition

The definition for cerebral toxoplasmosis case was adopted from the CDC. To diagnose clinical cerebral toxoplasmosis include:

- Clinical features of CNS involvement,
- Presence and Raised anti-toxoplasma IgG titers, &
- Typical CNS lesions on CT Scan/MRI.

A confirmed case required identification of *Toxoplasma gondii* tachyzoites in brain samples obtained through biopsy.

The presumptive case required:

- Recent start of the neurological abnormalities consistent with intracranial disease or alteration on the level of consciousness,
- Evidence in the imaging CT or MRI of a brain lesion with mass effect or with highlight after injection of contrast substance or both findings,
- Positive anti-toxoplasma IgG antibody,
- Response to anti- toxoplasma –specific treatment.

3.3: Study Population

Study population was patients of 18 years of age and above.

Patients with HIV test reactive with Central Nervous System Manifestation.

3. 4: Sample Size

Sample size was calculated using the following formula:

$$SS = \frac{Z^2 * (p) * (1-p)}{C^2}$$

Where:

Z = Z value (e.g. 1.96 for 95% confidence level)

p = percentage picking a choice, expressed as decimal
(.5 used for sample size needed)

c = confidence interval

The confidence interval chosen was estimated using a confidence level of 95 percent and a percentage likelihood of a person falling within the expected category of 50 percent. This percentage was chosen as the most conservative choice given no previously estimated value. The result was a confidence interval of 4.25.

Using this confidence interval, confidence level and population size, a sample size of 200 was calculated.

Reference: *The Survey System*. <http://www.surveysystem.com/sample-size-formula.htm>

3.5: Inclusion Criteria

- Adult Zambian of 18 years and above with advanced HIV infection,
- Patients presenting features suggestive to neuro-aids:
 - Focal neurological lesion – Hemi paresis, Hemi sensory loss,
 - Headache and neck-ache,
 - Focal and generalized seizures (adult on-set),
 - Cranial nerve neuropathy,
 - Confusion and Fever

3.6: Exclusion Criteria

- Patients who were negative HIV test
- Patients below 18 years of age with or without HIV test positive
- Patients who were suffering from hypertension, diabetes and history of Stroke
- Patients presumptively diagnosed or suspected with other CNS Opportunistic infections

3.7: Laboratory

3.7.1: LATEX AGGLUTINATION TEST

2 mls of sera were drawn or collected from each patient. No special preparation of the patient was required prior to sample collection. Fresh serum was used for testing, and in case of delay in testing, we stored the sample at 2 – 8° c for up to 48 hours. The sample was analyzed for the presence of IgG Antibodies to *T Gondii*. After this particular test the sample was destroyed and never used for any other purpose apart from the consented research.

Principal: Latex particles coated with *T Gondii* antigens agglutinate when mix with serum containing Abs to *T Gondii*. Agglutination was absent when Abs to *T Gondii* was absent. When compared with an indirect

immunofluorescence assay, the latex test had a sensitivity of 94% and specificity 100%. (Gull Foundation for Medical Research, Gull Research Park, Salt Lake City, UTAH). When compared with an enzyme-linked immunosorbent assay, the latex test had 86% sensitivity and 100% specificity.

Test Procedure: Bring reagent and samples to room temperature before use. Dilute sample to be tested 1:16 with 0.9% saline (0.1 ml serum + 1.5ml of 0.9% saline).

Clarification: Markedly lipemic, haemolysed and contaminated serum samples could give rise to non-specific result. Use of plasma rather than serum can lead to false positive results. It is recommended that results of the tests should be correlated with clinical findings to arrive at the final diagnosis. Other screening tests for anti-Toxoplasma IgG Abs are the Sabin Feldman dye test (DT), which is currently the serological test of choice in the west, although it is technically demanding.

3. 8: Data Collection

A detailed clinical history preceding thorough neurological examination was carried to each and every participant. Laboratory form was used to capture results of investigation – Latex Agglutination Test for *T Gondii* Abs.

3. 9: Data Analysis

The data was entered into excel worksheet and analyzed by means of statistical package (EPI INFO 6). Descriptive analysis was performed for the following variables - Mean & standard deviation for age, frequency for sex, & habits. T-test was used to asses significance continuous variables and chi-square for categorical variables. Univariate & multivariate logistic regression analysis was used to asses association of Cerebral Toxoplasmosis – Clinical, and Laboratory.

3. 10: ETHICAL CONSIDERATION

Ethical approval was sought from the Research Ethics Committee of the University of Zambia, as well as University Teaching Hospital Management. Informed and signed consents was obtained from the patient where this was practical. Spouses, and guardian or next to kin were utilized where the patient was not oriented. Merits & demerits of participating in the research were explained to the subjects and care was not compromised if permission was not granted to participate.

CHAPTER 4: RESULTS

4. 0: General Description of the Results

A total of 120 study subjects gave their consent to participate in the study, but 119 were considered for analysis due to missing data. 14 samples tested positive Toxoplasma IgG Ab and remaining 105 samples were negative, giving a seroprevalance rate of 11.9%.

Table 2 summarizes the patients' baseline demographic characteristics at the time of the study. Age range was between 19 to 55 years, of which mean age was 34.3. Most of the patients enrolled for the study were males with frequency of 61 (52.6%). The number of participants who were HAART naïve was 94 (79%) and those on HAART were 25 (21%).

Table 2. Patient characteristics

Age*, mean (SD)	34.3(8.6)
Sex^, n (%)	
Male	61 (53)
Female	55 (47)
On HAART?, n (%)	
No	94 (79)
Yes	25 (21)

* Age data only available for 102 patients

^ Gender data only available for 116 patients.

The most common neurological abnormality was headache (60.8%), followed by neckache/stiffness, confusion, fever, convulsions, hemiplegia, and cranial nerve palsy. Most of the patients presented with more than one clinical abnormality (see Table 3).

Table 3. Frequency of clinical findings

Clinical finding	N	Percent
Headache	73	60.8
Neck-ache/stiffness	49	40.8
Confusion	37	30.8
Fever	23	19.2
Convulsions	19	15.8
Hemiplegia	9	7.5
Cranial nerve palsy	7	5.8

Anti-toxoplasma IgG status was only available for 119 patients. Fourteen of 119 patients had a positive serum IgG (11.8%, 95% CI 6.6 – 19.0%). Clinical findings were recorded for 10 of the 14 patients with positive Anti-toxoplasma IgG (see Table 4). Only one patient with positive serology was on HAART.

Table 4. Clinical findings of 10 patients with positive toxoplasma IgG.

	Age	Sex	Signs and symptoms	On HAART
1	35	M	Confusion	No
2	48	M	Confusion, fever	No
3	20	F	Headache, neckache	No
4	44	M	Headache,	No
5	35	F	Headache, Blurring of vision	No
6	35	M	Headache, fever	No
7	35	M	Headache, fever	No
8	30	F	Headache, fever, seizures	No
9	39	F	Neck stiffness	No
10	31	M	Rt sided Hemiplegic, neckstiffness	Yes

Age, sex, and clinical presentation were not available for four additional pre-HAART patients with positive IgG.

Association between Toxoplasma IgG serostatus and epidemiologic and clinical features was assessed (Table 5). For patients not on HAART, there was a trend towards higher prevalence of positive toxoplasma IgG (OR 3.85), but this was not statistically significant. For patients with headache (OR 0.44), neckache (OR 0.36), confusion (OR 0.35), or convulsions (OR

0.37), there were trends towards lower prevalence of toxoplasma seropositivity, but these, too, were not statistically significant.

Table 5. Association of Toxoplasma IgG positivity with clinical and demographic variables

	Toxo Ab + n=14	Toxo Ab - n=105	Odds Ratio (95% CI)
Age*	35.2 (7.7)	34.2 (8.7)	---#
Sex^			
Male	6 (60)	54 (51)	1.42 (0.38 – 5.31)
Female	4 (40)	51 (49)	
On HAART?			
No	13 (93)	81 (77)	3.85 (0.48 – 31.0)
Yes	1 (7)	24 (23)	
Clinical findings			
Headache	6 (43)	66 (63)	0.44 (0.14 – 1.37)
Neckache/stiffness	3 (21)	45 (43)	0.36 (0.10 – 1.38)
Confusion	2 (14)	34 (32)	0.35 (0.07 – 1.64)
Fever	0 (0)	7 (7)	---
Convulsions	1 (7)	18 (17)	0.37 (0.05 – 3.03)
Hemiplegia	1 (7)	8 (8)	0.94 (0.11 – 8.07)
Cranial nerve palsy	0 (0)	7 (7)	---

*All results are listed as n (%) except age, which is listed as mean (SD);

For age, t-test used. p=0.74

CHAPTER 5: DISCUSSION

In patients with the acquired immunodeficiency syndrome (AIDS), Toxoplasmic encephalitis (TE) is usually a presumptive diagnosis based on Toxoplasma IgG Antibody, clinical manifestation, and characteristic neuroradiologic abnormalities. Serological testing is the most common laboratory test used for the diagnosis of cerebral toxoplasmosis in AIDS patients. Serology testing (IgG Ab for Toxoplasma) does not achieve definitive diagnosis. However, in the absence of computerized tomography (CT) scanning facilities and the routine post-mortem examinations, which are difficult in terms of financial and cultural beliefs in our setting, serology is a useful parameter in the diagnosis of CNS Toxoplasmosis. Up to 97% of patients with cerebral toxoplasmosis have IgG anti-bodies. Thus, negative results make toxoplasmosis unlikely.

We conducted a cross-sectional study at the University Teaching Hospital in Lusaka, Zambia. The aim of the study was to determine, in HIV/AIDS patient with neurological manifestations, the seroprevalence of Anti-toxoplasma IgG Ab, as this was an important tool in making a diagnosis of CNS toxoplasmosis. The seroprevalence of toxoplasmosis in this study was 11.8%, which was surprisingly lower than what was expected based on the literature review on the worldwide seroprevalence and anecdotal reports of clinical diagnosis of CNS Toxoplasmosis at UTH.

When HIV/AIDS patients present with neurological manifestations, toxoplasmosis is usually high on the list of differential diagnoses. All the patients in this study had a neurological abnormality, such as headache,

neck-stiffness, confusion, convulsion or hemiplegia. Therefore we expected higher seroprevalence.

In comparison with findings from the rest of the world, the toxoplasma seroprevalence in this study was very low. In Malaysia, for example, among 505 HIV/AIDS patients the seroprevalence of Toxoplasmosis was 45% (Veeranoo, *et al.*; 2004), France has the world's highest population-wide seroprevalence at 90-95%. However, only 15 – 30% of French AIDS patients in one study were sero-positive (Raffi *et al.*; 1997). Both of these countries are known for keeping cats as pets. High seroprevalence rates could also be due to the frequent ingestion of undercooked or raw meat products, geographical distribution, and environmental factors, such as climate, and diagnostic methods.

Within Africa, the population-wide seroprevalence (HIV negative population) ranges from 27% in Uganda to 61% of rural population in Somalia (Zumla *et al.*; 1990). Among HIV+ patients, the prevalence has been as high as 34% in Uganda. The study most pertinent to ours, however, was done in 1990, by Zumla, *et al.*- That study compared Toxoplasma serology in Zambia and Ugandan patients infected with HIV. They found only 4% seroprevalence among the Zambian patients. It is worth noting, however, their patient population was asymptomatic HIV patients presenting to clinic for routine care.

Our study found a nearly three-fold higher seroprevalence than the Zumla study, which was expected as we examined patients presenting with neurological abnormalities. The disparity between the two studies could also be due to other factors: with the wider availability of HAART, patients could survive longer than they did 10 years ago, but central nervous

system opportunistic infections would still be prevalent. Also, population-based changes in habits such as food consumption or an increase in keeping cats as domestic pets may have occurred.

In terms of clinical scenario, we found low prevalence of focal neurological deficits such as hemiplegia and cranial nerve palsy. Patients most commonly presented with complaints of headache and neck stiffness. Information on clinical symptoms and signs at presentation was available in 10 of the 14 patients with positive toxoplasma IgG Ab. The common clinical abnormalities among these patients were headache, and neck- stiffness. Only 1 patient with positive toxoplasma antibody and 9 patients overall presented with hemiplegia. The very low prevalence of focal neurological deficit would suggest a lower prevalence of TE which supports the seroprevalence figure. The higher prevalence of headache and neck-stiffness would support the clinical observation that many patients are admitted to UTH with bacterial or cryptococcal meningitis. A multivariable analysis was performed to determine associations between clinical findings and toxoplasma seropositivity. However, there were not enough patients in the study to reach any meaningful conclusions in this regard.

Among seropositive patients for Toxoplasma Ab, those with focal neurological deficit would have a very high probability of TE, and would deserve to institute treatment.

CHAPTER 6: LIMITATIONS

In our resource limiting setting, many of the necessary diagnostic tools are scarce. Serology for toxoplasma on its own is not a definitive diagnostic test. A neurologic imaging study, such CT scanning, is required. CT scans are not available for most patients presenting to UTH, and due to resource limitations, was not included as part of this study.

The list of differential diagnoses of cerebral toxoplasmosis and related confounding variables are vast, as are the investigations one requires differentiating them. The importance of CSF, CRAG, CT Scan/MRI, and other tests cannot be underestimated in order to confirm or to rule out other confounding variables

Historical background information such as Septrin usage for prophylaxis or occupational and dietary habits were not documented, which could have added value to the study,

CHAPTER 6: CONCLUSION AND RECOMMENDATION

6. 1: CONCLUSION

Toxoplasmosis is not as prevalent as expected in HIV positive Zambian patients with neurologic complaints. HIV positive patients with neurologic complaints at UTH tend to present with nonspecific findings such as headache and confusion, or with symptoms suggestive of meningitis such as neckache and neckstiffness.

Despite these findings, toxoplasma encephalitis is still a major concern among HIV seropositive patients with low CD4 counts.

6. 2: RECOMMENDATIONS

In light of the life-threatening nature of toxoplasma encephalitis, it is still recommended to utilise the anti-toxoplasma Ab serology test, to assist the attending physician in making a diagnosis of CNS toxoplasmosis. Other than the history and clinical examination, CT scan is the most reliable means for the detection of cerebral lesion.

HIV-Infected persons who are Toxoplasma sero-positive should be educated about non-pharmacological and medical prophylaxis. They should be advised about preventive measures or practices, including cleaning their hands after soil contact, such as occurs with farming or gardening, and after contact with pets, particularly cats. They should also be advised about their eating habits, to eat only well-cooked meat.

These findings in no way contradict the current MOH recommendations in HIV positive patients with low CD4 cell count but provides a valuable stepping stone for a more detailed population based study.

REFERENCES:

- 1- Ali Nawaz Khan, Toxoplasmosis, CNS; e-medicine, Aug. 10, 2004
- 2- Antinori A, Larussa D, Congolani A, et al. Prevalence, associated factors, and prognostic determinants of AIDS related toxoplasmic encephalitis in the era of advanced highly active antiretroviral therapy. Clin Infect Dis 2004;39:1681 – 1691.
- 3- Arunima Mamidi, Joseph A Desimone, and Roger J pomerantz CNS infections in individuals with HIV-1 infection: Journal of Neurologvirology, 8:158- 167, 2002
- 4- A.Zumla, D. Savva, Ruth B. Wheeler, S. K. Hira, N. P. Luo, P. Kaleebu, S. K. Sempala, Julie D. Johnson and R. Holliman: Toxoplasma serology in Zambia and Ugandan patients infected with human immunodeficiency virus. The royal Society of Tropical Medicine & Hygiene (1991) 85,227-229
- 5- Bruce Brew James, MD, F.R.C.P: HIV Neurology, 2001.
- 6- Caseb J, Marcondes Fonseca LA, Veiga AP, et al. AIDS incidence and mortality in a hospital-based cohort of HIV-1-seropositive patients receiving highly active antiretroviral therapy in Sao Paulo, Brazil. AIDS Patients Care STDs 2003; 17:447 - 452

- 7- Centre for Disease Control & Prevention 1997 USPHS/ IDSA guidelines for the prevention of Opportunistic infections in persons infected with Human Immunodeficiency Virus. MMWR 1997; 46(RR-12):1- 46
- 8- Ciricillo SF, Rosenblum ML. Use of CT & MRI imaging to distinguish intracranial lesions & to define the need for biopsy in AIDS patients. J Neurosurg. 1990 Nov; 73(5):720 – 4
- 9- Ciricillo SF, Rosenblum ML. Imaging of solitary lesions in AIDS. J Neurosurgery, 1991 Jun; 74(6):1029
- 10- Cohen O., The immunopathogenesis of HIV infection, in Paul WE, ed, Fundamental Immunology, Philadelphia; Lippincott Raven, 1999; 1455-1509
- 11- Cohen BA. Neurological manifestations of toxoplasmosis in AIDS. Semin Neurol 1999; 19:201-211
- 12- Dannemann B, McCutchan JA, Israelski D, et al. Treatment of toxoplasmic encephalitis in patients with AIDS. A randomized trial comparing Pyrimethamine plus clindamicin to Pyrimethamine plus sulfadiazine. Ann Intern Med 1992; 116:33-43
- 13- De la Monte SM, Ho DD, Scooley RT, Hirsh MS, Richardson EP Jr. Subacute Encephalomyelitis of AIDS & its relation to HTLV infection. Neurology, 1987 April

- 14- Derouin F, Leport C, Pueyo S, et al. Predictive value of toxoplasma gondii antibody titers on the occurrence of toxoplasmic encephalitis in HIV _infected patients. AIDS 1996.
- 15- Dubey JP, Toxoplasmosis. J Am Vet Med Assoc 189:166, 1988
- 16- Friedman AH, Orellana J, Gaglino DJ, et al. Ocular Toxoplasmosis in AIDS patient. *Trans Am Ophthalmol Soc* 1990; 88: 63- 88
- 17- Grant I, Gold J, Rosumblum M, Niedzwiecki D, Amstrong D. Toxoplasma Gondii serology in HIV – infected patients: The development of CNS toxoplasmosis. AIDS 1990; 4:519 – 21
- 18- Grant HI, Gold JW. Toxoplasma Gondii serology in HIV infected patients, the development of Central Nervous System Toxoplasmosis in AIDS. AIDS 6:519 – 521, 1990
- 19- Holliman RE., Serology study of prevalence of Toxoplasmosis in asymptomatic patients infected with Human Immuno-deficiency Virus. *Epidemiology Infectious* 105:415 – 48, 1990
- 20- Hellerbrand C, Goebel FD, Disko R.; High predictive value of T. gondii antibody levels in HIV-infected patients for diagnosis of cerebral toxoplasmosis. *Euro J Clin Microbial Inf Dis* 1996; 15(11):1869- 1872.)
- 21- Howord M Heller, MD., Toxoplasmosis in HIV-Infected patients: UpToDate. 2006.

- 22- Israelski DM, Remington JS. AIDS –associated toxoplasmosis. In: Sande MA, Volberding PA editors. The medical management of AIDS. Philadelphia: WB Saunders, 1992; 319-45
- 23- John G. Barlett, MD, Joel E. Gallant, MD, M.P.H.: Medical Management of HIV Infection, 2007
- 24- Jose E. Vidal, Adrian V. Hernandez, Augusto C. Penalva De Oliveira, Rafi F. Dauar, Silas Pereira Barbosa Jr., and Roberto Focaccia, AIDS Patient Care and STDs, Vol. 19, No. 10, 2005, Mary Ann Liebert, Inc.
- 25- J. p. dubey, Beattie CP; Toxoplasmosis of animals & man, CPC press, Boca Raton, Fl, 1988
- 26- Levy RM, Rosenblooms, Perrett LV. Neuroradiologic findings in AIDS; a review of 200 cases. AJR Am J Roentogenol 1986 Nov; 147(5):977-83
- 27- Levy RM, Mills CM, Posin JP, Moore SG, Rosenblum ML, Bredson DE. The efficacy & clinical impact of Brain imaging in neuroradiologically symptomatic AIDS patients: A prospective CT/MRI study. J Acquir Immune defic Syndr 1990; 3(5):461 -71
- 28- Levy RM. Brendenson DE. Robenblum ML. Neurological Mass of AIDS: J Neurosurgery 1985

- 29- Luft BJ, Brooks, RG, Conley, FK, et al. Toxoplasmic encephalitis in patients with AIDS: JAMA 1984
- 30- Luft BJ, Conley F, Remington JS, et al. Outbreak of CNS Toxoplasmosis in Western Europe and America. LANCET 1983.
- 31- Luft BJ and Remington, J.S. (1992): Toxoplasmic encephalitis in AIDS. Clin. Infect. Dis., 15, 211- 222.
- 32- Luft BJ, Hafner R, Korzen AH, et al, For the ACTG 077p / ANRS 009 Toxoplasmic Encephalitis in patients with AIDS. N Engl J of Med 1993; 329(14): 995 – 1000
- 33- Mansour SE. Non-cytomegalovirus Posterior segment opportunistic infection in AIDS patients. Ophthalmol. Clin. North Am. 1997- 10: 45 - 60
- 34- McCabe-R, Chirigi V. Issues in Toxoplasmosis. Infect Dis Clin North Am 1993; 7(3):587-604.
- 35- Murray HW et al., Impaired production of Lymphokines & Gamma Interferon in AIDS, N Engl J Med. 1984 April 5:310 (14):883 –
- 36- Murray H (1999) Toxoplasmosis. In AIDS Therapy. Dolin R, Masur H, Saag M. New York: Churchill Livingstone, PP 307-327
- 37- Naveet & J P Wali, CNS & HIV/AIDS: Journal of Indian Academy of Clinical Medicine, Vol. 5, No. 2. 1985

- 38- Navia BA, Petito CK, Gold JW, Cho ES, Jordan BD, Price RW. Cerebral toxoplasmosis complicating the acquired immune deficiency syndrome: Clinical and neuropathological findings in 27 patients. *Ann Neurol* 1986; 19: 224-238
- 39- Oksenhendler E, Cadranel j, Sarafati C, Katlama C, datry A, Marche C, Wolf M, Roux P, Derouin F, Clauvel JP. *Toxoplasma gondii* pneumonia in patients with AIDS. *Am J Med* 1990 May; 88 (5N):18N – 21N
- 40- Paul E. Sex, MD; Calvin J; Cohen, MD, MS; Daniel R Kuritzkes, MD; HIV ESSENTIALS, 2007
- 41- Pauwels A, Meyohas MC, Ehaszewicz M, Legendra C, Mongeot G, Frottier J.; *Toxoplasma colitis* in AIDS. *American journal of gastroenterology* 87:518 – 519, 1992
- 42- Porter SB, Sande MA. Toxoplasmosis of the central nervous system in the acquired immunodeficiency syndrome. *N Engl J Med* 1992; 327:1643-1648
- 43- Pravina V Kittredge, PhD, university of California, San Fransisco, Treatment of Toxoplasmosis in HIV infected patient: Overview of SA Clinicians; June, 2004).
- 44- Post MJ, Kursunogoln SJ, Hensley GT, Chan JC, Moskowitz LB, Hoffman TA. Cranial CT in AIDS; Spectrum of disease and optimal

- contrast enhancement technique. *AJR Am J Roentgenol* 1985 Nov; 145(5):929 – 40
- 45- Raffi F, Aboulker JP, Michelet C. A prospective study of criteria for the diagnosis of toxoplasma encephalitis in 186 AIDS patients. The BIOTOXO study group *AIDS*1997; 11(2):177-184
- 46- Renold C, Sugar A, Chave JP, Perrin L, DeLavelle J, Pizzolato G, Burkhard P, Gabriel V, Hirschel B. Toxoplasma Encephalitis in patients with AIDS. *Medicine (Baltimore)*. 1992 July, 71 (4): 224 – 39
- 47- Reebaund C, May T, Amiel C, Katlama C, Leport C, Ambroise Thomas P, and Canton P. Extracerebral Toxoplasmosis in patients infected with HIV. A French National Survey. *Medicine (Baltimore)*.1994 Nov; 73 (6): 306 – 14
- 48- Mark L. Rosenblum. *Aids & the Nervous System*, 1988. Raven Press, New York
- 49- Schnapp L, Geaghan S, Campagna A, et al. Toxoplasma gondii pneumonitis in patients infected with Human Immunodeficiency Virus. *Arch Intern Med* 1992;152:1073 -6
- 50- Skies DJ. Focal neurological disease in patients with AIDS. *Clin Infect Dis* 2001; 20:410-413
- 51- Subauste CS, Wessedarpm, Smulian AG, frame PT. Role of CD4 ligand signaling in defective type cytokine response in Human Deficiency Virus Inaction. *J Infect Diss*. 2001Jun15; 183(12): 1722-31)

- 52- Suur Biliciler, MD. HIV-1 Associated OIs, CNS Toxoplasmosis: eMedicine 2005.
- 53- Veerant Nissapatorn, Christopher Lee, Kia Fatt Quek, Chee Loon Long, Rohela Mahmud & Khairul Anuar Abdullah> (2004) Toxoplasmosis in HIV/ AIDS patients: A current situation. J Infect Dis., 57, 160- 65, 2004
- 54- Veerant Nissapatorn, Christopher K C Lee, A A Khairul, Singapore Med J 2003 vol 44(4): 194 - 196
- 55- Walot I Miller BL, Chung L et al. Neurological Imaging findings in patients with AIDS. Clinic Infect Dis. 1996; 22(6): 906 - 19
- 56- Winstanley P. Drug treatment of toxoplasmic encephalitis in acquired immunodeficiency syndrome. Post Grad Med Jr 1995; 71:404-408.

PATIENTS INFORMATION SHEET

Title: SEROPREVALENCE OF ANTI-TOXOPLASMA IgG Ab in HIV/AIDS PATIENTS WITH NEUROLOGICAL MANIFESTATION.

Investigator: Dr Abucar Noor Ali Farah

Introduction:

You are being requested to take part in a research study to look at the prevalence of a parasite by the name of **Toxoplasma Gondii**. It has a role in causing damage to the human brain.

This form gives you information about the study. I want you to understand the purpose of the study, the test, the possible risks & benefits, and what will be expected from you if you decide to join.

You may be asked questions about this study at any time.

If you decide to take part the study after it has been fully explained to you, we will ask you to sign a consent form or make your thump-print in front of a witness.

It may be mentioned to you that your participation in this research is entirely

Voluntary. You may decide to withdraw from the study at any time without repercussion.

Purpose of the Study:

Neurological complications of HIV diseases are significantly common, possibly secondary to opportunistic infections.

In view of that, I would like to see how common the parasite toxoplasma gondii cause brain damage among other complications it might cause.

This will help all of us to narrow down the differentials of brain damage secondary to infectious neuro-aids, and hence to speed up its management of the condition before it is too late.

Study procedure:

The study will take place Clinic 5, Medical wards & filter clinic at the University Teaching Hospital.

Blood will be drawn to see the presence of Anti-toxoplasma Ab.

The laboratory test results will be made available to you and you're attending Doctors. If you are found to have the parasite in your blood your Doctor will be informed after obtaining you permission in order to optimize your treatment.

Possible Risks:

There is minimal risk of injury or infection apart from little discomfort or pain while drawing the blood.

Possible Benefits:

You and your attending physician will know if your sera is found Toxoplasma gondii, so that your care can be improved. In addition knowledge gained from this study may in the future help other Zambians who are suffering the same ailment we are dealing now.

Costs to you:

There will be no cost to you for the test that you may have as part of the study.

Confidentiality:

Your research records will be confidential to the extent permitted by law, and will not be released without your written permission. You will not be personally identified in any publication about this study.

However, your records may be reviewed by the Research Ethics Committee, and study staff.

Person to Contact:

If you have any queries about the study you can contact:

Dr. Munthali James

Chairman research Ethics Committee

UNZA Research Ethics Committee

Ph. 25 60 67

Dr Abucar Noor Ali Farah (researcher)

Dept. Of Internal Medicine

University Teaching Hospital

P/Bag RWIX Lusaka, Zambia

Mobile Ph. +260 95 5 781451

***P.S:** You are not giving up any of your rights by signing this information consent.*

CONSENT FORM

You will receive a copy of this signed informed consent.

If you have read the informed consent or it read and explained to you and voluntarily agree to participate this study, please sign your name. If there is any part of this form that is unclear to you, be sure to ask questions about it. Do not sign until you get answers to all your questions.

By signing this consent form you agree to join the study.

.....

.....

Participant's Name Participant's Sign. Thumb print Date

Participant has stated that he/she is:

..... Literate and can sign his/her name

..... Illiterate and cannot sign his/her name

I have observed the participant sign or make his/ her name above and I believe he/ she understood and knowingly gives consent for participation.

.....

.....

Witness's name

Witness's signature

Date:

I have explained the purpose of this study to the participant. He/ she had the form ready to him/ her was given the chance to ask questions, accepted the answers, and signed to enroll in the study.

.....

.....

Staff's name

Staff's signature

Date:



THE UNIVERSITY OF ZAMBIA

BIOMEDICAL RESEARCH ETHICS COMMITTEE

Telephone: 260-1-256067
Telegrams: UNZA, LUSAKA
Telex: UNZALU ZA 44370
Fax: + 260-1-250753
E-mail: unzarec@zamtel.zm

Ridgeway Campus
P.O. Box 50110
Lusaka, Zambia

Assurance No. FWA00000338
IRB00001131 of IORG0000774

5 January, 2009
Ref.: 013-12-08

Dr Abucar Noor Ali Farah, MBBS
Department of Internal Medicine
University Teaching Hospital
LUSAKA

Dear Dr Farah,

RE: RESUBMITTED RESEARCH PROPOSAL: "SERO PREVALENCE OF ANTI-TOXOPLASMA IgGAb IN HIV PATIENTS WITH NEUROLOGICAL MANIFESTATIONS"

The above-mentioned research proposal was presented to the Biomedical Research Ethics Committee Secretariat on 27 November, 2008 where changes were recommended. We would like to acknowledge receipt of the corrected version with clarifications. The proposal has now been approved.

CONDITIONS:

- This approval is based strictly on your submitted proposal. Should there be need for you to modify or change the study design or methodology, you will need to seek clearance from the Research Ethics Committee.
- If you have need for further clarification please consult this office. Please note that it is mandatory that you submit a detailed progress report of your study to this Committee every six months and a final copy of your report at the end of the study.
- Any serious adverse events must be reported at once to this Committee.
- Please note that when your approval expires you may need to request for renewal. The request should be accompanied by a Progress Report (Progress Report Forms can be obtained from the Secretariat).

Yours sincerely,

Dr James C. Munthali
CHAIRPERSON

Date of approval: 5 January, 2009

Date of expiry: 4 January, 2010