

ESTABLISHMENT AND EVALUATION OF SEROLOGICAL
DIAGNOSTIC TESTS FOR HUMAN CYSTICERCOSIS

By

Chalumba Kachusi Simukoko

Bachelor of Veterinary Medicine (B.V.M.), University of Zambia

*A thesis submitted to the University of Zambia in partial fulfillment of
the requirements of the degree of Master of Science in Parasite
Immunology.*

**THE UNIVERSITY OF ZAMBIA
SCHOOL OF VETERINARY MEDICINE
BIOMEDICAL SCIENCES DEPARTMENT
LUSAKA
©2013**

DECLARATION

I **Chalumba Kachusi Simukoko** do hereby declare that this dissertation represents my own work and has not been previously submitted for the award of a degree or any other qualification at this or another University.

Signature: -----

Date: -----

CERTIFICATE OF APPROVAL

This thesis by **Chalumba Kachusi Simukoko** has been approved as fulfilling the requirements for the award of the degree of Master of Science in Parasite Immunology by the University of Zambia.

Supervisor ----- Signature----- Date-----

Examiner ----- Signature----- Date -----

Examiner ----- Signature----- Date-----

Abstract

Taenia solium (*T. solium*) infections are of public health concern in most developing countries where diagnosis of the diseases is still a major challenge. This is due to the high cost and technique nature of most of the reliable diagnostic tools that are commercially available. In this study, serological tests developed from crude cyst antigens (Ags) of *T. solium*, were established at the University of Zambia, and evaluated for their sensitivity and specificity in detecting circulating cysticerci serum antibodies (Abs) in human. The crude antigen was produced from cysts of *T. solium* collected from pigs from rural Zambia. The antibodies – Enzyme-linked immunosorbent assay (Ab-ELISA) and Electroimmunotransfer blot (EITB) tests were evaluated using a commercial (QualiCode™ Cysticercosis Kit) Immunoblot, in order to estimate their sensitivity and specificity.

The Ab-ELISA used a cut off-point of 15 antigen concentration of dilute serum. The Ab-ELISA showed a sensitivity and specificity of 16.67% and 91.94%, respectively. The crude antigen EITB used the 8-10 kDa antigenic bands to detect *T. solium* sera Abs in human. The commercial blot used any of the six bands 50, 42, 39, 24, 21, 18 and 14 kDa to detect *T. solium* sera Abs in human. Compared to the commercial blot, whose sensitivity and specificity was 98.00% and 100%, respectively, the crude antigen EITB had a sensitivity of 19.44% and specificity of 85.48%. The crude antigen EITB and Ab-ELISA tests showed significant difference ($p < 0.05$), as the former detected more positives (25) compared to the latter (14) out of 199 samples tested.

To our knowledge, this is the first study that attempted to establish an EITB from crude antigens. Most EITB that have been developed so far are based on purified antigens. The study demonstrated that the crude antigen EITB and Ab-ELISA tests are significantly less sensitive than the commercial Immunoblot test. In spite of this, both the Ab-ELISA and EITB can be useful as screening tests in endemic areas before more sensitive and expensive tests are employed. Besides, Ab-ELISA tests have an advantage of giving the level of antibody titres in the patient's blood, thus can be used to monitor the progress of the disease treatment. Future research should consider the use and evaluation of more immunogenic components of the cyst fluid or the use of purified or synthetic Ags, in an attempt to increase the test sensitivity.

DEDICATION

*This dissertation is dedicated to my **parents Mr. and Mrs. Simukoko**, For your love, support and understanding **My brothers and sisters**, For believing in me and To **My friends** For making everything worthwhile*

ACKNOWLEDGEMENTS

This research would not have been possible without the financial support of the Germany Research Foundation (DFG) under the Sub-Saharan Neurocysticercosis Research Project (NCC Project) and the University of Zambia

Great appreciation goes to my supervisors namely Dr. C.S Sikasunge, Prof. C.K Siulapwa and Dr. V. Schmidt, for their contribution in ensuring that this work was completed.

I am also very grateful to the technical staff in the Departments of Biomedical Sciences and Paraclinical Studies in School of Veterinary Medicine at the University of Zambia for their assistance.

My gratitude also goes to the District Veterinary officers in Gwembe, Mongu and Katete districts for allowing us to carry out our research in their Districts. I am also grateful to the Veterinary assistants who acted as guides in the field during sample collection. I also wish to express my gratitude to the local community leaders and the farmers for their friendly reception and help rendered during the work.

I am also grateful to Dr Kabemba Mwape and Mr Amos Chota for allowing us to use some of their samples in our research.

I also would like to express my gratitude to Dr Andrea Winkler, Dr Gisela Britzel and the staff at the Department of Infectious Diseases and Tropical Medicine (DMIT) at Ludwig-Maximilians University in Munich Germany, for providing training in the laboratory techniques necessary for the research.

I shall forever be grateful to my family for their patience, care, love and support during the period of study.

I am eternally grateful to God Almighty for giving me wisdom and guidance that enabled me to complete my research work.

TABLE OF CONTENTS

| | |
|---|-----------|
| DECLARATION | 2 |
| Abstract | 4 |
| ACKNOWLEDGEMENTS | 6 |
| TABLE OF CONTENTS | 7 |
| LIST OF SYMBOLS AND ABBREVIATIONS | 12 |
| CHAPTER ONE | 13 |
| 1.0 INTRODUCTION | 13 |
| CHAPTER TWO | 16 |
| 2.0 LITERATURE REVIEW | 16 |
| 2.1 History | 16 |
| 2.2 The parasite/Aetiology | 17 |
| 2.2.1.1 Adult tapeworm | 17 |
| 2.2.1.2 Cysticercus..... | 18 |
| 2.2.1.3 Oncospheres..... | 18 |
| 2.3 The life cycle of <i>T. solium</i> | 19 |
| 2.4 Host range | 23 |
| 2.5 The importance of <i>T. solium</i> taeniasis and cysticercosis | 24 |
| 2.5.1 Impact of <i>T. solium</i> infection on pig industry | 24 |
| 2.5.2 Impact of <i>T. solium</i> infection on public health and social life | 25 |
| 2.6 Disease due to <i>T. solium</i> -taeniasis and cysticercosis | 26 |
| 2.6.1 Disease in pigs-porcine cysticercosis..... | 27 |
| 2.6.2 Disease in human-taeniosis and cysticercosis..... | 27 |
| 2.7 Epidemiology and risk factors of <i>T. solium</i> | 28 |
| 2.7.1 Distribution | 28 |
| 2.7.2 Risk factors | 30 |
| 2.8 Diagnosis of <i>T. solium</i> infections | 31 |
| 2.8.1 Diagnosis of porcine cysticercosis..... | 31 |
| 2.8.3 Diagnosis of human cysticercosis | 37 |
| 2.8.4 Diagnosis of human neurocysticercosis | 41 |
| 2.9 Treatment | 46 |
| 2.9.1 Porcine cysticercosis..... | 46 |
| 2.9.2 Taeniosis | 47 |

| | | |
|---------------------------------------|--|-----------|
| 2.9.3 | Extraneural cysticercosis in human..... | 48 |
| 2.9.4 | Neurocysticercosis | 48 |
| 2.10 | Prevention and control of taeniosis and cysticercosis | 55 |
| CHAPTER THREE | | 59 |
| 3.0 MATERIALS AND METHODS..... | | 59 |
| 3.1 | Study area | 59 |
| 3.2 | Study design | 62 |
| 3.3 | Sample collection | 63 |
| 3.3.1 | Pig samples | 63 |
| 3.3.2 | Human sera and control sera..... | 63 |
| 3.4 | Research Methods | 63 |
| 3.4.1 | Tongue examination..... | 63 |
| 3.4.2 | Cyst collection | 64 |
| 3.5 | Immunological methods | 64 |
| 3.5.1 | Preparation of crude <i>T. solium</i> cyst antigen..... | 65 |
| 3.5.2 | Determination of antigen protein concentration | 65 |
| 3.5.3 | Indirect/Antibody Enzyme Linked Immunosorbent Assay titration..... | 66 |
| 3.5.4 | Western blot/Immunoblot | 68 |
| 3.5.5 | Commercial Immunoblot (QualiCode™ Cysticercosis Kit)..... | 70 |
| 3.6 | Data analysis | 70 |
| CHAPTER FOUR | | 71 |
| 4.0 RESULTS..... | | 71 |
| 4.1 | Tongue examination and cysts collected | 71 |
| 4.2 | Antigen concentrations | 72 |
| 4.3 | Indirect/Antibody Enzyme Linked Immunosorbent Assay titration | 73 |
| 4.4 | Diagnostic bands for western blot | 73 |
| 4.5 | Crude Western blot | 75 |
| 4.6 | Comparisons of diagnostic tests | 75 |
| 4.6.1 | Commercial immunoblot and Ab-ELISA | 76 |
| 4.6.2 | Commercial immunoblot and crude antigen immunoblot | 76 |
| 4.6.3 | Crude antigen immunoblot and Ab-ELISA | 77 |
| 4.6.4 | Comparison of the three diagnostic tests (crude antigen immunoblot, Ab-ELISA and commercial immunoblot)..... | 77 |
| CHAPTER FIVE | | 79 |
| 5.0 DISCUSSION..... | | 79 |

| | |
|---|-----------|
| CHAPTER SIX..... | 84 |
| 6.0 CONCLUSION AND RECOMMENDATIONS | 84 |
| REFERENCES | 86 |

LIST OF FIGURES

- Figure 2.1a** Head of Adult tape *Taenia solium*
- Figure 2.1b** Scolex of *Taenia solium*
- Figure 2.2a** Oncosphere of *Taenia solium*.
- Figure 2.2b** Hexacanth embryo in Oncosphere of *Taenia solium*.
- Figure 2.3** Life cycle of *Taenia solium* (pork tapeworm).
- Figure 2.4** Countries and areas at risk of cysticercosis.
- Figure 3.1** Map of Zambia showing the districts where cyst collection was done.
- Figure 3.2** Free roaming pigs in a village in Katete district.
- Figure 3.3** A pit latrine in one of the households of Undi village in Katete district.
- Figure 3.4** A shelter made of sticks and reeds, where pigs are kept during the security in one of the villages in Mongu.
- Figure 4.1** A pig positive for cysticercosis on tongue examination.
- Figure 4.2** *Taenia solium* cysts covering the entire muscle tissue from an infected pig.
- Figure 4.3** Colour bands and molecular mass of Precision Plus Protein Standards, Amidoblack stained antigen bands and a positive and negative stripe for *T. solium*.
- Figure 4.4** Amidoblack stained Immobilon paper, reaction with *T. solium* positive sera and *E. granulosus* positive sera.
- Figure 4.5** Reaction of Immunoblot stripes with Negative and positive control and test sera on crude antigen Immunoblot.

LIST OF TABLES

| | |
|------------------|---|
| Table 3.1 | Different dilutions of the standard and their concentrations. |
| Table 3.2 | Dilutions of the sample (antigen solution). |
| Table 4.1 | Number of pigs examined and sampled in each district. |
| Table 4.2 | Comparison of crude antigen immunoblot with commercial immunoblot. |
| Table 4.3 | Comparison of commercial immunoblot with Ab-ELISA. |
| Table 4.4 | Comparison of crude antigen immunoblot with Ab-ELISA. |
| Table 4.5 | Correlation of the overall cysticercosis results obtained by three tests. |

LIST OF SYMBOLS AND ABBREVIATIONS

| | |
|--------------|--|
| °C | Degree Celsius |
| µg | Microgram |
| G | Gram |
| nM | Nanometre |
| µl | Microliter |
| ml | Millilitre |
| M | Molar |
| OPD | o-phenylenediamine |
| OD | Optical density |
| AC | Antigen concentration |
| PBS-T | Phosphate buffer saline-Tween |
| PBS | Phosphate buffer saline |
| BSA | Bovine serum albumin |
| ELISA | Enzyme Linked Immunosorbent Assay |
| EITB | Electroimmunotransfer blot |
| Ag | Antigen |
| Ab | Antibody |
| VF | Versicular fluid |
| kDa | Kilo Dalton |
| PCR | Polymerise chain reaction |
| SDS- PAGE | Dodecyl Sulphate sodium- polyacrylamide gel electrophoresis |

CHAPTER ONE

1.0 INTRODUCTION

Livestock production is an important part of any country's economy. It is a source of income for a large proportion of the population. Livestock products are also an important part of the diet for most people. Animal products and by-products provide much needed nutrients in the human diet. Unfortunately, animal products have also been a source of disease to human. This has led to the development of the study of zoonotic diseases. Zoonotic diseases are diseases that are transmitted between vertebrate animals and humans (Slifko *et al.*, 2000). There are over 200 zoonotic diseases. An important area of zoonotic diseases that has recently attracted much attention is that of re-emerging and emerging zoonotic diseases. Many new, emerging and re-emerging diseases of humans are caused by pathogens which originate from animals or products of animal origin (Meslin *et al.*, 2000). This has made the study of zoonotic diseases in animals to be of great importance in order to control disease in man. A wide variety of animal species, both domestic and wild, act as reservoirs for these pathogens, which may be viruses, bacteria or parasites (Meslin *et al.*, 2000). Cestode infections in animals are important because several species are zoonotic, causing cysticercosis and hydatidosis in man, and because of the economic losses incurred due to infections in livestock (Lightowlers, 1990).

Zoonotic diseases due to the cestode *Taenia solium* are some of the most serious diseases of humans. *Taenia solium* (the pork tapeworm) is a cyclophyllid cestode in the family *Taeniidae*. The adult of *T. solium* is exclusively a parasite of man, where the adult strobila develops in the intestines (Smyth, 1994). In spite of this, it has been experimentally established in the gibbon and chacma baboon that the adult strobila can also develop (Soulsby, 1982). The larval stage occurs naturally in pigs and wildboars, but man can also be infected with serious and often fatal results (Smyth, 1994). The parasite is transmitted from pigs to humans through the ingestions of viable cysts in pork or through ingestion of eggs of the cestode in human excreta (Soulsby, 1982; Smyth, 1994; Garcia *et al.*, 2003; Mayta *et al.*, 2008). Humans are the only definitive hosts while pigs act as intermediate hosts

(Garcia *et al.*, 2003). Human cysticercosis occurs when a human host ingests infective eggs by faecal contamination and replaces the pig as intermediate host (Garcia *et al.*, 2003). *Taenia solium* commonly infects the central nervous system, causing neurocysticercosis (NCC), a pleiomorphic clinical disorder (Garcia *et al.*, 2003). The other forms of the disease (taeniasis and extraneurocysticercosis) are less severe, although extraneurocysticercosis has been reported in a few cases to cause serious disease such as eye problems (Garcia *et al.*, 2003). Taeniasis occurs when humans ingest viable cysts in pork, and the adult stage of the tape-worm develops in the intestines (Smyth, 1994; Mayta *et al.*, 2008). Extraneurocysticercosis occurs when cysts are established outside the central nervous system (Garcia *et al.*, 2003).

Neurocysticercosis remains a major public health problem in developing and some developed countries (Carpio *et al.*, 1998). The World Health Organisation estimates that eight people per 1000 worldwide have NCC (WHO, 2001). Accurate diagnosis of NCC is therefore vital in order to control the condition in humans. The diagnosis of human cysticercosis can be made by radiologic imaging, tissue biopsy, or serology. Currently, the best procedures for diagnosing NCC are neuroimaging studies (Carpio *et al.*, 1998). However, these methods are expensive and not available to most people in third world countries like Zambia. Furthermore, computed tomography and magnetic resonance imaging which are efficient methods for the visualization of cysticerci and of an inflammatory response, are very expensive and inaccessible to most of the affected population (Pardini *et al.*, 2002). Due to the high cost of these diagnostic methods, they are not suitable for epidemiological studies or screening test for *T. solium* infections. Therefore, serological tests for the detection of specific circulating antigens (Ag) and antibodies (Ab) are more and more frequently used, particularly in epidemiological studies (Prado-Jean *et al.*, 2007). Serological test such as Enzyme-Linked Immunosorbent Assay (ELISA) and Immunoblotting techniques (Western Blot) are more sensitive than the routine tests of tongue examination, meat inspection and faecal examination (Flisser *et al.*, 1990; Phiri *et al.*, 2003; Gomes *et al.*, 2007; Sikasunge *et al.*, 2007). Immunoblotting is more sensitive than ELISA, having sensitivity of 98 percent and specificity of up to 100 percent in patients with more than one lesion as opposed to ELISA which has sensitivity of

84 percent and specificity up to 94 percent (Garcia *et al.*, 2003; Dorny *et al.*, 2004; Sikasunge, 2008). The serological methods are also more affordable, and can therefore be used for epidemiological studies and screening for infections.

Prevalence of *T. solium* infection in pigs in Zambia has been shown to be high (Sikasunge *et al.*, 2007; Phiri *et al.*, 2006; Dorny *et al.*, 2004). This high prevalence of porcine cysticercosis indicates the presence of human carriers of the adult tapeworm and also connotes the associated risk of human cysticercosis and neurocysticercosis. This poses a serious problem to human health and the economy. One of the main obstacles to control and elimination of *T. solium* infections is the lack of adequate epidemiological data on cysticercosis/taeniasis. It is therefore necessary to come up with diagnostic tests that have reliable results and are affordable in developing countries like Zambia where radiological imaging is not widely available.

The main objectives in this study were therefore:

1. To examine pigs in Eastern, Southern and Western provinces of Zambia for *T. solium* infection and use the detected parasites (*T. solium* cysts) as a source of antigen (Ag) for diagnosis of human cysticercosis.
2. To establish antibody (Ab)-ELISA and Western Blot (WB) tests for diagnosis of human cysticercosis using crude antigens (Ags) from *T. solium* cysts obtained from infected pigs.
3. To evaluate the sensitivity and specificity of the established antibody ELISA and Western blot using the commercial Western Blot as a standard.

CHAPTER TWO

2.0 LITERATURE REVIEW

2.1 History

Taenia solium (the pork tapeworm) is a cyclophyllid cestode in the family *Taeniidae*. The adult of *T. solium* is exclusively a parasite of man, where the adult strobila develops in the intestines (Smyth, 1994). It infects pig and humans in large parts of Latin America, Sub-Saharan Africa, India, China and Southeast Asia, and isolated foci mainly of imported cases also occur in Western Europe, the Caribbean, Oceania and USA (Craig and Ita, 2007).

The scientific study of the taeniid tapeworms of humans can be traced to the late 17th century and the observations of Edward Tyson on the tapeworms of humans, dogs, and other animals. Tyson was the first person to recognize the 'head' (scolex) of a tapeworm, and his subsequent descriptions of the anatomy and physiology of the adult worms laid the foundations for our knowledge of the biology of the taeniid tapeworms of humans (Cox, 2002). However, the difference between *Taenia solium* and *Taenia saginata* (Beef tapeworm) was not apparent at the time. These worms continued to be confused long after the work of Tyson, and although Goeze in 1782 had suspected that there were two species it was not until the middle of the 19th century that Küchenmeister reported the differences between *T. solium* and *T. saginata* based on the morphology of the scolex (Cox, 2002). In 1784, the first indications that intermediate hosts were involved in the life cycles of taeniid tapeworms emerged from the detailed studies of the pork tapeworm by a German pastor, Johann August Ephraim Goeze, who observed that the scolices of the tapeworm in humans resembled cysts in the muscle of pigs. Some 70 years later, Küchenmeister, in much-criticized experiments, fed pig meat containing the cysticerci of *T. solium* to criminals condemned to death and recovered adult tapeworms from the intestine after they had been executed (Cox, 2002).

2.2 The parasite/Aetiology

Taenia solium belongs to the kingdom Animalia, phylum Platyhelminthes, class Cestoidea, order Cyclophillidea, family Taeniidae, genus *Taenia* and species *solium*. *Taenia solium* exists in three forms, the adult tape worm, the intermediate form (cysticerci) and the egg form.

2.2.1 Morphology

2.2.1.1 Adult tapeworm

The adult tapeworm is a hermaphrodite, endoparasitic worm with an elongate flat body and without a body cavity or alimentary canal. It is 3-5 m or up to 8 m long and can survive for up to 25 years (Soulsby, 1982; Urquhart *et al.*, 1987). The body consists of a head or scolex which is followed by a short unsegmented portion called the neck. Attached to the neck is the strobila which consists of a number of segments or proglottids (Soulsby, 1982; Urquhart *et al.*, 1987). The scolex bears a rostellum and four suckers. The rostellum, armed with 22 and 36 hooks arranged in two concentric rows of hooks and a thin neck measuring approximately 5 to 10 mm (fig. 2.1), constitutes the portion with most of the biokinetic activity (Rodriguez-Hidalgo, 2007). The gravid proglottids are 10-12 mm long by 5-6 mm wide and the uterus has 7 to 16 lateral branches. The gravid proglottids, each containing about 40,000 eggs, do not leave the host spontaneously and are voided in the faeces, frequently in chains. The eggs are 26-34 μm in diameter (Soulsby, 1982).

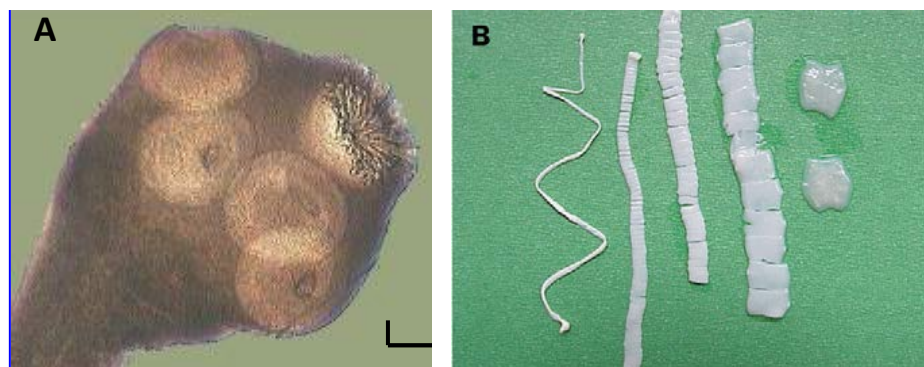


Figure 2.1 Showing scolex of *T. solium* (A) and proglottids (B) of the tape worm. (Source: Garcia *et al.*, 2003).

2.2.1.2 Cysticercus

A cysticercus is an ovoid vesicle of approximately 5-15mm diameter, with a transparent membrane. It contains an invaginated scolex and a neck that has a spiral or S-like shape (spiral canal), and is filled with a colourless liquid (Rodriguez-Hidalgo, 2007). Cysticerci can grow up to 2 cm, though occasionally they may even grow larger than this (Garcia *et al.*, 2003). Murrell *et al.* (2005), described the cysticerci (metacestodes) as having two chambers; the inner one containing the scolex and the spiral canal is surrounded by the outer compartment that contains the vesicular fluid, usually less than 0.5 ml. Cysticercus may lodge anywhere in the body but show predilection for muscles of the jaws, heart, neck, tongue, elbows, shoulders and the thighs (Boa *et al.*, 2002; Phiri *et al.*, 2006; Smyth, 1994). They (cysticerci) are frequent in striated muscles, but may also lodge in the heart, abdominal wall, liver, lungs, brain or eyes may be involved (Soulsby, 1982). Cysticerci in man develop primarily in the subcutaneous tissue, but may affect the brain and ocular tissue as well (Soulsby, 1982).

2.2.1.3 Oncospheres

The uterus contains spherical eggs or oncospheres (Fig. 2.3A), measuring between 29 and 77µm in diameter (Rodriguez-Hidalgo, 2007; Murrell *et al.*, 2005). Under a microscopy *T. solium* eggs are brown in colour, embryonated with radial striations in the egg shell giving it a radiated appearance (Sikasunge, 2009). They have a chorionic membrane, a thick and grooved embryophore, which is formed by embryophoric blocks (constituted of a keratin like protein), an embryophoral membrane, two oncospherical membranes surrounding the oncosphere (also named hexacanth embryo) bearing three pairs of hooks (Fig. 2.3B) (Rodriguez-Hidalgo, 2007; Urquhart *et al.*, 1987)

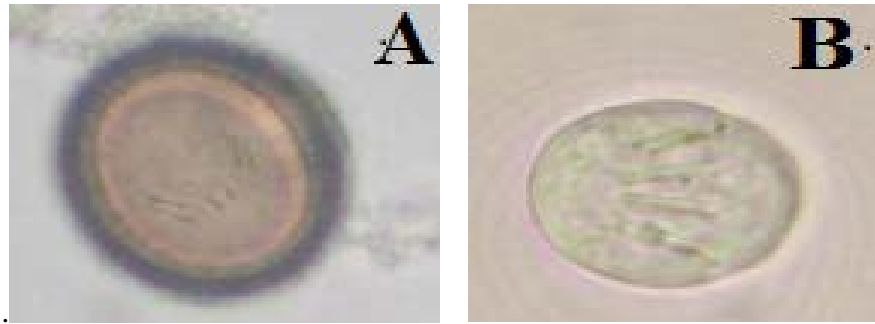


Figure 2.2 Showing (A) Oncosphere and (B) Hexacanth embryo. (Source: Rodriguez-Hidalgo, 2007)

2.3 The life cycle of *T. solium*

Taenia solium has a complex two-host life cycle. Human beings are the only definitive host and harbour the adult tapeworm (a condition referred to as natural taeniasis), whereas both people and pigs can act as intermediate hosts and harbour the larvae or cysticerci (Garcia *et al.*, 2003). Humans acquire taeniasis (intestinal infection) by eating undercooked or raw pork infected with cysticerci. In the intestines, the protoscolex evaginates and attaches to the mucosa with its double row of hooks and its four suckers in the upper third section of the small intestine, which is the duodenum-jejunum (Murrell *et al.*, 2005). The adult tapeworm develops in the small intestines of humans by forming proglottids which arise from the caudal end of the scolex (neck) (Soulsby, 1982; Flisser, 1994). The body formation which is called strobilation is rapid with development of a mature tapeworm which is 2-7 meters long after 2-3 months post-infection (Flisser, 1994). The earlier proglottids gradually enlarge and mature as they are separated from the scolex by newly produced proglottids with functional testes and ovaries. The tapeworm produces millions of eggs which are fertilized within the proglottids and are passed to the environment (Sikasunge, 2009). The adult worm starts releasing gravid proglottids between 8 to 12 weeks after infection (Murrell *et al.*, 2005). Each terminal gravid proglottid contains about 50,000 eggs which can either be intermittently extruded from the proglottids into the intestine, or the entire gravid proglottids may be passed in the faeces (White, 1997).

Most patients are asymptomatic. However, they may note the passage of proglottids, which are opaque, off-white in colour, and 1-2 cm long, 1 cm wide,

and 2-3 mm thick (White, 1997). The worm releases in the host's faeces a few gravid proglottids daily or two to three times per week (Murrell *et al.*, 2005). Since excretion of the proglottids is intermittent, stool studies from patients with active tapeworm infections are commonly negative for parasite ova (White, 1997). The lifespan of the adult *T solium* is also unknown. Parasitology textbooks and reviews cite 20–25 years, on the basis of anecdotal cases. Age-specific data from later studies suggest a much shorter lifespan, probably less than 5 years (Garcia *et al.*, 2003). Murrell *et al.* (2005) also said that indications from studies are that the tapeworm remains in the intestines only for short periods.

The development of successful experimental models of taeniosis has allowed more in-depth investigations of the host-parasite relationship. Microscopic studies have shown that the scolex anchors in the upper third part of the duodenum; it engulfs intestinal villi into its suckers and burrows its rostellum into Lieberkuhn crypts of the subcutaneous mucosa. Histological analysis of the anchor site has shown an intense inflammatory reaction surrounding the scolex (Murrell *et al.*, 2005). Specific antibodies and parasite antigens have also been detected in serum and faeces of infected hamsters (Murrell *et al.*, 2005).

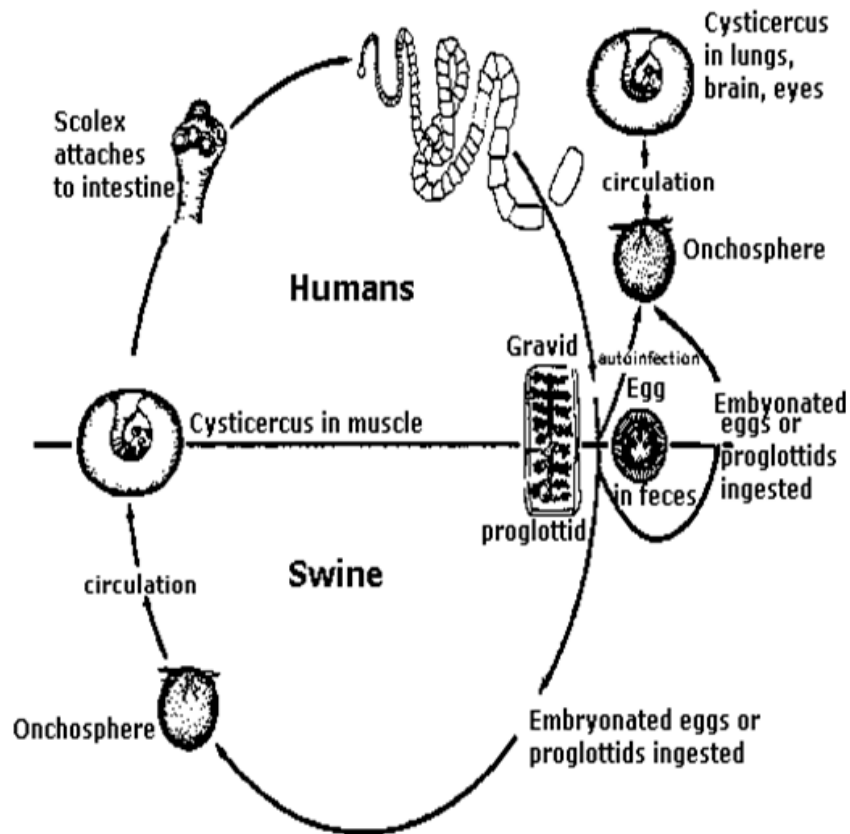


Figure 2.1: The life cycle of *Taenia solium*, showing the infective stages for both man and pig. (Source: www.nlc.net.au/.../taeniasislifecycle.htm)

The domestic pig is the main intermediate host for the tapeworm, that is, it harbors the cysticercus. The larval stage occurs naturally in pigs and wildboars, but man can also be infected with serious and often fatal results (Smyth, 1994). Infection by the larval stage of the parasite is called cysticercosis (Garcia *et al.*, 2003). However, *T. solium* cysticercosis in dogs has recently been reported in countries such as Indonesia and the People's Republic of China, where, because these animals are eaten, they can be a source of human taeniosis (Murrell *et al.*, 2005).

The usual intermediate host, the pig, is infected by ingestion of parasite eggs or proglottids in human faeces. Thus, porcine infection is limited to areas where animal husbandry practices are such that pigs come into contact with human faeces (White, 1997). When swine ingest eggs, bile and enzymes trigger the disaggregation of the embryophoric blocks and digest the oncospherical membrane

(Murrell *et al.*, 2005). The eggs are induced to hatch and are activated by the action of gastric and intestinal fluids. The hatched larvae, also called the oncospheres, escape from the eggs, attach to the intestines via motile hooks, and penetrate the intestinal mucosa and the vessels in the submucosa (White, 1997; Murrell *et al.*, 2005). Penetration appears to be facilitated by excretory proteases produced by the oncospheres (White, 1997). After invasion, the oncospheres migrate via the bloodstream or lymphatics throughout the body of the intermediate host where they develop into cysticerci (White, 1997; Murrell *et al.*, 2005). Cysticerci develop over a period of 3 weeks to 2 months, as the oncospheres enlarge and mature (White, 1997). It is not known whether the oncospheres actively migrate to specific tissue or merely passively lodge in the tissues with high blood flow (White, 1997). Cysticerci establish primarily in skeletal and cardiac muscle, as well as in the brain of pigs, a process that takes approximately 8 weeks (Murrell *et al.*, 2005). The cysts appear in the muscles as translucent, thin-walled cysts that are 1 cm in diameter and have an eccentric white nodule containing the invaginated scolex (White, 1997). Soulsby (1982) stated that the cysticerci are infective after about 9 to 10 weeks and that though the longevity of cysticerci is not known, however, the young age at which pigs are slaughtered means that the majority of cysts in pork would be viable. Murrell *et al.* (2005) stated that cysticerci remain viable for at least one year, when pigs are usually sent to slaughter. In older pigs the inflammatory reaction surrounding cysticerci becomes evident with time (Murrell *et al.*, 2005). In long standing porcine infections calcified cysts may be found in some pig, these appear as white vesicle and have caseous material when opened (Sikasunge, 2009). The life cycle of the parasite is completed when humans consume undercooked pork containing the cysts (White, 1997).

Humans may also harbor cysticerci (Murrell *et al.*, 2005). White (1997) reports that humans get infected through ingestion of *T. solium* eggs. Human beings acquire cysticercosis through faecal-oral contamination with *T. solium* eggs from tapeworm carriers. Thus, vegetarians and other people who do not eat pork can acquire cysticercosis (Garcia *et al.*, 2003). Water, wind, flies, and other indirect means of infection play little part in transmission. Internal autoinfection by

regurgitation of proglottids into the stomach in taeniasis has been proposed but not proven (Garcia *et al.*, 2003). A recent study showed that the prevalence of taeniosis among patients with NCC is higher than previously reported. The perception that tapeworms are silent guests, causing no harm to humans, is therefore erroneous, and tapeworm carriers should be regarded as potential sources of infection to themselves and to those living in their close environment (Murrell *et al.*, 2005).

After ingestion of the eggs, the oncospheres are released, penetrate the intestinal mucosa, and migrate throughout the body to produce human cysticercosis (White, 1997). At small terminal vessels, they establish and encyst as cysticerci, reaching their definitive size of about 1 cm in 2–3 months (Garcia *et al.*, 2003). Larval cysts are occasionally found in nearly every tissue, but the larvae do not usually develop into mature cysts in most tissues. Thus, most cysts are found in the CNS, skeletal muscle, subcutaneous tissue, and the eyes (White, 1997). Cyst may also be present in the liver and lungs (Gracey and Collins, 1992). The greatest number of cysts establish in the subcutaneous tissue, then in the brain, and in the muscle particularly in the thigh and calf (Gracey and Collins, 1992). Calcified cysticerci are frequently seen only in human (Murrell *et al.*, 2005).

2.4 Host range

Taenia solium adult and larval forms are less host-specific. The adult of *T. solium* was said to be exclusively a parasite of man, where the adult strobila develops in the intestines by Smyth (1994). In spite of this, experimentally it was reported established in the gibbon and Chacma baboon (Soulsby, 1982; Pawlowski 2002). Man is the natural definitive host for the adult tapeworm (Pawlowski, 2002). The tapeworm usually occurs singly in intestines of humans but in edemic areas, several tapeworms, up to 25, may be present in an individual (Gracey and Collins, 1992). The larval stage of the tapeworm is found most commonly in pigs, though it can also occur in the wild boar, rabbits, hare, monkeys, sheep, man and dogs (Scuitto *et al.*, 2000; Ito *et al.*, 2002). Ito *et al.* (2002) stated that although pigs are the most important intermediate hosts of economic importance, dogs are also highly susceptible and become intermediate hosts.

2.5 The importance of *T. solium* taeniasis and cysticercosis

Taenia solium infections have become a serious problem to man and pigs worldwide. *Taenia solium* is a serious public health and agricultural problem in Eastern and Southern Africa (Carabin *et al.*, 2006). They cause loss of income in the pig industry. They have also caused an increase in the cost of medical care associated with diagnosing and treating human infections. Neurocysticercosis also has a social effect on the community as it affects the livelihood of infected individuals and those near them.

2.5.1 Impact of *T. solium* infection on pig industry.

Porcine cysticercosis is one of the major pig diseases in most developing countries. *Taenia solium* cysticercosis is now regarded as an important disease due to its public health and economic effects in most developing countries (Dias *et al.*, 2007; Flisser *et al.*, 1990). This is due to the loss of income due to the condemnation of infected pig carcasses. The presence of cysts in the live animal or in the meat greatly reduces its market value causing economic losses to the producer (Sikasunge, 2005). Also regulations in most African countries require infected pigs to be destroyed (Zoli *et al.*, 2003). These all result in huge losses to the pig traders. Based on the available information, a very conservative economic estimate indicates that the annual losses due to porcine cysticercosis in 10 West and Central African countries amount to about 25 million Euro (Zoila *et al.*, 2003). In Eastern Cape Province of South Africa, the agricultural sector losses were estimated to an average of US\$5.0 million (Carabin *et al.*, 2006). In Mexico, porcine cysticercosis is responsible for a loss of more than one-half of the national investment in swine production. For all of Latin America, porcine cysticercosis accounts for an economic loss of US\$164 million (Murrell, 1991). Inspection of pork and all pork products meant for human consumption is necessary to prevent spread of the disease to humans. Routine inspection is done by lingual examination for cysts and at meat inspection for cysts in the muscles (Lapage, 1965; Wilson, 1991; Phiri *et al.*, 2003). However, these 2 detection methods in pigs have shown some shortcomings in the detection of porcine cysticercosis (Sato *et al.*, 2003; Phiri *et al.*, 2006). This continues to pose a problem to human health as some infected pork still finds its way into the human

food chain. Also due to lack of well organised meat inspection and very common illegal slaughtering, almost all infected carcasses are marketed or consumed continuing to cause disease in humans (Zoila *et al.*, 2003). This tends to push up the cost of pig production as more money is spent on inspections to insure pork is safe for human consumption.

2.5.2 Impact of *T. solium* infection on public health and social life

Taenia solium infections are a source of great concern to human health. It is considered to be a public health problem in several developing countries in which social, economic and cultural Conditions favour the maintenance of this zoonosis (Flisser *et al.*, 2003). It is estimated that over 50 million people are infected by the parasite, mostly in the developing world (Almeida *et al.*, 2009). Human cysticercosis is highly endemic in Latin America, Asia and Africa, especially where domestic pig husbandry is practiced. It is also increasingly being seen in industrialised countries due to immigration of tapeworm carriers (Mayta *et al.*, 2008; Sarti *et al.*, 1997). As globalization increases, tourism, refugee movements, and immigration from endemic regions have resulted in more NCC cases in areas where it was previously considered rare or non-existent (Huisa *et al.*, 2005).

The parasite can cause disease in two forms in humans. Taeniasis which is the presence of the adult tapeworm in the human intestines or cysticercosis which is the metacestode stage in human body organs (Flisser *et al.*, 2003; Garcia *et al.*, 2003). Taeniasis has not been reported to cause serious disease in humans, though abdominal discomfort may occur in a few cases (Garcia *et al.*, 2003). Cysticercosis is the major cause of human disease due to the metacestode stage of the parasite. The disease may be the neural form NCC or the extraneural form. NCC, which is caused by infestation of the human CNS with the tissue cysts of *Taenia solium*, is arguably the most common parasitic disease of the human nervous system (White, 1997).

The importance of cysticercosis on human health is rather difficult to estimate because of the highly variable clinical picture of the disease. It ranges from asymptomatic to severe headaches, epilepsy and even death (Sikasunge, 2005). Sikasunge (2005) also said the costs associated with visits to the hospital, cost of serological and/or CT-scan, transport and drugs have to be taken into account

when establishing the cost of human cysticercosis. Like many complex diseases that evolve over a long time, multiple types of treatments are used for NCC (Nash *et al.*, 2006). This makes the cost of treating NCC more costly as different drugs need to be used for different situations. The annual economic loss due to taeniasis (all species including *Taenia asiatica*) in the mountainous regions of Taiwan, Cheju island of Korea and Samosir island of Indonesia amounted to US\$ 18 million, US\$ 13 million and US\$ 2.4 million, respectively (Rajshekhar *et al.*, 2003). In Mexico, more than US\$17 million is spent annually in hospitalization and treatment costs for humans with neurocysticercosis (Murrell, 1991). Roberts *et al.* (1994) estimated that the cost of admission to hospital and wage loss for NCC in the United States (a nonendemic country) was US\$8.8 million annually whereas treatment costs in Mexico were estimated at US\$89 million, while in Brazil it was US\$85 million. The monetary burden in Eastern Cape Province of South Africa was estimated to be US\$34.2 million (Carabin *et al.*, 2006).

NCC has serious social effects on the patient and the community. Preux *et al.* (2000) stated that the social stigma of epilepsy must also be taken into account and that most communities cast out epileptic patients, because epilepsy is considered a contagious and/or a shameful disease. Of Thirty-three epileptic patients surveyed 73 percent believed the disease to be a form of possession, and 76 percent attributed the disease to a spell. 45 percent thought that epilepsy is a disease that should be hidden. Only 9 percent considered epilepsy to be contagious (Preux *et al.*, 2000). In these communities, epileptics are often isolated to prevent the spread of the ailment (Sikasunge, 2005). According to surveys of Preux *et al.* (2000), in West Cameroon only 27 percent of epileptics get married and 39 percent fail to enter into any professional activity. It was also noted 27 percent had secondary school education, 61 percent had stopped in primary school, and 10 percent had no formal education at all. 61 percent had a professional occupation, mainly carpenters (woodworkers), traders, house maids, masons, cultivators, or teachers (Preux *et al.*, 2000).

2.6 Disease due to *T. solium* -taeniasis and cysticercosis

Taenia solium infects both man and pigs. Other animals like dogs and primates play a limited or no role in the life cycle of the parasite. The two forms of the

disease are *Taeniosis* (adult tape infection) and cysticercosis (metacestode stage infection).

2.6.1 Disease in pigs-porcine cysticercosis

Only the metacestode form of the disease occurs in the pig. In pigs, cysticerci may lodge anywhere in the body but show predilection for muscles of the jaws, heart, neck, tongue, elbows, shoulders and the thighs (Phiri *et al.*, 2006; Boa *et al.*, 2002; Smyth, 1994). Cysticerci are frequent in striated muscles, but the heart, abdominal wall, liver, lungs, brain and eyes may be involved (Sikasunge *et al.*, 2008; Soulsby, 1982). Though the predilection sites of cysticerci are mainly the active muscles and brain, during their migration they pass through the liver (Garrido *et al.*, 2007). The infection in pigs appears to be benign, since they do not present overt clinical signs despite the presence of thousands of cysts distributed throughout the body (Alvarez *et al.*, 2002 a,b). However in recent reports, pigs with cysticercosis were reported to have exhibited excessive salivation, blinking and tearing (Prasad *et al.*, 2006) but no clinical signs of intracranial hypertension were found, which is the most severe complication in human NCC (Del Brutto, 1997; Garcia *et al.*, 1997). It is worthwhile noting that this was the only study to have investigated morbidity in pigs with cysticercosis and unless such findings are consistently found elsewhere, any conclusions should be made with caution (Sikasunge, 2009).

2.6.2 Disease in human-taeniosis and cysticercosis

Humans can develop both taeniasis and cysticercosis. Taeniosis occurs only in the human host, after ingestion of undercooked pork infected with cysticerci (Garcia *et al.*, 2003; Gonzalez *et al.*, 2003). Most patients are asymptomatic and will not seek medical attention. Taeniosis is characterised by mild symptoms such as Abdominal pain, distension, diarrhoea, and nausea or none at all (Garcia *et al.*, 2003).

The larval stage of the parasite commonly infects the central nervous system, causing NCC, a pleiomorphic clinical disorder (Garcia *et al.*, 2003). In humans, heavy cyst burden in the brain can cause encephalopathy with fever, headache, nausea and vomiting, altered mental status, and seizures. Controlled field studies have consistently demonstrated the association between NCC and epilepsy

(Rajshekhar *et al.*, 2003; Del Brutto *et al.*, 2005). Cysts also can occur in the subarachnoid or ventricular spaces, sometimes growing large enough to cause meningeal signs and symptoms, obstructive hydrocephalus, or cranial nerve palsies caused by nerve entrapment (Garcia *et al.*, 2003). Less commonly, cysts located in the spinal column can cause radicular pain or paresthesias indistinguishable from other spinal pathologies (Singhi and Singhi, 2004). Ocular cysticercosis can also occur in the sub-retinal space or vitreous humor. Retinal detachment or inflammation due to degenerating cysts can threaten vision (Sharma *et al.*, 2003; Singhi and Singhi, 2004). When cysticerci lodge in extra-ocular muscle, they cause limitations on the range of eye movements that can mimic cranial nerve palsies (Garcia *et al.*, 2003). Skeletal muscle or subcutaneous cysticercosis can cause localized pain and nodules (Garcia *et al.*, 2003). Outside the central nervous system, cysticercosis causes no major symptoms. Subcutaneous cysticercosis presents as small, movable, painless nodules that are most commonly noticed in the arms or chest. After a few months or even years, the nodules become swollen, tender, and inflamed, and then they gradually disappear. Subcutaneous cysticercosis is rare in Latin America but very common in Asia and Africa (Garcia *et al.*, 2003). In rare cases, very massive parasite burdens enlarge the patient's limbs (muscular pseudohypertrophy) (Garcia *et al.*, 2003).

2.7 Epidemiology and risk factors of *T. solium*

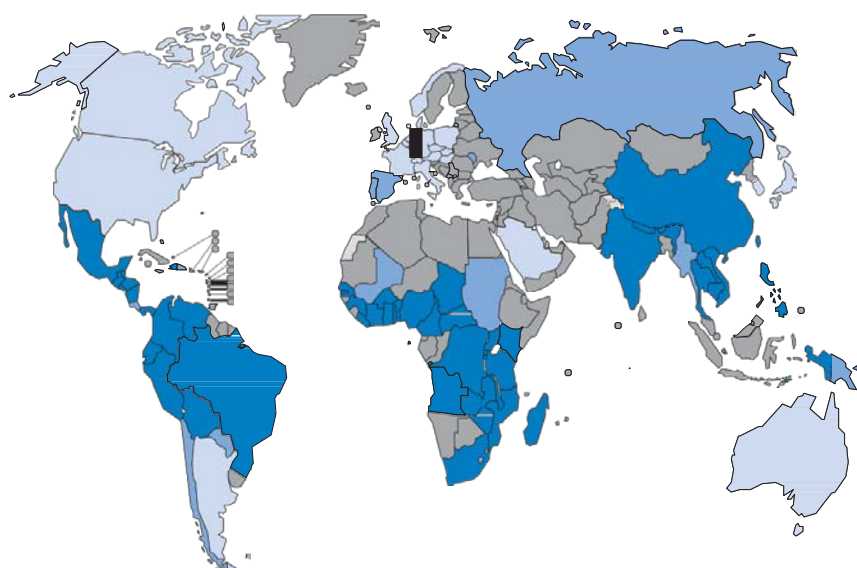
2.7.1 Distribution

Taenia solium infections occur in most developing countries of the world, with a few cases being seen in some developed countries. *Taenia solium* infection and the resulting disease NCC are endemic in less developed countries where pigs are raised as a food source (Garcia *et al.*, 2003). NCC is common throughout Latin America, most of Asia, sub-Saharan Africa, and parts of Oceania, and is the greatest cause of acquired epilepsy worldwide. It is now increasingly diagnosed in more developed countries owing to immigration of tapeworm carriers from endemic zones (Garcia *et al.*, 2003). Cysticercosis mainly affects

the health and livelihoods of subsistence farmers in developing countries of Africa, Asia and Latin America.

In Latin America, Cysticercosis has been a serious problem for decades. Hotspots of the disease include the Bolivarian Republic of Venezuela, northern Brazil, Colombia, Ecuador, Guatemala, Honduras, Mexico, Nicaragua, Peru and the Plurinational State of Bolivia. The disease is also endemic in Haiti and possibly the Dominican Republic. Studies in Brazil and the United States indicate that NCC is an important cause of human deaths (Garcia *et al.*, 2003). Cysticercosis has also emerged as a public-health and agricultural problem in most of sub-Saharan Africa, from Cape Verde to Madagascar, because of the increase in the number of pigs being kept for pork under free range system. Exception of the WHO's African Region include the mainly Muslim countries of Algeria, the Comoros, Mauritania and Niger, as well as in countries with low pork consumption, such as Botswana, the Congo, Gabon and Namibia. Community-based surveys of human and porcine cysticercosis have been undertaken in the following countries where the disease is believed to be prevalent, though mainly with focal distribution: Benin, Burkina Faso, Burundi, Cameroon, the Central Africa Republic, Chad, Cote d'Ivoire, and the Democratic Republic of the Congo, Ghana, Kenya, Madagascar, Mozambique, Nigeria, Rwanda, Senegal, South Africa, Togo, Uganda, the United Republic of Tanzania, Zambia and Zimbabwe (WHO, 2010).

In Asia, the disease is endemic in Bhutan, India, parts of Indonesia (Bali and Papua), Nepal and Timor-Leste; the situation is unknown in Bangladesh, the Democratic People's Republic of Korea and Sri Lanka. Case reports suggest that the disease is endemic in Myanmar and Thailand; a recent survey indicated taeniasis *solium* (presence of adult *T. solium* in human intestine) is common in western Thailand. Cysticercosis has also been reported in 29 administrative divisions of China (WHO, 2010). Figure 2.5 shows the areas where the disease is present.



- Endemic (full life-cycle)
- Suspected endemic
- Imported cases (possible human cysticercosis transmission)
- No data available

Figure. 2.4 Countries and areas at risk of cysticercosis. (WHO, 2010).

2.7.2. Risk factors

Occurrence and prevalence of *Taenia solium* is associated with certain cultural practices such as eating raw or undercooked pork and poor socio-economic conditions (Sikasunge *et al.*, 2007). A number of factors have been identified as being responsible for the occurrence of *T. solium* infections in most parts of the developing world. Risk factors include free-range pig farming (in developing countries, pigs are often allowed to roam), poor sanitation, close contact of humans and pigs and inadequate meat inspection (Winkler *et al.*, 2009). In an urban community of Honduras, Sanchez *et al.* (1998) showed that seropositivity was statistically associated with poor household conditions such as raising pigs, lack of potable water, lack of sanitary toilet earthen floor. Seropositivity was also associated with low academic education and lack of knowledge about the parasite (Sanchez *et al.*, 1998). Cysticercosis is thus strongly associated with poverty (Winkler *et al.*, 2009). A study conducted in rural areas of Eastern and Southern provinces of Zambia by Sikasunge *et al.* (2007) also found that *T. solium* infections were associated with lack of pork inspection at slaughter (96.7 percent), consumption of pork with cysts (20.1 percent), selling of pork infected

with *T. solium* cysticerci (18.3 percent), free-range husbandry system (83.2 percent) and absence of latrines (58 percent). People who neither raise pigs nor consume pork are also at risk of cysticercosis, if they ingest *T. solium* eggs after coming into direct or indirect contact with tapeworm carriers like through food, water, wind, flies and other indirect means of infection (Winkler *et al.*, 2009; Garcia *et al.*, 2003). Schantz *et al.* (1992) found intracerebral infection with the larval stage of the pork tapeworm *T. solium* in four unrelated persons in an Orthodox Jewish community in New York City. None of the patients had eaten pork, and only one had travelled to a country in which *T. solium* infection was endemic. Thus, vegetarians and other people who do not eat pork can acquire cysticercosis (Garcia *et al.*, 2003). Due to socio-economic factors and lack of information, *T. solium* infections still pose a great risk to the health of most people in developing countries.

2.8 Diagnosis of *T. solium* infections

2.8.1 Diagnosis of porcine cysticercosis

2.8.1.1 Parasitological methods

2.8.1.1.1 Tongue inspection

In animals, ante mortem diagnosis is routinely performed in pigs, by visual inspection and palpation of the tongue (Rodriguez-Hidalgo, 2007). Looking for metacestodes in the eyes has been reported but has a low sensitivity (Rodriguez-Hidalgo, 2007). Tongue examination is the most common method of diagnosing porcine cysticercosis in vivo at the village level. This is done by inspecting the ventral surface of the tongue (Sikasunge, 2005). However, tongue examination requires technical skills and has low sensitivity (Scuitto *et al.*, 1998a). The vesicular metacestodes can be palpated and easily seen. However, fibrous or calcified larvae (cysts) are more difficult to detect, as they tend to be quite small (Scuitto *et al.*, 1998b). This is in contrast with the calcified cysts of *Taenia saginata*, which are comparatively easy to identify at meat inspection because they often form white and fibrotic lesions (Onyango-Abuje *et al.*, 1996). In many endemic countries, tongue inspection is carried out by the local population in order to identify pigs infected with *T. solium* cysticercosis. If carried out correctly (both palpation and visual inspection throughout the base) by experienced people, it is generally agreed that the specificity of this technique is 100 percent (Dorny *et*

al., 2004; Gonzalez *et al.*, 1990). The sensitivity of the technique, however, depends very much on the degree of infection of the animals. Although in heavily infected animals, tongue inspection might detect up to 70 percent of the cysticercotic pigs, in lightly infected animals the sensitivity is much lower (Murrel *et al.*, 2005). Scuitto *et al.* (1998a) also reported that the maximal sensitivity obtained by tongue examination were 71 percent in experimentally infected pigs. Several studies have shown that in experimentally or naturally infected pigs harbouring less than 100 cysts, none of the animals could be detected by tongue inspection (Dorny *et al.*, 2004; Nguekam *et al.*, 2003). In moderately to heavily infected animals (>100 cysts) the sensitivity is lower than 50 percent (Phiri *et al.*, 2002; Pouedet *et al.*, 2002). In Zambia, using Bayesian analysis, the overall sensitivity of tongue inspection was estimated at 21 percent (Dorny *et al.*, 2004).

2.8.1.1.2 Meat inspection

The procedures for the detection of *T. solium* cysticercosis during conventional meat inspection vary widely from one country to another. In some countries, visual inspection only is carried out on one or several so-called predilection sites, such as the heart, diaphragm, masseter muscles, tongue, neck, shoulder and intercostal and abdominal muscles (Murrel *et al.* 2005). Scuitto *et al.* (1998a) estimated that more than 50 percent of pigs that harbour metacestodes show them in the tongue, and recommended the tongue as one of the sites for meat inspection in addition to the diaphragm or the shoulder muscles. In other countries, regulations also require incisions in some of these muscles. It is obvious that the efficacy of meat inspection will depend not only on the thoroughness of the inspection methods, but also on the degree of infection of the pigs. Given the fact that, in rural areas of Africa and South America, lightly infected animals have been shown to occur more frequently than previously believed (Dorny *et al.*, 2004; Scuitto *et al.*, 2000; Scuitto *et al.*, 1998), meat inspection in these areas will seriously underestimate the real prevalence of porcine cysticercosis. Using a Bayesian approach, the overall sensitivity of meat inspection in Zambia (only visual examination of masseter muscles, triceps brachii, tongue and heart) was estimated at 22.1 percent (Dorny *et al.*, 2004). Although detection of cysticercosis infection is routinely done at meat inspection, the technique is time consuming and infected carcasses are easily missed and passed on for human consumption

(Gonzalez *et al.*, 1990). Another disadvantage of meat inspection is that infection is detected after the death of an animal, which is too late to make any decision over the treatment (Onyango-Abuje *et al.*, 1996).

2.8.1.2 Serological methods

Immunodiagnosis in pigs is used in prevalence surveys, community-based surveys and in intervention studies. In endemic areas, pigs can also be used as sentinels to measure the environmental contamination of *T. solium* eggs (Murrell *et al.*, 2005). Most of the techniques developed for the diagnosis of cysticercosis in humans have been adapted for analysing pig sera, including the EITB (Tsang *et al.*, 1991), Ab-ELISA using isoelectric focusing-purified glycoproteins (Ito *et al.*, 1998; Sato *et al.*, 2003), and Ag-ELISA (Dorny *et al.*, 2004). The benefits of immunodiagnosis in pigs are: (i) tests offer diagnosis on live animals; (ii) blood sampling followed by serological testing is more sensitive than the tongue examination; and (iii) the tests are relatively inexpensive and easy to perform on large numbers of serum samples (Dorny *et al.*, 2003).

2.8.2 Diagnosis of taeniosis

Several techniques are available for the diagnosis of taeniosis (adult worm intestinal infection): questioning, faeces microscopy, the peri-anal adhesive tape test, the ELISA for Coproantigen or circulating antibodies, the differentiation of somata based on morphology or isoenzyme patterns and molecular tests such as the polymerase chain reaction (PCR). All have advantages and disadvantages.

2.8.2.1 Questioning of tapeworm carriers

Proglottids of the tape are realised in human excreta. Carriers may notice this is the faecal material. Asking them if they have noticed this can also be used to diagnose tape worm carriers. Spontaneous expulsion of proglottids (independent of defecation) generally occurs with *T. saginata* and *T. s. asiatica*, and exceptionally this has been observed for *T. solium* (Rodriguez-Hidalgo *et al.*, 2002). Therefore, *T. saginata/T. s. asiatica* carriers are often aware of the presence of a worm, which is not necessarily the case for *T. solium* carriers, where the expulsion of proglottids is passive (together with faeces). Furthermore, it has been observed that patients cannot always distinguish tapeworm proglottids from nematodes like *Enterobius vermicularis* leaving the body or the spontaneous expulsion of the large roundworm *Ascaris lumbricoides*, resulting in false positive

answers. Therefore, questioning can be used as an auxiliary method for the diagnosis of *T. saginata* /*T. s. asiatica*, but is certainly not reliable in the case of *T. solium* (Murrel *et al.*, 2005).

2.8.3.2 Peri-anal swabs

Taenia spp. eggs sticking to the skin in the peri-anal region can be detected by using adhesive tape ('Scotch' tape), also known as the method of Graham. For the detection of *T. saginata* eggs the perianal swab is considered to be more sensitive than a single coprological examination (Murrel *et al.*, 2005). Although less data are available for *T. solium*, the eggs of this parasite are also frequently found using the 'Scotch' tape technique (Schantz and Sarti, 1998).

2.8.2.3 Microscopy (morphological criteria)

Several methods have been described to detect intestinal taeniasis. Microscopic diagnosis is based on the search of proglottids or ova (eggs) in the faeces or on the recovery of the worm after treatment (Rodriguez-Hidalgo, 2007; Ir TIDO, 2004). Morphological characteristics allow for a distinction between *T. solium* and *T. saginata* based on proglottids or the scolex (Rodriguez-Hidalgo, 2007). Although it is theoretically possible to distinguish the three adult taeniids on the basis of morphological characteristics of the scolex or the mature proglottids, the former is rarely available after treatment with modern anthelmintics, whereas the latter need to be fixed and stained in order to examine the ovarian lobes and the vaginal sphincter, a laborious procedure (Murrel *et al.*, 2005). Since morphological abnormalities are not uncommon in taeniids, the presence or absence of hooks on the scolex does not automatically indicate that it is *T. solium* or *T. saginata*/*T. s. asiatica* (Rodriguez-Hidalgo *et al.*, 2002). In most cases, gravid proglottids of *T. saginata* and *T. solium* can be distinguished on the basis of the number of unilateral uterine branches (Murrel *et al.*, 2005). However, some overlapping might occur (Murrel *et al.*, 2005). Therefore, if the number of uterine branches falls between 11 and 16, it is advised to confirm the identity of the tapeworm using molecular tools or enzyme electrophoresis (Murrel *et al.*, 2005). Routine diagnosis is based on the microscopic detection of *Taenia* spp. oncospheres in direct smears or after concentration methods such as the Kato-Katz and formol-ether methods. On the basis of the eggs, coprological techniques do not allow

differentiation of *T. solium* and *T. saginata* infections because their eggs are morphologically identical (Murrel *et al.*, 2005; Ir TIDO, 2004). These methods have a sensitivity of around 38 percent to 60 percent (Allan *et al.*, 1996; Sarti, 1997). Due to the low sensitivity of these techniques (Flisser, 2003), many infected persons are not detected.

2.8.2.4 Differentiation based on enzyme electrophoresis

A simple technique to differentiate taeniid somata, based on glucose phosphate isomerase (E.C.5.3.1.9.) zymogrammes has been described by Le Riche and Sewell (1978). The technique is faster and less labour intensive than staining tapeworm material. It can be applied on a routine basis when direct morphological observations remain indecisive; however, it requires preferably fresh or frozen material. Typical preservative solutions for segments such as alcohol or formalin will destroy enzyme activity (Murrel *et al.*, 2005).

2.8.2.5 Serological tests

Serological methods can also be used to detect antigens or antibodies in the diagnosis of taeniasis. These include ELISA methods and Immunoblot. The methods are carried out in the same way as for diagnosing human cysticercosis as described in section 2.7.1 on diagnosis of human cysticercosis. The possibility of diagnosing *T. solium* taeniosis by the detection of species-specific circulating antibodies has been demonstrated (Wilkins *et al.*, 1999). Diagnosis of taeniasis by serological examination has obvious advantages over the faeces-based methods, like species-specific diagnosis, avoidance of the potential biohazard of collecting and handling faeces, and also the possibility to combine this test with other immunological assays in the diagnosis of human cysticercosis (Rodriguez-Hidalgo, 2007; Murrel *et al.*, 2005). However, residual antibodies from past exposure might result in false positives (Allan *et al.*, 2003; Ito and Craig, 2003).

2.8.2.6 Coproantigen detection by ELISA

Taenia solium coproantigens are parasite specific products in the faeces of the host that can be detected by a polyclonal antibody-based sandwich ELISA (Murrel *et al.*, 2005). The presence in the faeces of tapeworm metabolic products with antigenic capacity has been used to prepare specific polyclonal antibodies that

allow the detection of coproantigens by ELISA (Allan *et al.*, 1990). These antibodies are obtained from hyperimmune rabbit sera raised against *T. solium* adult worm somatic antigens (Allan *et al.*, 1990). The use of this test increases the detection of parasitologically proven intestinal *T. solium* cases by a factor of at least 2.6 times in comparison to microscopy (Allan *et al.*, 1993). Coproantigens are stable for weeks in unfixed faecal samples kept at room temperature and for years in frozen samples or in chemically fixed samples (e.g. formalin) kept at room temperature. Coproantigens can be detected prior to patency and they are no longer detectable within a week of treatment. A major disadvantage of this test is that it is only genus specific, making it impossible to differentiate *T. solium* and *T. saginata* infections (Rodriguez-Hidalgo, 2007; Murrel *et al.*, 2005; Schantz *et al.*, 1998). According to Allan *et al.* (1990) coproantigen detection has specificity and sensitivity of 100 percent and 98 percent respectively. However, some studies in Guatemala and Peru demonstrated a lower sensitivity (Rodriguez-Hidalgo, 2007). Wilkins *et al.* (1999) developed a serologic assay to identify adult *T. solium* tapeworm carriers using excretory/secretory antigen collected from in vitro cultured *T. solium* tapeworms and the test was identified to be 95 percent sensitive and 100 percent specific. The test shows no cross-reactions with other intestinal helminth infections including *Ascaris*, *Trichuris* and *Hymenolepis* spp. (Allan *et al.*, 1996). Coproantigen testing for *Taenia* has also been carried out using a dipstick ELISA format (Allan *et al.*, 1993). This field test proved faster, but less sensitive, than the micro-plate assay.

2.8.2.7 Copro Polymerise chain reaction PCR

Methods have been developed to extract DNA of *Taenia* spp. from human feces, which can be used in a Polymerise chain reaction (PCR) for diagnosis of taeniosis (Yamasaki *et al.*, 2004; Nunes *et al.*, 2003). Molecular techniques for the detection and differentiation of *Taenia* species using gDNA and/or mtDNA include Dot Blot analysis, Multiplex-PCR, a based excision sequence scanning thymine-base reader analysis and random amplified polymorphic DNA (RAPD) (Murrel *et al.*, 2005). The high sensitivity and species-specific detection of the immature stages are definite advantages of this test. However, current DNA extraction methods are too expensive for use as a routine test (Murrel *et al.*, 2005).

2.8.3 Diagnosis of human cysticercosis

2.8.3.1 Parasitological diagnosis

The diagnosis of *T. solium* cysticercosis (extraintestinal metacestode stage) is made parasitologically by demonstrating the scolex with the hooks or fragments of the bladder wall in biopsy or autopsy material (Murrel *et al.*, 2005). In some parts of Asia, especially, where subcutaneous cysticercosis is rather frequent (Rajshekhar *et al.*, 2003), it is easy to obtain biopsy material for further histopathological confirmation. With less invasive techniques such as fine needle cytology, the diagnosis of cysticercosis can often be made (Kapila *et al.*, 2003).

2.8.3.2 Serological diagnosis

Immunological methods for the diagnosis of human cysticercosis can be used for the detection of individual cases or for epidemiological surveys. In the former, sensitivity is more important than specificity, since the diagnosis is usually made on an individual who has symptomatology suggestive for cysticercosis. For epidemiological purposes, the specificity of the test is an important factor. Immunodiagnostic techniques include detection methods for specific antibodies and for circulating parasite antigens in serum or cerebral spinal fluid (CSF) (Murrel *et al.*, 2005). Dorny *et al.* (2004b) also noted that Antibody detection tests (ELISA and EITB) are the most appropriate tools for measuring exposure to *T. solium* in sero-epidemiological surveys and confirmation of *T. solium* as aetiological agent of epilepsy. Complement fixation, indirect haemagglutination, ELISA and EITB are among the types of immunodiagnostic assays that have been developed to detect human cysticercosis (Carpio, 2002). Western blot and enzyme linked Immunosorbent assay have good sensitivity and specificity, the former being more reliable (Flisser, 2003). Other tests that detect antibodies are; radioimmunoassay, dipstick-ELISA, and latex agglutination (Dorny *et al.*, 2003).

2.8.3.2.1 Antibody detecting Enzyme-Linked Immunosorbent Assay

Infection with *T. solium* results in a specific antibody response, mainly of the IgG class (Carpio *et al.*, 1998). Antigens used in these tests are either cyst fluid or crude homogenates of *T. solium* cysticerci or crude preparations of the related parasite *Taenia crassiceps*, which can be maintained in laboratory rodents (Pardini

et al., 2002). These unpurified antigens have moderate sensitivities and relatively poor specificities (Schantz and Sarti, 1989; Fleury *et al.*, 2003). Research on the antigenic properties of cyst fluid and surface-associated glycoproteins, and improved protein purification techniques have resulted in much more reliable serological tools (Pardini *et al.*, 2002; Ito *et al.*, 1998; Tsang *et al.*, 1989; Gostein *et al.*, 1986). Using saline extract and vesicular fluid of *T. solium* cysts Shiguekawa *et al.* (2000) found that ELISA sensitivity at 1: 20 and 1: 100 sera dilutions was, respectively, 90 percent and 85 percent for saline extract, and 95 percent and 90 percent for vesicular fluid. The ELISA specificity at 1: 20 and 1: 100 dilutions was, respectively, 52 percent and 88 percent for SE and 74 percent and 96.5 percent for VF. Zimic *et al.* (2009) used purified protein fraction including antigens of 53 and 25 kDa and found the sensitivity of the ELISA was 98 percent in patients with multiple cysts and 84 percent in patients with a single cyst. Specificity was 92.7 percent.

Despite having less sensitivity and specificity than Immunoblot, in developing countries, ELISA is preferred because of its better availability, its simplicity and its lower cost compared to Immunoblot (Rosas *et al.*, 1986). Purification of glycoproteins from cyst fluid by single step preparative isoelectric focusing was shown to produce very specific antigens, which are applicable both in Immunoblot and ELISA (Ito *et al.*, 1998). The specificity and sensitivity of this ELISA were reported to match those of the Immunoblot (Ito *et al.*, 2002). The other disadvantage is that because all three taeniid (*T. solium*, *T. saginata* and *T. asiatica*) infections are related, there is considerable similarity in the antigenic profile of the different metacestodes, implying cross reactions in areas where more than one species is present (Rogan and Craig, 2002). As in porcine Ab-ELISA, antibodies due to previous infections are also detected by the test, in the absence of active infection resulting in false positives.

2.8.3.2.2 Enzyme-Linked Immunotransfer Blot (EITB) or Western Blot

The most specific test developed is the EITB, an Immunoblot of seven cysticercus glycoproteins, purified by lentil lectin-purified chromatography, which gives close to 100 percent specificity and a sensitivity varying from around 70 percent to 90 percent (Tsang *et al.*, 1989). Other studies have also found that serum EITB is highly sensitive (more than 90 percent) and specific for the diagnosis of human

cysticercosis, but in patients with a single brain cyst, the sensitivity was only 25 percent (Carpio, 2002). Wilson *et al.* (1991) also found a sensitivity of only 28 percent in cases with single, enhancing parenchymal cysts in the brain. Other studies show that in patients with a single intracranial cysticercus, it shows a lower sensitivity of less than 50 percent and specificity 65 percent (Wilson *et al.*, 1991; Proaño-Narvaez *et al.*, 2002). In cases where two or more cysts are present, EITB is very sensitive, 100 percent and 95 percent using serum or cerebrospinal fluid (CSF) respectively and 99 percent specific for either sample (Wilkins *et al.*, 2002). In addition, an EITB is more likely to show a positive result in patients with calcified lesions than in those with active or transitional cysts and EITB may become negative after the cysticercus dies (Ir-TODO, 2004).

Purification of glycoproteins from cyst fluid by single step preparative isoelectric focusing was shown to produce very specific antigens, which are applicable both in Immunoblot and ELISA (Ito *et al.*, 1998). Since the preparation of purified antigens relies on the availability of parasite material and may be subject to the quality of this material, attempts were made to produce recombinant antigens and synthetic peptides. Different authors synthesised 7-10, 10 and 14 kDa recombinant polypeptides that can be used in Immunoblot and ELISA (Sako *et al.*, 2000; Chung *et al.*, 1999). While the specificity of these antigens is reported to be high, the sensitivity is generally lower than with the native antigens. As in Ab-ELISA cross reactions occur when crude antigen is used (Rogan and Craig, 2002). The test is also more technical (Carpio, 2002) and expensive compared to ELISA (Rosas *et al.*, 1986), thus limiting its use in developing countries.

2.7.3.2.3 Antigen detection methods

To overcome the fact that the presence of antibodies does not constitute direct evidence of a living parasite, several attempts have been made to develop antigen-based assays based on polyclonal and monoclonal antibodies (Carpio, 2002). Several assays have been developed to detect parasite antigens, but only the monoclonal antibody based ELISA directed at defined parasite antigens (Ag-ELISA) may ensure reproducibility and specificity (Dorny *et al.*, 2003). Antigen detection, monoclonal antibody-based sandwich-ELISA's have been developed. These tests allow detection in serum of excretory/secretory products of *Taenia spp.* cysticerci (Rodriguez-Hidalgo, 2007). Antigen detection can be done on

serum as well as on CSF (Garcia *et al.*, 1998; Garcia *et al.*, 2000). Because of the localisation of the cysts in the brain, antigen detection in CSF may be more appropriate for diagnosis than in serum. However, sampling of CSF is more cumbersome than blood sampling (Murrel *et al.*, 2005). The application of sandwich ELISA for detection of circulating parasite antigens presents some diagnostic advantages since it does not demonstrate exposure but identifies active infections (Dorny *et al.*, 2003).

Because the detection of antigens correlates with the presence of live cysticerci, it has been shown that Ag-ELISA is useful in monitoring disease progression and anticysticercal therapy (Garcia *et al.*, 2000; Nguekam *et al.*, 2003). However Ito *et al.* (2004) believes that there is no evidence to suggest that the Ag-ELISA is better than Ab-ELISA for the detection of active cysticercosis. Ag-ELISA detects only cases of active cysticercosis, i.e. the presence of living cysticerci (Garcia *et al.*, 2002; Erhart *et al.*, 2002; Garcia *et al.*, 2003; Nguekam *et al.*, 2003). Detection is restricted to the presence of viable larvae; degenerated or calcified cysts are not detected by the test (Rodriguez-Hidalgo, 2007). A sensitivity of 85 percent by antigen detection ELISA was found in selected EITB-seropositive patients (Garcia *et al.*, 2000). Furthermore, the sensitivity in patients with a single viable cyst or only enhancing lesions was 65 percent (Garcia *et al.*, 2000). This shows that the sensitivity of the Ag-ELISA is very high, even in light infections. The Ag-ELISA is very specific, and no cross-reactions have been observed in sera from patients with confirmed infections with *Schistosoma*, hydatid cysts, *Ascaris*, *Trichuris*, filaria, *Entamoeba*, *Plasmodium* and *Trypanosoma* (Erhart *et al.*, 2002). Specificity is at the level of the genus, which allows use for the diagnosis of *T. saginata* in bovines and of *T. solium* in humans and pigs. Since these antigen detection assays are only genus specific, their use is limited in areas where hydatidosis and cysticercosis are co-endemic (Correa *et al.*, 2002). Since *T. hydatigena* does not occur in humans, the monoclonal antibody-based ELISA can be used for the diagnosis of human cysticercosis (Dorny *et al.*, 2004b).

2.8.4 Diagnosis of human neurocysticercosis

2.8.4.1 Neuroimaging

Frequently, the diagnosis and clinical care of patients with NCC involve the use of sophisticated and expensive radioimaging techniques such as computer assisted tomography (CT) and magnetic resonance imaging (MRI) and serological tests employing Western blots. These technologies are commonly not available in the developing world which necessitates the primary use of symptomatic care under these conditions (Murrel *et al.*, 2005). Serological methods are not reliable for diagnosis of NCC because the important features in diagnosing NCC are the number, size, and location of lesions. Initially, skull and soft-tissue radiographs showed calcifications, and arteriography and pneumoencephalography showed lesions causing mass effect and hydrocephalus. Both techniques are no longer being used for this purpose due to the danger they pose to the patient. Lately, computer-based imaging procedures have enabled visualisation of the brain and other intracranial soft structures. Currently used techniques include CT and MRI (Garcia *et al.*, 2003). Human NCC can be diagnosed by MRI or/and CT-scan, which identify vesicular (viable), colloidal (degenerating) and calcified cysticerci or lesions related with cysticercosis in the CNS (Garcia *et al.*, 2005). These neuroimaging techniques are considered as reference diagnostic tools. However, their cost and restricted availability (patients have sometimes to travel long distances) limits their use. Moreover, interpretation of the images demands skilled experts. Also, only patients with neurological symptoms will undergo a brain scan, meaning that if these symptoms are caused by cysticerci, in most cases the degenerating process has already started, which may be too late to start a causative treatment (Rodriguez-Hidalgo, 2007).

2.8.4.1.1 Computed Tomography

The basic physics principle of CT scanning is the reconstruction of an object internal structure from different projections, which are based on X-rays emitted towards the object from different angles. The object presents a variety of absorption rates depending on its constituent tissues. For this reason, when all projections are integrated, CT images are much sharper than X-rays, showing a higher definition not only in bone structures but also in soft tissues (Hsieh, 2009).

C T-scan has high sensitivity and specificity in the diagnosis of most forms of NCC. The classic image of multiple cysts with an internal eccentric scolex is pathognomonic, and multiple round, punctate calcifications are also highly suggestive, as are mixed forms (Garcia *et al.*, 2006). CT has been claimed to have sensitivity and specificity of over 95 percent for the diagnosis of NCC, (Garcia *et al.*, 2003) although CT images are rarely pathognomonic for this disease (Garcia *et al.*, 1994). The availability of antiparasitic treatments and serial CT studies has allowed the description of imaging changes throughout the involution process. Cysts appear as hypodense images, with well-defined edges, and commonly a hyperdense nodule inside the cyst shows the parasite's scolex (Garcia *et al.*, 2003). Parasite degeneration initially appears as contrast enhancement of the edges of the cyst and perilesional oedema, resulting from the inflammatory reaction in the surrounding tissue (Vasconcelos *et al.*, 1990). In later stages, the cyst becomes isodense to the parenchyma but appears after the administration of contrast, enhancing as a nodule or a ring (Garcia *et al.*, 2003). CT examination best detects the characteristic punctate calcifications as part of the diagnostic evaluation (Murrel *et al.*, 2005) and most appropriately confirms the presence of a calcified focus associated with perilesional edema. The sensitivity of CT is much lower for ventricular or cisternal forms of the disease. Intraventricular cysticercosis presents with obstructive hydrocephalus, and only indirect signs such as cavity enlargement or deformation are seen on CT.

2.8.4.1.2 Magnetic Resonance Imaging

The MRI physics principles are based on the resonance capacity of certain atoms, particularly the protons. When an object is exposed to a strong magnetic field, the small magnetic fields produced by the protons get positioned in a particular direction. After a radiofrequency pulse application, an exciting and relaxing response of the protons is obtained. This response is called resonance, and can be measured and quantified to determine the type of tissue that is being analysed (Brown and Semelka, 2003). In the human body, the molecule responsible for most of this kind of resonance is water, since it contains two protons and is

present in the tissues in a high percentage. MRI is more sensitive than CT for detection of the scolex and for the diagnosis of extraparenchymal NCC (Singhi, 2011). MRI examinations are more sensitive in detecting non-calcified parenchymal, subarachnoid, or ventricular cysts and the presence of associated inflammation (bright signals on T2 and FLAIR techniques) or breakdown in the blood brain barrier as determined by leakage of injected gadolinium (enhancement) from the blood vessels (Murrel *et al.*, 2005). MRI is also the most accurate technique to assess the degree of infection, the location, and the evolutionary stage of the parasites. It visualises well the perilesional oedema and the degenerative changes of the parasite, as well as small cysts or those located in the ventricles, brainstem, cerebellum, eye, and basal racemose vesicles (Garcia *et al.*, 2003). Studies comparing the two imaging techniques (MRI and CT-Scan) have concluded that MRI is more sensitive and specific for identifying most forms of NCC with the exception of microcalcifications (Schantz *et al.*, 1998). MRI has several obvious advantages: better resolution, capacity to present images in different axes, and it does not use contrast. All of this results in better discrimination for small lesions, areas of inflammation, the presence of intraventricular parasites, and lesions close to bony structures. But it should be noted that small calcifications are better seen on CT than on MRI (Garcia *et al.*, 2006). CT is more sensitive for the detection of calcifications (Garcia *et al.*, 2003). MRI may at times miss small calcified lesions (Singhi, 2011; Murrel *et al.*, 2005). The main disadvantages of MRI are its high cost and scarcity (Garcia *et al.*, 2003).

MRI studies, like CT-scan studies, have allowed the description of imaging changes throughout the involution process. On MRI, the parenchymal scolex is seen as a nodule that is isointense or hyperintense relative to white matter. It is better seen on fluid attenuated inversion recovery (FLAIR) or diffusion weighted images, as the bright perilesional oedema and the high-intensity cystic fluid obscure the scolex on T2 weighted images. Gadolinium-enhanced MRI shows ring enhancement of lesions (Singhi, 2011). A study on the evolution of MRI characteristics in single-lesion NCC showed that cyst contents were initially T1 hypointense and T2 hyperintense with inversion on FLAIR in 30.8 percent cases but on later scans the contents were T2 hypointense. The cyst wall appeared

initially as a T2 hypointense rim but subsequently became hyperintense. The enhancement pattern of the lesion changed from an initial ring to subsequent disc enhancement (de Souza *et al.*, 2010). On MRI, vesicular cysts appear as round lesions either isointense or slightly hyperintense to the CSF. Calcified lesions appear hypointense on all MRI sequences and small lesions may at times be missed (Singhi, 2011).

2.8.4.2 Serology

Diagnosis of NCC is suggested by clinical, epidemiological, and serological findings, but magnetic resonance imaging or computed tomography (CT) scans are the most sensitive and specific diagnostic tools. To support them (Imaging methods), several laboratory methods have been standardized, which are based on the detection of antibodies against cysticerci or parasite antigens in the cerebrospinal fluid (CSF) or serum (Proaño-Narvaez *et al.*, 2002). Serology is typically used to confirm the diagnosis made with neuroimaging (Garcia *et al.*, 2006). This is because the most commonly used ELISA cross-reacts with *Hymenolepis nana* and *Echinococcus granulosus*, which are common cestode infections. For this reason, ELISA is much more useful when applied to samples of CSF than of serum, with the drawbacks of the invasiveness and pain associated with the lumbar puncture (Garcia *et al.*, 2003). Detection of circulating cysticercosis antigens using ELISA has a modest sensitivity especially for parenchymal lesions. The Ab-ELISA has a better sensitivity with the use of CSF samples as compared with serum samples (Singhi, 2011). The method of choice, an EITB assay using purified glycoprotein cyst antigens, has a specificity of 100 percent and overall sensitivity of 98 percent in patients with more than one cyst (Garcia *et al.*, 2006; Singhi *et al.*, 2011). This assay can be performed with either serum or CSF samples without losing sensitivity. However, the sensitivity of serology is significantly less in patients harbouring a single cyst, and patients with only calcified lesions can be seronegative. Unfortunately, the EITB assay requires sophisticated equipment and highly trained personnel (Garcia *et al.*, 2006). Therefore, the ELISA method is still the most commonly used method in developing countries.

2.8.4.3. Diagnostic criteria for neurocysticercosis

Even with neuroimaging methods and sensitive and specific serological tests, diagnosis of NCC remains difficult. Therefore, a panel of experts designed diagnostic criteria for NCC, which evaluates the clinical, radiological, immunological and epidemiological data of patients (Rodriguez-Hidalgo, 2007). The general opinion is that consistent diagnostic criteria of NCC should be based on combined neuro-imaging studies, serological tests, clinical presentation and exposure history (Murrel *et al.*, 2005). These proposals are divided in absolute, major, minor and epidemiologic criteria based on their individual diagnostic strength (Del Brutto *et al.*, 2001).

Absolute criteria permit unequivocal diagnosis even if standing alone (Rodriguez-Hidalgo, 2007). Absolute criteria includes histological demonstration of the parasite from biopsy of a brain or spinal cord lesion, cystic lesions showing the scolex on CT-scan or MRI, or Direct visualization of subretinal parasites (ocular cysts) by fundoscopic examination (Rodriguez-Hidalgo, 2007; Garcia *et al.*, 2003). Major criteria strongly suggest the diagnosis but cannot be used alone to confirm or exclude the disease (Rodriguez-Hidalgo, 2007). Major criteria include lesions highly suggestive of NCC or neuroimaging studies, positive serum Immunoblot for the detection of the anticysticercal antibodies, resolution of cysts after antiparasitic therapy, or spontaneous resolution of enhancing lesions (Rodriguez-Hidalgo, 2007; Garcia *et al.*, 2003). Minor criteria are frequent clinical and radiological manifestations of the disease but are relatively non-specific and therefore are unable to significantly differentiate among the diagnostic possibilities; these include compatible lesions on neuroimaging, compatible clinical manifestations suggestive of NCC, positive cerebrospinal-fluid ELISA for detection of anticysticercal antibodies or cysticercal antigens, or cysticercosis outside the central nervous system (Garcia *et al.*, 2003; Rodriguez-Hidalgo, 2007). Lastly, epidemiological criteria include potential exposure that favours the diagnosis of cysticercosis. These include evidence of household contact with *T. solium* infection, an individual coming from or living in an area where cysticercosis is endemic, or history of frequent travel to disease-endemic areas (Rodriguez-Hidalgo, 2007; Garcia *et al.*, 2003). Combinations of these criteria provide different degrees of diagnostic certainty (Garcia *et al.*, 2003).

Proper use of these criteria might help doctors to avoid incorrect diagnosis and to conduct an appropriate treatment, although this assessment has not been prospectively validated (Rodriguez-Hidalgo, 2007).

2.9. Treatment

2.9.1 Porcine cysticercosis

It has been shown in that cestocidal drugs are useful to eliminate cysticerci in pigs. Oxfendazole has been shown to be highly effective against porcine cysticercosis in muscles, when given as a single dose at 30 mg/kg bodyweight (Gonzalez *et al.*, 1997). Gonzalez *et al.* (1998) reported lower efficacy against brain cysts for the same drug. Albendazole or praziquantel has been restricted to experimental studies; this is due to the need for repeated dosages, secondary effects, high cost and low efficacy against CNS-cysticerci (Rodriguez-Hidalgo 2007). Praziquantel was used in Mexico at 50 mg/kg for 15 days and at 100, 50 or 25 mg/kg divided in three doses and given only 1 day. The effect was evaluated by tomographic, neurophysiologic, immunologic and mutagenic techniques in pigs as well as by physiology, morphology and histopathology of cysticerci. All results obtained after 15-day treatment showed that the drug damaged the parasites, and after 2 months the inflammatory reaction eliminated all muscle cysticerci, which remained only as microscopic granulomas, while in the brain, that is an immunologic privileged site, dead and destroyed cysticerci, as well as some living or damaged were seen at this time (Flisser *et al.*, 1990a,b). One day treatment was also highly efficient and showed that most muscle and brain parasites in all treated groups exhibited histological images of dying or dead cysticerci at 1 month after treatment in 16/18 pigs (Torres *et al.*, 1992). Oxfendazole is another drug that is reported to be effective against porcine cysticercosis. Veterinary benzimidazole, oxfendazole, is more than 95 percent effective in killing the cysts in the pig when given in a single dose of 30 mg/kg (Garcia *et al.*, 2003). Oxfendazole was used in Peru at a single dose of 10, 20 or 30 mg/kg, viability of cysticerci was measured by evagination, no viable parasites were detected at 2 months after treatment with 30 mg/kg, and at 3 months only minuscule scars remained except in 1/4 pigs that had viable brain cysticerci (Gonzalez *et al.*, 1997, 1998). Sikasunge *et al.* (2008) also reported that after 1

week post treatment with oxfendazole cysts starting dying, at 4 weeks cyst had undergone calcification to various degrees, at 8 weeks all cyst were calcified and by week 26 cyst had disappear from the muscles, heart and tongue. The meat was fit for human consumption at 26 weeks as it had an acceptable appearance (no remnants of cysts). However, the drug was not very infective against cyst in the brain, although some calcification of cysts also occurred in the brain (Sikasunge *et al.*, 2008). Recently, albendazole sulphoxide showed 100 percent effectiveness against muscular cysticercosis, but 8-day treatment was used (Peniche-Cardeña *et al.*, 2002). These data indicate that cestocidal treatment is also an efficient alternative for control of swine cysticercosis, since a 1 day dose is enough to kill the parasites, although disappearance of cysticerci takes place after 2-3 months (Flisser *et al.*, 2003). The only disadvantage is the time it takes for the meat to return to its normal appearance.

2.9.2 Taeniosis

Since a tapeworm carrier is the direct source of infection for him or herself and surrounding people, treatment of taeniosis is extremely important to avoid future NCC cases (Garcia *et al.*, 2006). Praziquantel is the preferred drug for treatment of human taeniosis at an oral dose of 5-10mg/kg b.w. (Garcia *et al.*, 2006). It is recommended that no less than 10mg/kg should be used to avoid exacerbating some cases (Flisser *et al.*, 2003). According to Herrera *et al.* (2000) this drug has a low toxicity and minimal secondary effects. According to Garcia *et al.* (2006) niclosamide is the treatment of choice, in a single dose of 2 g orally. Niclosamide followed by a purgative is a good alternative because tapeworms are usually completely recovered, including the scolex, being crucial in the identification and differentiation between species. In addition, this drug is not absorbed in the intestine avoiding the risk of causing neurological symptoms when the carrier also has NCC (Rodriguez-Hidalgo, 2007). Albendazole has also been used to treat taeniosis although it has a low efficacy (85 percent in 7 studies) (Rodriguez-Hidalgo, 2007). Targeted, instead of massive treatment, should be used, since potential tapeworm carriers can be identified by direct questioning, detection of parasite eggs, antigens or DNA, or by association with late onset epilepsy, and because there is a possibility of generating neurological symptoms in persons with

previously occult NCC (Flisser *et al.*, 2003). Careful diet (avoiding solid foods) for a couple of days and intestinal cleansing with a purgative before and after treatment increases the detection of the parasite scolex, thus ensuring the cure of the patient (except in a minority of cases who have more than a single *T solium* specimen). If the parasite is not cleared from the stool, the patient is retreated (Garcia *et al.*, 2006).

2.9.3 Extraneural cysticercosis in human

Cysticercosis outside the nervous system is a benign disorder and does not merit specific treatment (Garcia *et al.*, 2003). However, ocular cysticercosis may cause blindness in some cases (Garcia *et al.*, 2003). Cestocidal drugs are not used in such cases due to the risk of causing seizures when cysts in the brain undergo degeneration due to the drug. This is due to secondary perilesional inflammatory reaction (Garcia *et al.*, 2003). Surgery can be used in the treatment of orbital cysts (Garcia *et al.*, 2003). Albendazole or praziquantel have also been said to be effective for orbital cysts (Nash *et al.*, 2003).

2.9.4 Neurocysticercosis

Due to the variability in presentation of NCC cases, the choice of treatment should be done on a case by case basis (Garcia *et al.*, 2002). Inherent in any clinical decision is the need for reasonable proof that treatment will be of clinical benefit. This implies that there is adequate knowledge of the natural history of cysticercosis and its various types of presentations. Unfortunately, the natural history of most presentations of cysticercosis is at best incompletely described and therefore prognosis is difficult to judge with certainty (Nash *et al.*, 2003). Factors considered in deciding treatments include the anatomic location of cysts, the stage of evolution of the cysts, number of cysts, the degree of associated inflammation, size, and severity of symptoms (Nash *et al.*, 2006; Garcia *et al.*, 2002). Frequently, the presence of multiple cysts in different anatomic locations and in varying stages of evolution further complicates treatment decisions. Determining effective treatments is complicated by the fact that cysticidal treatment itself initiates a host inflammatory response that may result in the symptoms that one is trying to control (Nash *et al.*, 2006; Garcia *et al.* 2003). The goals of the therapy are to: (1) identify and treat life-threatening complications including mass effect

of cysts and/or associated inflammation, hydrocephalus, stroke and seizures; (2) prevent serious neurological sequelae such as recurrent seizures, mass effect from enlarging cysts, strokes, encephalomalacia secondary to repeated or prolonged intense inflammation, hydrocephalus caused by either ventricular obstruction due to a cyst or inflammatory obstruction of the foramina, ventriculitis, chronic basilar meningitis, and neuropsychiatric manifestations; and (3) minimize the need for long-term medication and associated side effects (Nash *et al.*, 2003). Five treatment modalities can be offered to patients: (1) larvicidal agents to kill the cystic larvae and/or tapeworm; (2) corticosteroids or other immunosuppressive agents to decrease or prevent inflammation; (3) anti-seizure medication to prevent or decrease the severity and number of seizures; (4) surgical-based therapies including emergent measures to decrease the mass effect of cysts with or without accompanying inflammation, remove cysts causing obstruction of the ventricles, shunt placement for hydrocephalus and sometimes for removal and/or decompression of large or critically located cysts prior to use of cysticidal agents; and (5) general supportive measures in impaired individuals or symptomatic treatments.

A panel of experts in taeniasis/cysticercosis discussed the evidence on treatment of NCC for each clinical presentation, and came up with four general recommendations as follows: (i) individualize therapeutic decisions, including whether to use antiparasitic drugs, based on the number, location, and viability of the parasites within the nervous system; (ii) actively manage growing cysticerci either with antiparasitic drugs or surgical excision; (iii) prioritize the management of intracranial hypertension secondary to NCC before considering any other form of therapy; and (iv) manage seizures as done for seizures due to other causes of secondary seizures (remote symptomatic seizures) because they are due to an organic focus that has been present for a long time. Treatments of specific conditions are presented in latter sections. It should be noted that each case presents with different challenge and thus requires a unique treatment plan.

2.9.4.1 Antiparasitic drugs

Antiparasitic treatment may be unnecessary or even contraindicated in some cases (Garcia *et al.*, 2003). Albendazole and praziquantel are the two main cestocidal drugs used for the treatment of NCC (Singhi, 2011; Nash *et al.*, 2003).

Albendazole (usual dose 15 mg/kg/day divided in two doses, for 8 to 15 days oral) and praziquantel (usual dose 50 mg/kg/day divided in three doses for 15 days oral) both have parasiticidal action (Singhi, 2011; Garcia *et al.*, 2006; Garcia *et al.*, 2003; Nash *et al.*, 2003). Use of these drugs should be individualised in terms of the viability of parasites, their number, and their location. In brief, there is apparent benefit in patients with intraparenchymal viable cysts or enhancing lesions, with the exception of those with many lesions in whom the inflammatory reaction secondary to parasite death after therapy may lead to acute intracranial hypertension and so compromise the patient's life. In these cases antiparasitic therapy should be administered with extreme caution (Garcia *et al.*, 2006). Albendazole is preferred over praziquantel as it is less expensive, better tolerated and has better penetration into the subarachnoid space. Also, the bioavailability of albendazole is increased by co-administration of steroids and is not affected by phenytoin or carbamazepine, whereas that of praziquantel decreases with co-administration of steroids, as well as by phenytoin, dilantin and carbamazepine which are often used as first-line anticonvulsants in children with seizures due to NCC (Singhi, 2011; Nash *et al.*, 2003). Albendazole can cause mild hepatic toxicity and gastrointestinal symptoms, rarely reversible hair loss, and marrow suppression. Praziquantel can cause abdominal pain and cramps, diarrhoea, dizziness, drowsiness, fever, headache, sweating, anorexia, malaise, nausea, vomiting, and (less commonly) allergic reactions (Singhi, 2011; Garcia *et al.*, 2006).

2.9.4.2 Corticosteroids

Corticosteroids are commonly used to suppress and/or prevent on-going or treatment-induced inflammation that usually occurs 2- 5 days after initiation of therapy (Nash *et al.*, 2003; Nash *et al.*, 2006; Singhi, 2011). Its usage has not been standardized. Although some wait until symptoms develop, others begin corticosteroids with, before or just after, administration of larvicidal drugs. There is a general consensus that corticosteroids should be used prophylactically when patients have numerous, large or critically located lesions (Nash *et al.*, 2003). Corticosteroids used include methotrexate, dexamethasone and prednisolone (Garcia *et al.*, 2003; Nash *et al.*, 2003; Garcia *et al.*, 2006; Singhi, 2011).

Corticosteroids decrease blood levels of praziquantel and elimination of albendazole sulphoxide is decreased by corticosteroids (Singhi, 2011; Nash *et al.*, 2003). The duration of corticosteroid treatment is determined clinically. The most frequent regimen is dexamethasone at doses of between 4.5 and 12 mg/day. Prednisone at 1 mg/kg/day may replace dexamethasone when long-term steroid therapy is required (Garcia *et al.*, 2006). 10- 16 mg per day of dexamethasone in divided doses and tapering the dose following therapy over 1- 3 months depending on the MRI findings has also been used by Nash *et al.* (2003).

2.9.4.3 Antiseizure medications

Antiseizure medication is indicated in all patients with epilepsy and most with seizures. Although there is no information suggesting that use of antiepileptic drugs (AEDs) in NCC differs from use in other similar types of epilepsy and seizures, this has not been formally studied (Nash *et al.*, 2006). Phenytoin, dilantin and carbamazepine are often used as first-line anticonvulsants in children with seizures due to NCC (Singhi, 2011; Nash *et al.*, 2003). The increase the bioavailability of albendazole, but decrease that of praziquantel.

2.9.4.4 Parenchymal (Brain) viable cysts

These commonly lodge in the parenchyma of the brain. Parenchymal cysts may be viable, degenerating (enhancing lesions), or already dead and calcified. Viable parenchymal cysts may be asymptomatic. However, they are more frequently seen in patients with seizures in endemic areas. Presumably, the viable cysts more frequently degenerate and initiate an injurious inflammatory response. Mass effects as well as focal neurologic symptoms and signs may also be caused by viable parenchymal cysts. Many studies have documented that anthelmintic therapy results in death and resolution of viable cysts, but the clinical benefit of this treatment had been questioned. This is because they may sometimes initiate an intense inflammatory response by the host immune system. Seizures, headaches, and uncommonly death can occur secondary to cysticidal treatments (Nash *et al.*, 2006; Garcia *et al.*, 2002). Patients with moderate infections and viable cysts maybe treated with antiparasitic and with steroids (to minimise inflammation) (Garcia *et al.*, 2003). In patients with massive infections, there is a general hesitation to use larvicidal drugs because of the resulting massive

inflammatory response (Nash *et al.*, 2003; Garcia *et al.*, 2002). Other suggests that single viable non-reactive cysts should not be treated at all.

2.9.4.5 Parenchymal single enhancing lesions (Degenerating cysts)

A single degenerating cyst is the most frequent finding associated with NCC in the Indian subcontinent and is common in other regions as well. Degenerating cysts are usually associated with seizures because these cysts incite a granulomatous inflammatory response by the host. MRI of these lesions shows varying degrees of enhancement and oedema, and histologic examination of these as well as nodular enhancing lesions (a more advanced stage of degeneration) invariably shows acute and or chronic granulomatous inflammation (Nash *et al.*, 2006). For Calcified cysticercosis no antiparasitic treatment is used (Garcia *et al.*, 2003). Corticosteroids anecdotally have been used in these patients (perilesional oedema) to reduce inflammation.

2.9.4.6 Parenchymal chronic calcific cysticercosis

Most cysts eventually calcify. Brain calcifications typical of NCC are detected in from 15 to 20 percent of endemic populations. Calcifications in the absence of viable cysts are frequently the only or predominant type of lesion found in patients who present with seizures and have been implicated as seizure foci in studies. Calcified and resolved cysts cause seizures at a lower rate than viable and degenerating cysts. Previously, calcific NCC was characterized as 'inactive,' implying it was not associated with significant disease or morbidity. Recently, perilesional edema around calcified lesions has been detected around foci of seizure activity or focal neurologic deficits in symptomatic patients. How calcified cysticerci cause seizures or focal neurologic symptoms is not understood. It is suggested that episodic perilesional edema (presence of enhancement around calcified lesions) is common, possibly due to sporadic release of antigen and subsequent host immunologic responses. As for single enhancing cyst, no antiparasitic treatment is used (Garcia *et al.*, 2003) and corticosteroids anecdotally can be used in these patients to reduce inflammation (Nash *et al.*, 2003).

2.9.4.7 Subarachnoid cysts

Extraparenchymal cysticercosis refers primarily to infection of the subarachnoid spaces and ventricles. The clinical problems, approaches, and treatment differ from parenchymal infection, and generally, the prognosis of these patients is worse compared with those with solely parenchymal disease (Nash *et al.*, 2003). Subarachnoid cysts may grow abnormally, presenting as large mass occupying lesions or as racemose cysts, which are aberrantly proliferating membranous forms. Giant cysts respond to anthelmintic drugs. Inflammatory responses to subarachnoid and ventricular cysts frequently cause chronic meningitis and ependymitis that in turn result in hydrocephalus, a common long-term complication, necessitating shunt placement. Lacunar infarcts and entrapment of cranial nerves occur as a result of granulomatous inflammation affecting adjacent arteries or nerves. Whether inflammation in chronic cysticercosis meningitis is the result of continuous degeneration or chronic antigenic release from dead parasitic tissues/ cells driving host inflammatory responses is not known. Inhibition of maturation, growth, and abnormal proliferation forms would be expected to be effective treatments and result in better clinical outcomes (Nash *et al.*, 2006). Subarachnoid cysts, including giant cysts or racemose cysticercosis, and chronic meningitis can be treated by antiparasitic and with steroids (Garcia *et al.*, 2003). Patients with subarachnoid cysts or chronic meningitis may require immunosuppression chronically (Nash *et al.*, 2003). Cysts may or may not regress after anthelmintic treatment and in contrast to parenchymal cysts frequently require long-term and multiple courses of anthelmintic (Nash *et al.*, 2006). Surgery is mostly restricted to shunt placement or emergency decompression (Garcia *et al.*, 2002; Garcia *et al.*, 2006). In the presence of acute obstructive hydrocephalus, surgical therapy can be lifesaving. In many cases, this can be accomplished by placement of a ventricle–peritoneal shunt. Case series suggest that shunt failure rates are high. However, the failure rate is lower in cases treated with antiparasitic drugs. As viable cysts can mechanically obstruct or degenerate and obstruct, surgical removal of cysts when feasible and safe seems a reasonable approach (Garcia *et al.*, 2006; Nash *et al.*, 2006).

2.9.4.8 Ventricular disease

Cysts that lodge in the ventricles may result in hydrocephalus by blocking CSF flow mechanically or as a result of inflammation and fibrosis. Blockage of the fourth ventricle and to a lesser extent third ventricle is relatively frequent and gives rise to the most serious complications. Cysts located in the lateral ventricles can cause unilateral hydrocephalus but may also resolve without sequelae. Hydrocephalus is a common complication that requires placement of intraventricular shunts (Nash *et al.*, 2006; Garcia *et al.*, 2003). Surgery is mostly restricted to shunt placement or removal of cysts located in the ventricles. Anthelmintic treatment of fourth ventricular cysts can be effective. Less invasive flexible neuroendoscopy has been used to remove approachable subarachnoid cysts and cysts lodged in the lateral, third, and fourth ventricles (Nash *et al.*, 2006; Garcia *et al.*, 2006; Garcia *et al.*, 2002).

2.9.4.9 Symptomatic therapy (Antiepileptic therapy)

Treatment of symptoms has an important role in the management of NCC (Garcia *et al.*, 2003). Seizures are the most common clinical manifestation of cysticercosis and require anti-seizure medications. Their use is no different in cysticercosis than in other seizure disorders, but the need for their continued use depends on the clinical situation. For instance, patients with single enhancing lesions tend not to require long-term antiseizure medication (Nash *et al.*, 2003). Seizures generally respond well to first-line antiepileptic drugs, but complete withdrawal of antiepileptic therapy is difficult to achieve (Garcia *et al.*, 2003). Corticosteroids anecdotally have been used in patients with single enhancing lesions, but perilesional edema also has been documented to regress without specific therapy (Nash *et al.*, 2003). Steroids, dexamethasone or prednisone, are helpful in oedema or intracranial hypertension (Garcia *et al.*, 2003). Seizures are often well controlled with a single antiepileptic drug (AED), and the recurrence rate after AED withdrawal is low in cases with single-lesion NCC both in children as well as in adults (Singhi, 2011). Recurrence of seizures after AED withdrawal is correlated with the presence of multiple lesions prior to starting cestocidal therapy, and persistence or calcification of lesions after therapy (Singhi, 2011). The optimal duration of AED therapy has been a matter of debate. Although the

usual practice has been to use AED for 2 years seizure-free interval, shorter durations of AED have been proposed (Singhi, 2011).

2.10 Prevention and control of taeniosis and cysticercosis

Taenia solium infections are a serious public health problem in most developing and some developed countries. Due to its health and economic impact, a lot of work is being done on the prevention and control of infections in humans and pigs. The growing scientific interest in control measures is evident in the number of international conferences on control and prevention of *T. solium* infections. These include the first large international conference on *T. solium* infections in developing countries held in San Miguel de Allende Mexico in 1981, WHO Technical Consultation in Geneva 1983, Symposium on neurocysticercosis in Rotterdam 1998, the 33rd Southeast Asian Ministers of Education Organization (SEAMEO) Seminar in Chiang Mai Thailand in 1990, the 1990 Pan American Health Organization (PAHO) Informal Consultations in Porto Alegre Brazil, 1993 International Task Force for Disease Eradication, and PAHO/WHO consultations held in 1995 (Murrel *et al.*, 2005). Recent advances in research and control measures were discussed at the North Atlantic Treaty Organization (NATO) Seminar on Emergent Zoonoses held in Poznan, Poland in 2000, the International Action Planning Workshop on *T. solium* cysticercosis/taeniosis in Arusha Tanzania in 2002 and at the SEAMEO Seminar in Bangkok Thailand in 2003. In 2002 the problem of *T. solium* taeniosis/cysticercosis was presented at the World Health Assembly for the first time to attract attention of the Member States (Murrel *et al.*, 2005). Other recent programmes are the NCC project in Sub-Saharan Africa (NCC Project) and Integrated Control of Neglected Zoonoses (ICONZ) which are on-going in Zambia and other African countries.

In 1993 the International Task Force for Disease Eradication, concluded that *T. solium* infection was potentially eradicable, even though greater experience in evaluating the efficacy and feasibility of control measures was required. This statement was based on the following reasons: (1) Tapeworm infection in humans is the only source of infection for man and pigs, (2) The reservoir of infection in pigs is restricted by the life span of these animals (rarely exceeding one year), (3) There is no significant reservoir of infection in wildlife, (4) Effective,

inexpensive, easily deployed drugs are available for the treatment of human infections and (5) *T. solium* infections already have disappeared from most of Europe and the feasibility of significant reduction of *T. solium* transmission by population-oriented chemotherapy has already been demonstrated (Murrel *et al.*, 2005). As a result of the International Task Force for Disease Eradication statement on potential eradicability, the importance of chemotherapy of human carriers has been generally accepted, along with chemotherapy in pigs, vaccination of pigs, improvements in sanitation and promoting education. The development of new diagnostic tools was promoted and several community-oriented control projects were undertaken. Operational knowledge and expertise concerning the efficacy of various interventions in endemic areas have since accumulated (Murrel *et al.*, 2005).

Only the tapeworm carriers and the infected pigs are important in terms of transmission (Garcia *et al.*, 2003). Control and prevention of taeniasis in man is based on preventing transmission of the disease from pigs to humans and treatment of tapeworm carriers. A number of ways are used to achieve this. Treatment of tapeworm carriers or at risk population with cestocidal drugs, to eliminate the adult tapeworm (Garcia *et al.*, 2006; WHO 2003). Targeted, instead of massive treatment is recommended since potential tapeworm carriers can be diagnosed to avoid generating neurological symptoms in persons with previously occult NCC (Flisser *et al.*, 2003). Effective meat inspection of pork and condemnation of infected carcasses are also used to prevent infected pork from being ingested by humans. Proper cooking of pork can also kill any viable cysts in the pork (Garcia *et al.*, 2003). Human cysticercosis (neural and extraneural) is also controlled by treating tapeworm carriers (source of infection). Good hygiene like washing hands before and after defecation, drinking boiled water, washing vegetables and fruits and improving sanitation also prevents ingestion of tapeworm eggs directly or indirectly (Sikasunge, 2008; Garcia *et al.*, 2003). Community educational on the prevention and control measures is an important tool in management of infections.

A number of measures are used in the control and prevention of porcine cysticercosis. Proper disposal of human waste (faeces) in pit latrines (toilets) and treated of sewage to prevent pigs from accessing faecal matter contaminated with

tapeworm eggs (Murrel *et al.*, 2005; Sikasunge, 2005). This is especially important in rural areas where confinement of pigs may not be feasible. Where possible, confinement of pigs should be practice to avoid access to human excreta. Feed and water given to pigs should also be hygienically prepared to avoid contamination in case animal attendants are tapeworm carriers. Preventing infection in pigs prevents transmission to humans, since the pig is the only intermediate host. Treatment of pigs with cestocidal drugs like praziquantel and oxfendazole has also been shown to be effective (Gonzalez, 1997; Garcia *et al.*, 2003; Rodriguez-Hidalgo, 2007; Sikasunge *et al.*, 2008). The only set back is that it may take as long as 2-3 months or more before the pork can return to its normal appearance (Sikasunge *et al.*, 2008; Flisser *et al.*, 2003). Another alternative approach to interrupting the transmission cycle of *T. solium* cysticercosis is vaccination of pigs. Effective vaccination can lower prevalence in pigs since it has been shown to reduce the number of viable cysticerci that are capable of developing into tapeworms (Huerta *et al.*, 2000). Immunized pigs contain more damaged cysts than non-immunized ones (Scuitto *et al.*, 1995). Lightowers (2003) reported that a vaccine TSOL18 (one oncosphere antigen) against *T. solium* was shown to give 100% protection against infection in pigs in trials conducted. A vaccine to protect against porcine cysticercosis, based on 3 synthetic peptides (designated S3Pvac) present in all stages of development of *T. solium*, was developed and shown to be effective in mice against *Taenia crassiceps* (Toledo *et al.*, 1999) and in pigs against *T. solium* (Manoutcharian *et al.*, 1996). Its protective capacity (50 percent reduction in prevalence levels and 98 percent reduction of intensity of infection) was demonstrated against naturally-acquired cysticercosis in piglets free-ranging in Tepetzintla, Puebla, Mexico (Huerta *et al.*, 2000). Scuitto *et al.* (2007) also found similar results in a field trial carried out in the rural town of Cuentepec, Mexico, on the protective effect of the vaccine S3Pvac against porcine cysticercosis. A recombinant M13 phage version of the anti-cysticercosis tripeptide vaccine (S3Pvac) has been developed and its efficacy evaluated. Vaccination of pigs with S3Pvac reduced the prevalence of tongue cysticercosis by 70 percent, muscle cysts by 54 percent and total number of cysts by 87 percent (Morale *et al.*, 2008). SP3vac is based on three synthetic peptides of 18 amino acids (aa) (GK-1), 12 aa (KETc1), and 8 aa (KETc12) shared by *T.*

solium and *Taenia crassiceps* (Fragoso *et al.*, 2011). Fragoso *et al.* (2011) examined the immunogenic properties of the *Taenia crassiceps* protective peptide GK-1 administered orally in Mice against *T. crassiceps* and found a significant rate of protection of 64.7 percent was achieved in GK-1-immunized mice, and that rate significantly increased to 91.8 and 96 percent when mice were primed with GK-1 coadministered with BLS as an adjuvant and BLS as a carrier, respectively. This finding offers hope for vaccination in pigs as well.

The control of *T. solium* infections requires a multidiscipline act. Different organisations, professionals and governments need to co-ordinate for the disease to be controlled and eventually eradicated. The community also needs to be involved at all stages and they should be well educated.

CHAPTER THREE

3.0 MATERIALS AND METHODS

3.1 Study area

The study area composed of three districts in Zambia, where cyst collection was done. These were Gwembe in southern province, Mongu in western province and Katete in eastern province (Figure 3.1). Two pigs from Kazungula district in southern province were bought from a livestock market (Chibolya market) in Lusaka district in Lusaka province. Human serum samples were from an existing blood bank at the School of Veterinary medicine. The samples were from Monze district in southern province and Katete district.

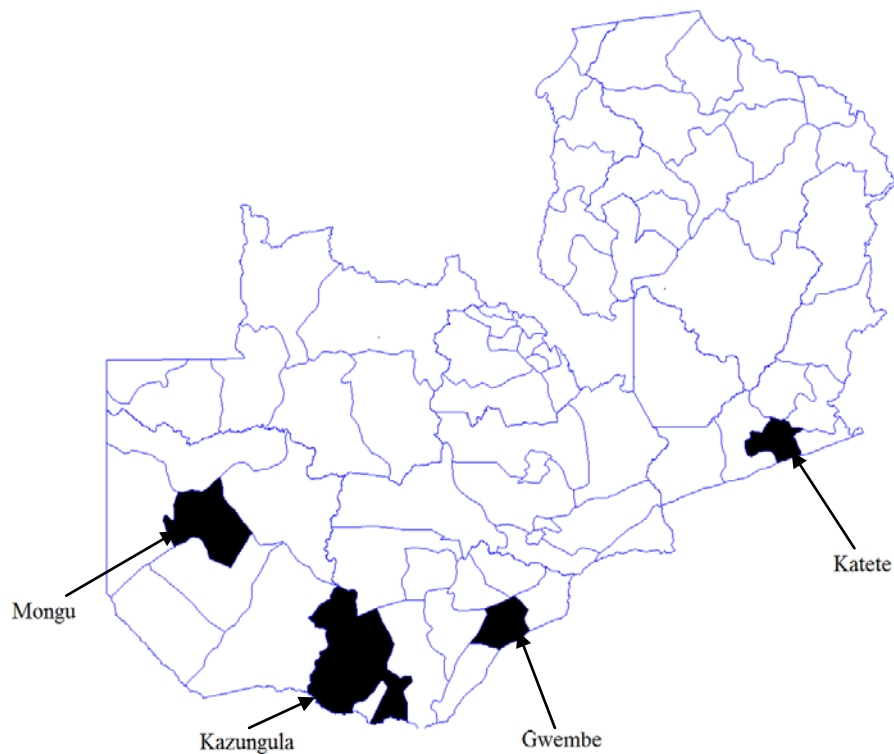


Figure 3.1 Map of Zambia showing the districts where cyst collection was done.

Gwembe and Kazungula districts are located in southern province of Zambia. Gwembe district has a latitude of -16.5 ($16^{\circ} 30' 0$ S) and a longitude of 28 ($28^{\circ} 0' 0$ E). It is situated 271 kilometres south west (232°) of the approximate centre of

Zambia and 124 kilometres south (194°) of the capital Lusaka. Kazungula has a latitude of -17.78 ($17^{\circ} 46' 60$ S) and a longitude of 25.27 ($25^{\circ} 16' 0$ E), and is situated 592 kilometres south west (238°) of the approximate centre of Zambia and 415 kilometres south west (230°) of the capital Lusaka. Both are rural district where farming is mostly done for subsistence and pigs are kept on free range during the day and enclosed in the night for security. Most Pigs in the villages are crossbreeds between Landrace and Large white breeds, with very few local breeds. Farming is mostly by traditional means and livestock is also kept in a traditional way. Livestock in the area includes cattle, goats and pigs. Chickens and guinea fowls are also kept.

Katete district in the eastern province is located at latitude of 14.08 ($14^{\circ} 4' 60$ S) and a longitude of 32 ($32^{\circ} 0' 0$ E). The district is situated 238 kilometres north east (65°) of the approximate centre of Zambia and 426 kilometres east (70°) of the capital Lusaka. It has an average elevation of 1000 meters above the sea. Katete is also a rural district where traditional farming is practiced by most people. Farming activities include crop production (mainly maize) and also livestock rearing. Livestock in the area include cattle, goats and pigs, chickens and guinea fowls. The pigs kept are the local dwarf breed called Nsenga. These are kept under traditional methods which involve free range during the day and confinement in the night (Figure 3.2).



Figure 3.2 Free roaming pigs in a village in Katete district, Zambia, 2010.

The presence of pit latrines in certain villages in Katete district is a good control measure against *Taenia solium* infections as this disrupts the parasites life cycle. The presence of positive pigs in such villages is usually low, as pigs have no access to human excreta. Figure 3.3 shows a pit latrine in one of the villages in Katete district.



Figure 3.3 A pit latrine in one of the households of Undi village of Katete district, Zambia, 2010.

Mongu district has a latitude of -15.17 ($15^{\circ} 10' 0$ S) and a longitude of 23.5 ($23^{\circ} 30' 0$ E). It is the provincial capital of the western province of Zambia. The district is situated 698 kilometres west (268°) from the approximate centre of Zambia and 514 kilometers west (272°) of the capital Lusaka. Mongu has an average elevation of 1058 meters above the sea (traveljournals.net). It is an urban district of Zambia that is surrounded by many villages. The district lies along the Zambezi flood plains, with sandy soil and mostly light vegetation around it. Farming is mostly by traditional means and livestock is also kept in a traditional way. Livestock in the area includes cattle, goats and pigs. Chickens and guinea fowls are also kept. Pigs in the area are mostly cross breeds of Landrace and Large white. Others are the local breeds. Pigs are kept on free range during the day and inclosed in shelters made of sticks or reeds during the night for security (Fig. 3.4).



Figure 3.4 A shelter made of sticks and reeds, where pigs are kept during the night for security.

3.2 Study design

Purposive sampling (non-probability sampling) was used. Pigs were selected based on the presence of cysts on the ventral aspect of the tongue and/or in the eyelids. Districts and Villages were selected based on the information available on the prevalence of porcine cysticercosis in the areas.

Twelve villages were sampled in Gwembe district. These were Chiliga A, Chitembwa, Chiliga B, Chimbali, Hamulelwe, Chimbali B, Kaumuzya, Siabenzu, Madonda, Minziya, Sinafala and Minziyabantu. Twenty six (26) household were sample and a total of 62 pigs were examined from these households. Cysts were collected from 2 pigs. Two Pigs from Kazungula were obtained from traders at Chibolya market in Lusaka. Nine villages were sampled in Katete; these were Songwe, Undi, Matambalika, Mkubamba, Chimwa, Kazungulile, Mutopa, Kaptpa 2 and Chikhitu. A total of 98 pigs were examined for cysticercosis from 45 households using tongue and eye lid inspection and cysts collected from four pigs. Nine of the villages (Namweti, Likuyu, Liyala, Nangole, Latoya, Natubu, Kayenyi, Makono Limulunga and Sefula) in Mongu and 1 market (Mongu harbour) were sampled. Ten households were surveyed in the 9 villages. A total of 206 pigs were examined for *T. solium* cysticercosis in Mongu and cysts collected from one pig.

3.3 Sample collection

3.3.1 Pig samples

Cysts were collected from 14 pigs positive for cysticercosis on tongue examination. These were 2 from Gwembe, 1 from Mongu, 4 from Katete and 2 from Kazungula.

3.3.2 Human sera and control sera

A total of 199 human serum samples were selected from the serum bank, comprising 101 samples from Katete and 98 from Monze. Of the 101 samples from Katete, 98 samples had been tested by an Ag-ELISA (11 positive and 87 negative) and a commercial Immunoblot kit (QualiCode™ Cysticercosis Kit) produced by Immunetics (36 positive and 62 negative). The samples were selected from a blood bank created from other research work done on *T. solium* infections in humans. The samples were selected based on random selection. The cysticercosis status of the sera was not considered. However, only samples with enough volume to run all three or four tests were included in the final sample group. That is, there had to be enough serum to perform Immunoblot and ELISA tests. Control and standard sera were from Department of Infectious Diseases and Tropical Medicine (DMIT) laboratory at Ludwig-Maximilians University in Munich Germany.

3.4 Research Methods

3.4.1 Tongue examination

Tongue examination was used to check for cysts on the ventral aspect of the tongue. The presence of cysts on the tongue indicated that the animal was positive for cysticercosis. Viable cysts appear as thin walled vesicles, fluid-filled and have a visible whitish invagination termed as a scolex. Nonviable cysts appear as calcified cysts with a caseous appearance. Only pigs with viable cysts were considered positive and sampled. In order to examine the tongue, the pig was placed in left lateral recumbence for a right handed examiner, and vice versa for a left handed examiner. The pig was restrained by three people. One held the hind limbs, the second one the fore limbs and the third person restrained the head. The

examiner then used a wooden stick to open the mouth of the pig. The stick was also used to keep the mouth of the pig open and prevent the examiner from being bitten by the animal during examination. The examiner pushed the stick gently between the jaws of the pig to avoid injury to the animal. This was in the up-down direction. When the mouth was open, the examiner used a mutton cloth (cotton cloth) to grip the tongue and pulled it out towards the dorsal aspect of the pig's head in order to expose the ventral aspect of the tongue as much as possible.

3.4.2 Cyst collection

Pigs that were found positive for cysticercosis on tongue examination (presence of cysts on the ventral aspect of the tongue) with or without cysts in the inner eyelid membranes were purchased and slaughtered. They were then dissected and cysts collected from skeletal muscles. The samples were divided into whole cysts, cyst fluid and scolices and membranes (cysts without fluid). Cyst fluid was collected as described by Sikasunge *et al.* (2005). Briefly, cysts were rinsed in phosphate buffered solution (PBS) in a petri dish and dried using No. 4 Watmans filter paper (Wathman, GE Healthcare, Great Britain). Whole cysts were ruptured using a scalpel blade to release the fluid. The fluid was aspirated using an 18G needle and a 20 ml syringe and then placed into tubes. The whole cysts and the damaged cysts (scolices and membranes) were placed into different tubes after drying with No.4 Watmans filter paper. The tubes were stored in a cool box containing ice packs during transportation to the laboratory at the University of Zambia, School of Veterinary Medicine for storage at -20°C. The cysts were later transported to Department of Infectious Diseases and Tropical Medicine (DMIT) laboratory in Germany where they were stored at -80°C until use.

3.5 Immunological methods

Antigen preparation was done at the Department of Infectious Diseases and Tropical Medicine (DMIT) laboratory at Ludwig-Maximilians University in Munich, Germany. The *T. solium* cysts were tested using PCR and microscopy of scolices to confirm its identity by the laboratory at DMIT.

3.5.1 Preparation of crude *T. solium* cyst antigen

The antigen preparation was performed by a modification of the method described by Gottstein *et al.* (1986). Briefly, 4 ml sediment of the thawed cysts, including vesicular fluid, walls and scolices were added to 62 ml of PBS containing 0.01 percent of NaN₃ (0.1g Sodium azide and 1L PBS), then mixed with a blender after adding 6 Proteinase inhibitor tablets (cOmplete ULTRA tablets, Roche) for 5 minutes. Subsequently the material was frozen and thawed 3 times in liquid Nitrogen (N₂) then ultrasonicated for 3 min (100 Volt) until complete homogenization. The solution was then examined microscopically for any large fragments. This was followed by centrifugation at 13,000rpm/4⁰C for 45 min. The supernatant was collected and stored at -80°C. Will then be adjusted to standardized protein concentrations and used as antigen in the antibody ELISA. Two batches of crude antigens were prepared J/XIII and J/XI.

3.5.2 Determination of antigen protein concentration

A commercial total Protein kit (f.e Sigma # TP0200) was used to determine the concentration of the different antigens prepared. A Micro-Lowry, Onishi & Barr modification was used to determine the protein concentration of the antigen preparations. 0.85 percent Sodium Chloride (NaCl) was prepared by dissolving 0.85g NaCl in 100ml of Double distilled water. A stock solution was prepared by mixing 990 µl 0.85 percent NaCl and 10µl of the Protein standard (Protein standard provided in the total Protein kit). Six dilutions of the stock solution and 0.85 percent NaCl were prepared as shown in table 3.1.

Table 3.1 Different dilutions of the standard and their concentrations.

| | Blank | 1 | 2 | 3 | 4 | 5 |
|-------------------------------|-------|-----|-----|-----|-----|------|
| Standard (µl) | 0 | 10 | 25 | 50 | 75 | 100 |
| 0.85% NaCl (µl) | 100 | 90 | 75 | 50 | 25 | 0 |
| Protein Concentration (µg/ml) | 0 | 100 | 250 | 500 | 750 | 1000 |

The sample (antigen) was diluted with 0.85 percent NaCl in 3 dilutions as shown in table 3.2.

Table 3.2 Dilutions of the sample.

| Sample | 50 μ l | 10 μ l | 5 μ l |
|------------|------------|------------|------------|
| 0.85% NaCl | 0 | 40 μ l | 45 μ l |

50 μ l from each dilution (sample dilutions and standard dilutions) was taken and placed in separate Eppendorf tubes. Five hundred and fifty microliter (550 μ l) of Biuret reagent was added to each tube, vortexed, and then incubated for 10 min/rtp (room temperature and pressure). Twenty-five microliter (25 μ l) of Folin was added to each tube followed by incubation at room temperature for 30 minutes. Thereafter, 200 μ l from each Eppendorf tube was added to a well on a Microliter plate (ELISA plate) which was read at 620nm using an ELISA reader. The concentration of the antigen was obtained from the graph.

3.5.3 Indirect/Antibody Enzyme Linked Immunosorbent Assay titration

3.5.3.1 Determination of antigen coating concentration for ELISA

The Ab-ELISA was conducted as described by Gosttein *et al.* (1986) with minor modifications. The optimal dilution of the antigen was determined by serial titrations (dilutions) of the Zambian antigen (Batch XI 440 μ g/ml) in coating buffer (Sodium carbonate 3.1g, Sodium hydrogen carbonate 5.9g, Sodium nitrate 0.1g and 1L double distilled water). The dilutions used were 0.5 μ g/ml, 1.0 μ g/ml and 1.5 μ g/ml. The dilutions were compared to 1.0 μ g/ml coating concentration of the Mexican antigen used at DMIT laboratory. The ELISA plate (F-plate) was coated with Mexican antigen and the 3 dilutions of the Zambian antigen. Each antigen solution was placed in two rows of the plate. The plate was incubated at 37°C for 3 hrs (1–3hrs is recommended) then left at 4°C overnight. The plat was washed once with PBS-T then 200 μ l/well of incubation buffer (5g BSA IN 100ml PBS) added and incubated at 37°C for 1hr. Serum samples (human sera), controls (Negative, medium and low) and Standard 1 (Factor 1) were diluted 1: 160 in PBS-T and standards Factor 100, 1: 100, Factor 33, 1: 300, Factor 10, 1 : 1000.

After washing once 50ul of each (diluted sera and standards) plus 50ul of incubation buffer/wall was added according to the pipetting plan, and then incubated for 1hr at 37°C. Microplate was washed three times with PBS-T then added 100ul/well of diluted conjugate (rabbit IgG antihuman IgG, heavy chain specific, labelled with peroxidase prepared as described by Wilson & Nakane 1978) 1: 2000 with incubation buffer and incubated for 1 hr at 37°C. After washing three times with PBS-T, the assay was developed by adding the enzymatic substrate consisting of H₂O₂ and o-phenylenediamine (OPD) in citrate phosphate buffer pH 5 for 30 min in the dark. The reaction was stopped by adding 25 ml/well of 0.5mol/l (1 N) H₂SO₄. The absorbance was determined at 492 nm using an ELISA reader (TEACAN sunrise). Magellan software was used to calculate the antibody concentrations (AC) and measure other parameters. The cut-off points used were determined by DMIT laboratory. The 1.0µg/ml concentration of the Zambian antigen was selected as it gave similar results to the Mexican antigen. This was repeated to check for consistency.

3.5.3.2 Titration of standard sera for ELISA

The standard serum was chosen from sample sera (human) that gave consistently high antibody titres (above 50 AC) on ELISA and were positive for cysticercosis on Immunoblot. The selected sample serum was diluted in several dilutions as describe above for standards (Factors 100, 33 and 10). The dilutions of selected serum were compared with the standard serum used at DMIT laboratory using the ELISA method as describe above. The criteria for choosing a certain dilution/concentration of the selected serum was that Factors 100 had to have an absorbance range of 1.0–1.3 OD, Factor 33=0.5–0.8 OD, and factor 10=0.2–0.5 OD. The dilution that had reading most close to the standard used at DMIT was chosen for the ELISA test. This was repeated to check for consistency in the results before finally selecting the final dilution. The selection of standard sera also involved testing the sera with antigens of *Filarial* and *Echinococcus* species to check for cross reactions.

3.5.3.3 Sample analysis

The Ab-ELISA was conducted by as described by Gosttein *et al.* (1986) with minor modifications. The ELISA plate (F-plate) was coated with 100ul/well of

1.0µg/ml of Zambian antigen. Then incubated at 37°C for 3 hrs (1–3hrs is recommended) and left at 4°C overnight. The plate was then washed once with PBS-T and dried on paper towels, then 200µl/well of incubation buffer added and incubated at 37°C for 1hr. Serum samples, controls (Negative, medium and low) and Standard 1 (Factor 1) were diluted 1: 160 in PBS-T and standards Factor 100 1: 200, Factor 33 1: 600, Factor 10 1: 2000. After washing once 50ul of each plus 50µl of incubation buffer/wall was added according to the pipetting plan, and then incubated for 1hr at 37°C. The plate was then washed three times with PBS-T then added 100µl/well of diluted (1: 2000) conjugate (rabbit IgG antihuman IgG, heavy chain specific, labelled with peroxidase prepared as described by Wilson and Nakane (1978) with incubation buffer and incubated for 1hr at 37°C. After washing three times with PBS-T, 100 µl/well of enzymatic substrate consisting of H₂O₂ and OPD in citrate phosphate buffer (pH 5) was added, and then incubated for 30 min in the dark at room temperature. The reaction was stopped by adding 100 µl/well of 0.5mol/l (1 N) H₂SO₄. The absorbance was read at 492 nm using an ELISA reader (TEACAN sunrise). Magellan software was used to perform the calculations.

3.5.4 Western blot/Immunoblot

3.5.4.1 Electrophoresis and electrophoretic transfer

Electrophoresis and electrophoretic transfer were performed using a modification of the method by Gosttein *et al.* (1986). All SDS-PAGE chemicals and protein markers were obtained from Bio-Rad Laboratories. Three hundred and fifty microliter (350 µl) of Crude *T. solium* antigen was mixed with 350 µl of the Tricine-loading buffer (20 µl β-Mercapto-Ethanol, 0.33 ml M Tris/HCl pH 8.45, 4 ml 50 percent (w/v) Glycerine, 1 ml 10 percent (w/v) SDS (Dodecyl Sulphate sodium), 0.4 ml Coomassie-Brilliant-Blue G250 and 3.77 ml double distilled water) then heated in boiling water in 2 intervals of 2¹/₂min. A 16.5 percent Resolving gel (5.2 g Glycerin, 6 ml double distilled water, 13.4 ml 3 M Tris/HCl pH 8.45 and 16.4 ml 40 percent Acrylamide/Bisacrylamide, 200 µl 10 percent Ammoniumpersulphate solution (PER) and 20 µl TEMED) and a 4 percent Stocking gel (11.4 ml double distilled water, 6.6 ml 3 M Tris/HCl pH 8.45, 2 ml 40 percent Acrylamide/Bisacrylamide, 100 µl 10 percent Ammoniumpersulphate

solution (PER), 20 µl TEMED) were used for electrophoresis. Six microliter (6 µl) of protein standard (Precision plus) and 750 µl Crude antigen(Batch J/XIII)/Tricine-loading buffer were separated by SDS-PAGE on a 4-16.4 percent , gradient under reducing conditions 40 v, 200 mA, 10 W for 1:30hrs then 100 V, 200 mA, 10 W for 4hrs. After electrophoresis, gels were briefly soaked in transfer buffer (6g Tris, 29g glycine, 400ml methanol, and 1600ml double distilled water). The polypeptides were then electrophoretically blotted onto to a sheet of nitrocellulose transfer membrane (Immobilon, Millipore 0.2) using Bio-Rad transfer cell (Trans-BIOT ® SD BIO-RAD) and power supply (EPS601 Amersham Pharmacia biotech) at 25 V, 150 mA, 30 W for 1:30hrs. Amidoblack solution was used to visualise protein bands on 2 stripes (8 mm thick). The remaining transfer membranes were blocked with BSA/PBS/Tween solution at room temperature for 30min then stored at room temperature on a clean glass plate.

3.5.4.2 Western blot procedure/protocol

The nitrocellulose transfer membrane was cut into thin strips of 3 mm wide using a scalpel blade. They were then placed in wells in a mini incubation tray. Two milliliters (2 ml) of BSA/PBS/Tween/ per well was added and then incubated for 30 minutes at room temperature on a shaker (magnetic stirrer). This was then replaced with 2 ml of BSA/PBS/Tween per well. Six microliter (6 µl) of positive control and 6 µl of negative control sera were added to the positive and negative control stripes respectively (still immersed in 2 ml of BSA/PBS/Tween), then incubated for 70min at room temperature and pressure (rtp) with shaking. Afterwards the stripes were washed twice with 2 ml of PBS/Tween per well. They were then incubated in 2 ml of PBS/Tween per well for 5 minutes, then for 10 minutes in the same solution. Two milliliters (2 ml) of BSA/PBS/Tween per well was added plus 3.5 µl IgG conjugate per well then incubated for 75 minutes/rtp on a shaker. Then the washing step was repeated. After that, 2 ml of substrate solution (23.25 ml double distilled water, 1.25 ml 1M Tris/HCl, 25 µl 3 percent H₂O₂ and 1 tablet Diaminobenzidine) per well was added for 3–10 min/rtp. As soon as distinct bands appeared, stripes were transferred into double distilled water to stop the reaction (colour change). The stripes were then dried at room temperature and stored at -20°C until use. Some stripes were tested with

Echinococcus antibody positive serum for cross reactions. African sera; negative and positive for *T. solium* antibodies were also used to test the stripes.

3.5.5 Commercial Immunoblot (QualiCode™ Cysticercosis Kit)

The QualiCode™ Cysticercosis Kit is an *in vitro* qualitative assay for the detection of IgG antibodies in serum reactive with *Taenia solium* antigens present on a membrane. It is a qualitative membrane-based immunoassay manufactured from *T. solium* proteins. The *T. solium* proteins are fractionated according to molecular weight by electrophoresis on a polyacrylamide slab gel (PAGE) in the presence of sodium dodecyl sulfate (SDS). The separated *T. solium* proteins are then transferred via electrophoretic blotting from the gel to a nitrocellulose membrane. The Western Blot assay has been shown to provide a reliable method for evaluation of sera from patients with clinically diagnosed active cysticercosis (Wilson 1991). Field studies support a sensitivity of 98% and specificity of 100% for this assay (Diaz *et al.*, 1992; Tsang *et al.*, 1989). The kit uses six glycoprotein antigens of molecular mass 50, 42-39, 24, 21, 18 and 14kDa. The presence of any one of the six glycoproteins is diagnostic (Immunitics, Inc. 2006).

3.6 Data analysis

Due to the absence of a gold standard for immunological (serological) diagnosis for *T. solium* infections, the Crude and commercial Immunoblot (QualiCode™ Cysticercosis Kit) were used as standards to which other tests were compared to. Chi-square, Fisher's test and kappa tests were used to test for level of significant difference and agreement (independence) among the tests in detecting antibodies against *T. solium* in human sera. All values of $p < 0.05$ were considered to be significant. Kappa Agreement was interpreted as described by Viera and Garrett (2005) as shown below:

| Values | Levels of agreement |
|------------|----------------------------|
| < 0 | less than chance agreement |
| 0.01–0.20 | slight agreement |
| 0.21– 0.40 | fair agreement |
| 0.41–0.60 | moderate agreement |
| 0.61–0.80 | substantial agreement |
| 0.81–0.99 | almost perfect agreement |

CHAPTER FOUR

4.0 RESULTS

4.1 Tongue examination and cysts collected

Of the 367 pigs, 14 were positive on tongue examination representing 3.8 percent. Table 4.1 shows the number of pigs examined and sampled (cysts collected) in the different districts. Figure 4.1 shows cysts on the tongue, while fig 4.2 shows cysts covering the entire muscle tissue taken from an infected pig.

Table 4.1 Number of pigs examined and sampled in each district, Zambia, 2009-2012

| District | Number Examined | Positive | Sampled for cysts |
|-----------|-----------------|----------|-------------------|
| Gwembe | 61 | 7 | 2 |
| Mongu | 206 | 1 | 1 |
| Katete | 98 | 4 | 4 |
| Kazungula | 2 | 2 | 2 |
| Total | 367 | 14 | 9 |

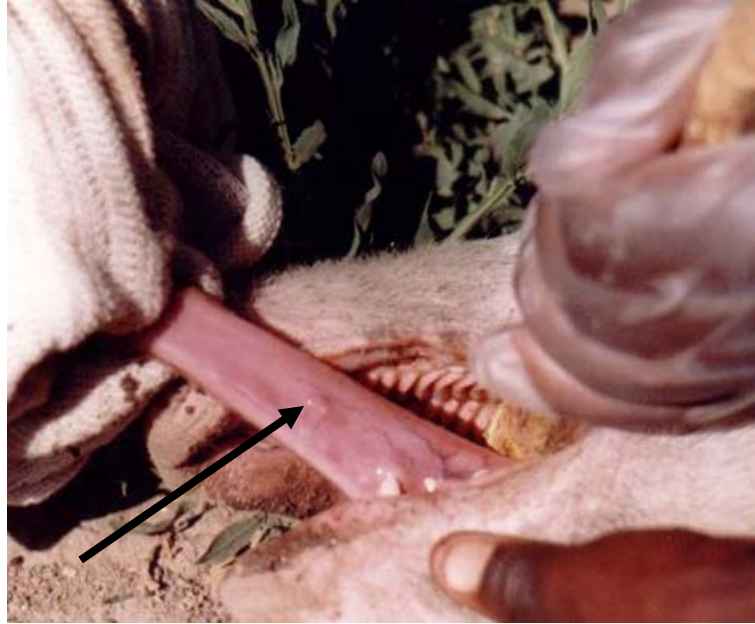

Figure 4.1 A pig positive for cysticercosis on tongue examination. The arrow shows the presence of viable cyst on the ventral aspect of the tongue.

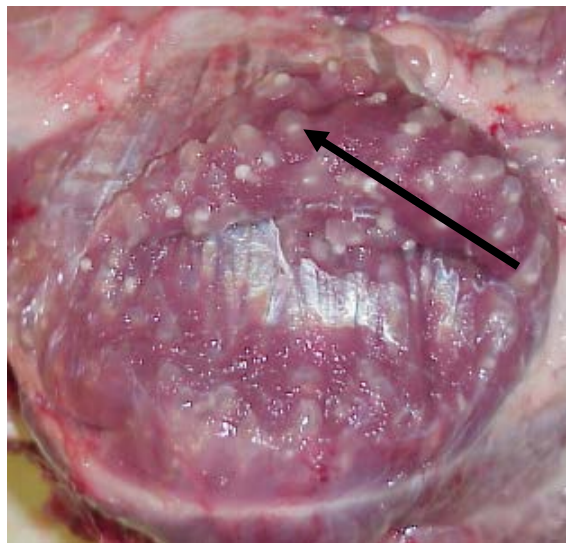


Figure 4.2 *Taenia solium* cysts covering the entire muscles taken from an infected pig. Note that the cysts are viable and appear as vesicles filled by clear fluid with a whitish invaginated scolex (whitish spot) inside.

4.2 Antigen concentrations

Using the Micro-Lowry, Onishi and Barr modification the concentrations of the antigens were determined. The concentrations of the two crude antigens prepared

were 882 µg/ml (Batch J/XIII0 and 440 µg/ml (Batch J/XI). For coating the Immunoblot stripes, 50 percent (1:2) dilution of the antigen solution with Tricine-loading buffer (750 µl antigen solution and 750 µl Tricine-loading buffer) was found to provide adequate antigen concentration on the Immunoblot stripes.

4.3 Indirect/Antibody Enzyme Linked Immunosorbent Assay titration

The ELISA coating concentrations were determined to be 2.3 µl/ml or 1 µg/ml of crude antigen in coating buffer using Batch J/XI. A 1:200 dilution of the standard serum gave the best standard curve. Of the 199 human serum samples tested, 7 percent were positive. Positive samples had an AC (antigen concentration) reading greater than 14. Negative sera had AC readings less than 10. Samples in the borderline region (10-14 AC) were classified as negative. The antigen concentrations of the test sera ranged from 0 to 67.96 AC. The average concentration was 7.55 AC.

4.4 Diagnostic bands for western blot

Several bands on the Immunoblot stripes were seen to react with different serum samples. Reactions occurred with antigenic components from 8-10kDa (Kilo Dalton) to 250kDa. The reactions were mostly between 25-150kDa. The antigen component (band) of approximately 8-10kDa was found to be diagnostic for *T. solium* infection in human using crude antigen (Figure 4.3). This band was consistently positive when tested with *T. solium* positive serum and negative with negative *T. solium* serum. These appeared as two bands when tested with European and one with African sera positive for *T. solium* antibodies. When tested using serum positive for *Echinococcus granulosus*, no cross reactions were noted with the 8-10 kDa protein(s) of the antigen. Cross reaction with *E. granulosus* was seen mostly with *T. solium* antigen proteins of molecular weight of 25 kDa and above as seen in figure 4.4.




Figure 4.3 Showing colour bands and the molecular mass of Precision Plus Protein Standards (stripes **A**), Amidoblack stained antigen bands (bluish stripes **B**) and a positive (+) and negative (-) stripes for *T. solium* in the middle. Note the level of the diagnostic band (brownish) on the positive stripe just below the 10kDa band of the protein standard (indicated by the Arrow).




Figure 4.4 Amidoblack staine showing bluish lines (stripe **AB**), reaction with *T. solium* positive sera (stripe **T.s**), *E. granulosus* positive sera (stripe **E.g**) and standard stripes (stripe **S**). Note that *E. granulosus* sera, only reacts with antigenic components greater than 25kDa (Arrow).

4.5 Crude Western blot

Of the 199 human sera tested with crude cyst antigen Immunoblot, 25 (12.6 percent) were positive for cysticercosis. Reaction of antigenic components greater than 25kDa (25–150kDa) occurred with all sera (negative and positive sera). Some serum samples showed reactions of antibodies and antigenic components between 10 and 25kDa (Figure 4.5). Figure 4.5 also shows the diagnostic band 8–10kDa which was detected by the positive control sera and some of the test sera.

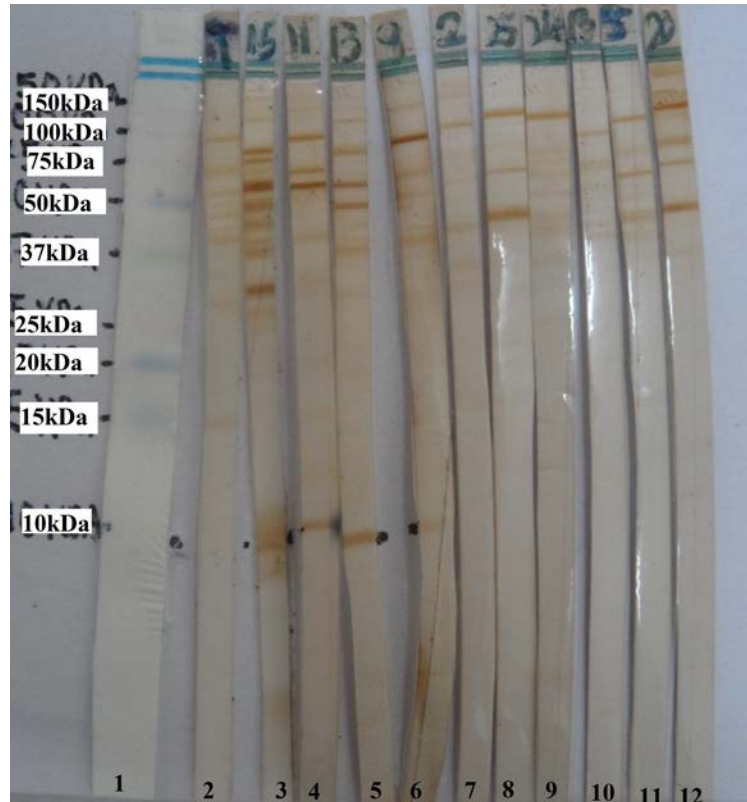

Figure 4.5 Illustrative Western blots of test sera, controls and standard protein. Protein standard (1) showing molecular mass of different protein bands, Negative control (2), positive control (3) with diagnostic band of 8-10kDa (black dots), positive test sera (4-6) and negative tests sera (7-12). Note presence of bands on all sera (test and controls) above 25kDa.

4.6 Comparisons of diagnostic tests

Due to the absence of a gold standard for immunological diagnosis of *T. solium* infections, the commercial Immunoblots (QualiCode™ Cysticercosis Kit) was used as the standard by which other tests were compared to. Chi-square, Fishers

test and kappa test were used to test for level of agreement (or independence) among the tests in detecting antibodies against *T. solium* in human sera.

4.6.1 Commercial immunoblot and Ab-ELISA

Compared to the commercial Immunoblot, the Ab-ELISA had a sensitivity of 16.67 percent and specificity of 91.94 percent. McNemar test had Chi-square value of 17.15 and two tailed $p < 0.05$. There was a significant difference between the two tests, as the Commercial Immunoblot test performed better than the Ab-ELISA. Kappa was 0.10, proportional agreement 0.64, Bias index -0.25, Prevalence index -0.52. The level of agreement between the two tests was slightly significant. Table 4.2 shows the number of patients positive and negative using both tests.

Table 4.2 Comparison of commercial immunoblot with Ab-ELISA (n=98)

| | | Commercial Immunoblot | | TOTAL |
|----------|----------|-----------------------|----------|-------|
| | | Positive | Negative | TOTAL |
| Ab-ELISA | Positive | 6 | 5 | 11 |
| | Negative | 30 | 57 | 87 |
| TOTAL | | 36 | 62 | 98 |

4.6.2 Commercial immunoblot and crude antigen immunoblot

The crude Immunoblot was compared to the commercial Immunoblot. The estimated sensitivity of crude Immunoblot was found to be 19.44 percent. The specificity was 85.48 percent. Table 4.3 shows the number of patients positive and negative using both tests. Using the McNemar test (chi-square two tailed) there was a significant difference between the two tests ($p < 0.05$). The commercial Blot had a superior performance than the crude Immunoblot. Kappa was 0.06, proportional agreement 0.61, Bias index -0.2, and Prevalence index -0.46. There was slight agreement between the two tests.

Table 4.3 Comparison of commercial immunoblot with crude immunoblot (n=98)

| | | Commercial Immunoblot kit | | TOTAL |
|------------------|----------|---------------------------|----------|-------|
| | | Positive | Negative | TOTAL |
| Crude Immunoblot | Positive | 7 | 9 | 16 |
| | Negative | 29 | 53 | 82 |
| TOTAL | | 36 | 62 | 98 |

4.6.3 Crude antigen immunoblot and Ab-ELISA

When compared, the two tests showed significant difference. McNemar test had Chi-square value of 4.08 and two tailed $p < 0.05$. The crude antigen Immunoblot detected more positives. Kappa was 0.24, proportional agreement 0.86, Bias index -0.05, Prevalence index -0.80. The level of agreement between the two tests was fairly significant. Table 4.4 shows the number of patients positive and negative using both tests.

Table 4.4 Comparison of crude antigen immunoblot with Ab-ELISA (n=199)

| | | Crude antigen Immunoblot | | |
|----------|----------|--------------------------|----------|-------|
| | | Positive | Negative | TOTAL |
| Ab-ELISA | Positive | 6 | 8 | 14 |
| | Negative | 19 | 166 | 185 |
| TOTAL | | 25 | 174 | 199 |

4.6.4 Comparison of the three diagnostic tests (crude antigen immunoblot, Ab-ELISA and commercial immunoblot)

Table 4.5 compares only three tests (crude antigen Immunoblot, Ab-ELISA and commercial Immunoblot). 98 sera were tested using all three tests. Three (3 percent) were positive and 51 (52 percent) were negative on all three tests. The rest of the results are presented in the table.

Table 4.5 Correlation of the overall results obtained by three tests (n=98)

| No. tested (%) | Crude antigen Immunoblot | Ab-ELISA | Commercial Immunoblot |
|-----------------|--------------------------|----------|-----------------------|
| 3(3) | + | + | + |
| 3(3) | + | + | - |
| 4(4) | + | - | + |
| 6(6) | + | - | - |
| 51(52) | - | - | - |
| 26(27) | - | - | + |
| 2(2) | - | + | - |
| 3(3) | - | + | + |
| 98 (100) | | | |

CHAPTER FIVE

5.0 DISCUSSION

The Ab-ELISA test was prepared using a modification of the method describe by Gosttein et al (1986) at Department of Infectious Diseases and Tropical Medicine (DMIT) laboratory at Ludwig-Maximillians University in Munich, Germany. This is the same procedure used for the routine Ab-ELISA for detecting antibodies against *T. solium* cysticercosis at DMIT. The ELISA used 1.0µg/ml of crude antigen to coat the plates. This dilution gave similar results as the routine test done at DMIT. Dilution of 1: 200 of the factor 100 of the standard serum was used, as it gave the good standard curve. Since the Ab-ELISA used crude antigen which has been reported to cross react with other infections (Gosttein et al., 1986; Shiguekawa et al. 2000), a cut-off point is important to reduce the number of false positives.

We adapted a Western blot (Immunoblot) technique using crude cyst antigen. This was done through electrophoresis and electrophoretic transfer of the antigen onto nitrocellulose blotting paper as described by Gosttein *et al.* (1986). The concentration of the antigen (0.88mg/ml) used in Western blot, was similar to those used by Shiguekawa *et al.* (2000) 1mg/ml and 0.9mg/ml. In our study a 1:2 dilution of the antigens before electrophoresis provided adequate coating on the nitrocellulose paper as evidenced by a strong staining reaction with Amidoblack stain. The principle is such that the stain attaches to protein coated on the nitrocellulose paper. The intensity of the stain shows how well the nitrocellulose paper has been coated by the antigen solution during electrophoresis. In our study, the stained bands ranged from 8kDa to 250 kDa. These findings are in agreement with those of Gosttein *et al.* (1986). Several antigenic bands reacted with test sera used within the bands of between 25 and 150kDa. These findings were similar to those found by Shiguekawa *et al.* (2000) who found twenty one (21) proteins (8, 12–14, 18, 24, 26–28, 32–36, 39–42, 47–52, 56, 64–68, 72, 75, 80, 85, 88, 92, 98, 105, 110, 115–120 and 126–155 kDa) that were recognized by IgG antimetacestode of *T. solium* antibodies in 80 sera by western blot with a range between 8-155 kDa. The band 8-10kDa was consistently positive when tested with sera positive for cysticercosis and negative with negative sera, and was thus

found to be diagnostic for cysticercosis. Interestingly, the band did not react with *Echinococcus granulosus* positive sera, which is said to be the main cause of cross reaction with *T. solium* antigenic components (Gosttein *et al.*, 1986). When tested with sera positive for *Echinococcus granulosus*, reactions occurred mostly with bands greater than 25kDa. Gosttein *et al.* (1986) also found that 8 kDa was positive for cysticercosis and equally showed no reaction to cystic or alveolar echinococcosis. Though these authors also reported that 26kDa was also specific for cysticercosis on WB, this was not the case in the current study. Shiguekawa *et al.* (2000) reported that recognition of two out of the six immunodominant markers using saline extract without 2-ME (24, 39–42, 47–52, 56, 64–68 and 126–155 kDa) was diagnostic for NCC. However in our study these antigenic bands were not significant in the diagnosis of cysticercosis. Different authors have also synthesised 10, 7-10 and 14 kDa recombinant polypeptides that can be used in immunoblot and ELISA (Sako *et al.*, 2000; Chung *et al.*, 1999). While the specificity of these antigens is reported to be high, the sensitivity is generally lower than with the native antigens. Yet again several researchers have reported that the proteins to which specific antibodies were encountered more often in sera of the echinococcosis patients were: 16 and 18 kDa (Ito *et al.*, 1993); 8, 12, 17 and 32 kDa (García *et al.*, 1998); 8, 29 and 34 kDa (Poretti *et al.*, 1999). Though the 8 kDa band was reported to cross react by other researchers, in our work it showed no cross reactions to other parasitic infections and it is because of this that it was our diagnostic band.

Using the crude antigen Immunoblot technique, the reaction of antigenic components of 25–150kDa occurred with all sera (including negative and positive control sera). Some serum samples showed reactions of antibodies and antigenic components between 10 and 25kDa. These reactions could be due to cross-reactions with other parasites that the subjects in the study may have been exposed to in their life. This is due to the exposure to parasites (mostly worms) by most people in rural areas of Zambia due to poor hygiene. Gosttein *et al.* (1986) observed that most cross-reactions to *T. solium* antigens occurred most with sera positive for related *Echinococcus* species (*E. granulosus* and *E. multilocularis*). This observation was mainly with components higher than 20kDa. These authors also noted lesser cross reactions with sera from patients with filariasis,

toxocariasis, strongyloidiasis and schistosomiasis. Shiguekawa *et al.* (2000) also reported cross reaction of *T. solium* antigenic components greater than 45kDa with other helminthic infections in patient sera. The diagnostic band 8-10kDa which was only detected by the positive control sera and some of the test sera in other study was also reported not to react with other helminthic infections by Gostein *et al.* (1986).

On The Ab-ELISA, 17 borderline samples were categorised as negative to reduce the incidence of false positives. This is because unpurified antigens have previously shown cross reactivity with non-specific infections such as *T. hydatigena*, *E. granulosus*, *Hymenolepis nana*, and *Ascaris suum* (Tefera, 2008). Borderline samples are usually retaken from patients after some time to check on whether the antibody titres are increasing or reducing. Thus the antibody titres may have been declining in such patients probably due to parasite death.

The commercial Immunoblot (QualiCode™ Cysticercosis Kit) was used as the standard with which other tests were compared to. The Western Blot assay (U.S. Patent No. 5,354,660) developed by Tsang *et al.* (1989) at the U.S. Centers for Disease Control has been shown to provide a reliable method for evaluation of sera from patients with clinically diagnosed active cysticercosis (Wilson and Schantz, 1991). Field studies (Diaz *et al.*, 1992; Tsang *et al.*, 1989) support a sensitivity of 98 percent and specificity of 100 percent for this assay. The manufacturer (Immunetics) of the QualiCode™ Cysticercosis Kit states that the kit has the sensitivity of 98 percent and specificity of 100 percent in field studies as it is produced using the same protocol (Immunetics, Inc. 2006). The kit uses six glycoprotein antigens of molecular mass 50, 42-39, 24, 21, 18 and 14kDa. The presence of any one of the six glycoproteins is diagnostic (Immunetics, Inc. 2006). Another EITB that utilizes a 10 kDa native antigen, a subunit component of a 150 kDa complex, purified from fluid of *T. solium* cyst showed a sensitivity of 85 percent (n = 247) and specificity of 90 percent in detecting cysticercosis in human serum (Yang *et al.*, 1998). Synthetic proteins of 8 kDa from LLGP's have also been used in EITB format. The assay demonstrated sensitivity of 82-94 percent in sera (n = 107) from patients with two or more viable cysts and specificity of 76-100 percent (Scheel *et al.*, 2005). Our crude antigen Immunoblot uses the 8-

10kDa which was diagnostic in our research and in the work done by Gosttein *et al.* (1986).

When the crude antigen and commercial blots (using commercial blot as standard) were compared, there was a statistically significant difference as the commercial blot performed better (crude antigen blot Se 19.44 percent and Sp 85.48 percent). The low sensitivity of the crude antigen Immunoblot could be attributed to the fact that it only uses one band (8-10kDa) for diagnosis while the commercial Immunoblot uses any of the six bands. This makes the commercial blot to be more sensitive. Carpio, (2002) found that in patients with a single brain cyst, the sensitivity of the commercial blot (EITB) was only 25 percent. Wilson *et al.* (1991) also found a sensitivity of only 28 percent in cases with single, enhancing parenchymal cysts in the brain. Other studies showed that in patients with a single intracranial cysticercus, it showed a lower sensitivity of less than 50 percent and specificity 65 percent (Wilson *et al.*, 1991; Proaño-Narvaez *et al.*, 2002). Since the sources (patients) of the sera used in our research did not undergo any imaging tests and most were negative on Ag-ELISA, the performance of the commercial blot maybe lower than expected thus not being very accurate. This maybe the reason for the difference observed with the crude Immunoblot. Since there was a period of over two years between the testing of the sera by the two tests, the level of antibodies in the sera may have reduced due to repeated thawing and freezing and also storage (-20c). These factors may also contribute to the difference observed as well.

The Ab-ELISA had a sensitivity and specificity of 16 percent and 91.94 percent respectively compared to the commercial Immunoblot. Thus the Ab-ELISA had a lower performance compared to the commercial Immunoblot.

Using crude soluble extracts of *T. solium*, Atluri *et al.* (2009) reported similar findings with sensitivity of the ELISA being 38.4 percent and the specificity was 88 percent. Diaz *et al.* (1992) reported a higher Sensitivity of 65 percent by Ab-ELISA. Crude antigens have been shown to have moderate to poor sensitivity (Parija and Roman, 2011). Parija and Roman (2011) also said that synthetic and recombinant antigens have sensitivity ranging from 85-100 percent and specificity 83-100 percent. This is far much greater than that of crude antigens when used in ELISA. This explains the low sensitivity showed by the Ab-ELISA since crude

antigen of *T. solium* was used. However, Suzuki and Rossi (2011) using whole *T. solium* cysticercal extract showed 91.30 percent sensitivity and 94.30 percent specificity, whereas the sensitivity and specificity of the ELISA for the whole *Taenia crassiceps* cysticercal extract were 87 percent and 94.30 percent, respectively. The ELISA reactions for vesicular fluid from *T. solium* or *Taenia crassiceps* showed 91.30 percent sensitivity and 97.10 percent specificity (Suzuki and Rossi, 2011).

Comparison of the crude antigen immunoblot and Ab-ELISA showed significant differences between the two ($p < 0.05$). The crude immunoblot test detected more positives (25) than the Ab-ELISA (14). The level of agreement between the two tests was fairly significant ($\kappa = 0.24$). The immunoblot technique has also been found to have superior performance than the Ab-ELISA by Flisser (2003). Unpurified (crude) antigens have moderate sensitivities and relatively poor specificities (Fleury *et al.*, 2003; Schantz and Sarti, 1989), thus giving Ab-ELISA a lower performance. The immunoblot technique combines the high resolving power of gradient sodium dodecyl sulfate-polyacrylamide gel electrophoresis (SDS-PAGE) and the high sensitivity of the ELISA to produce a powerful qualitative method for detection of antibodies against *T. solium* infections (Gostein 1986). This makes it better than the Ab-ELISA.

When all 3 tests were compared, 3 percent (3) of test sera were positive and 52 percent (51) were negative on all three tests. None of the established tests (crude immunoblot and Ab-ELISA) performed better than the commercial blot. Twenty-six out of the 36 serum samples that tested positive on commercial blot were not detected by either crude cyst antigen immunoblot or Ab-ELISA (negative on both). This showed poor sensitivity of the 2 tests evaluated. Only 3 out of the 51 negative samples on commercial blot tested positive on both tests, while 6 and 2 (of the 51 negative) were positive only on crude antigen immunoblot and Ab-ELISA respectively, thus showing good specificity for the two tests.

CHAPTER SIX

6.0 CONCLUSION AND RECOMMENDATIONS

Immunoblot and Antibody ELISA tests using crude antigens of *T. solium* cysts collected from pigs in Zambia were established at the School of Veterinary Medicine, University of Zambia. To our knowledge, this is the first study that attempted to develop an EITB from crude antigens. Most EITB that have been developed so far are based on purified or recombinant antigens. The performances of the serological diagnostic tests, using crude antigens of *T. solium* metacestodes, for the diagnosis of human cysticercosis were evaluated. Due to the absence of a gold standard for serological detection of *T. solium* antibodies in serum, a commercial Immunoblots (QualiCode™ Cysticercosis Kit) was used as the standards with which the other tests were compared. Compared to the commercial kit, the crude antigen immunoblot had a sensitivity of 19.44 percent and specificity 85.48 percent ($p < 0.05$). When compared to the commercial immunoblot, the sensitivity and specificity of the Ab-ELISA were 16.67 percent and 91.94 percent respectively ($p < 0.05$). The crude antigen immunoblot and Ab-ELISA tests, showed significant difference when compared ($p < 0.05$).

The study demonstrated that crude antigen immunoblot and Ab-ELISA tests had low sensitive compared the commercial immunoblot test, while their specificity was good. In spite of this, the Ab-ELISA can be used for screening test in areas where the disease is endemic or in suspected cases of cysticercosis before more sensitive and expensive tests are employed. This is because Immunoblot and imaging tests are not available in rural areas due to the high costs associated with establishing and running them. The Ab-ELISA test also has the advantage of giving the level of antibody titres in the patient's blood, thus can be used to monitor the progression of the disease.

The lack of sera whose status for *T. solium* cysticercosis and other common parasites that are known to cross react with it, greatly affected the results obtained. The lack of a gold standard for the detection of cysticercosis also makes evaluations of new tests difficult. The limitations of the study meant that the sensitivity and specificity of the crude antigen immunoblot and Ab-ELISA

couldn't be accurately determined. The commercial immunoblot could only be used to estimate the performance of the two tests.

This study therefore recommends the following:

1. The antibody ELISA method can be used for screening exercises of large populations, especially in rural areas where the disease is endemic and in suspected cases of cysticercosis, with the crude antigen immunoblot used to confirm positive results. It cannot be used in areas where the disease is low due to its low sensitivity. It is also cheaper and easier to set up compared to more advanced methods like Western blot and imaging techniques, which are not available in most developing countries.
2. The Ab-ELISA could be made more sensitive by lowering the cut-off point, though care must be taken to avoid causing too many false positives. Alternatively, purification of antigenic components which are more immunogenic could improve the sensitivity of the test.
3. The sensitivity of the crude antigen immunoblot could be increased by using more bands for diagnosis. This could be done by using more bands that have been found to be diagnostic for *T. solium* cysticercosis like in the commercial blot.
4. Further work needs to be done with human serum samples whose status for cysticercosis and other parasitic infection is known. This will provide a better analysis of the sensitivity and specificity of the crude antigen immunoblot and Ab-ELISA tests that have been established.

REFERENCES

1. Allan, J.C., Avila G., Garcia-Noval J., Flisser A. and Craig P.S. (1990). Immunodiagnosis of taeniasis by Coproantigen detection. *Parasitology*, 101: 473-477.
2. Allan, J.C., Mencos, F., Garcia Noval, J., Sarti, E., Flisser, A., Wang, Y., Liu, D. and Craig, P.S. (1993). Dipstick dot ELISA for detection of *Taenia* coproantigens in humans. *Parasitology*, 107: 79-85.
3. Allan, J.C., Velasquez-Tohom, M., Torres-Alvarez, R., Yurrita, P. and Garcia-Noval, J. (1996). Field trial of the coproantigen-based diagnosis of *Taenia solium* taeniasis by enzymelinked immunosorbent assay. *American Journal of Tropical Medicine and Hygiene*, 54: 352-356.
4. Allan, J.C., Wilkins, P.P., Tsang, V.C. and Craig, P.S. (2003). Immunodiagnostic tools for taeniasis. *Acta Tropica*, 87: 87-93.
5. Almeida, C.R., Stoco, P.H., Wagner, G., Sincero, T.C., Rotava, G., Bayer-Santos, E., Rodrigues, J.B., Sperandio, M.M., Maia, A.A., Ojopi, E.P., Zaha, A., Ferreira, H.B., Tyler, K.M., Dávila, A.M., Grisard, E.C. and Dias-Neto, E. (2009). Transcriptome analysis of *Taenia solium* cysticerci using Open Reading Frame ESTs (ORESTES). *Parasit Vectors*, 2: 1756-3305.
6. Alvarez, J.L., Colegial, C.H., Castano, C.A., Trujillo, J. and Restrepo, B.I. (2002a). The human nervous tissue in proximity to granulomatous lesions induced by *Taenia solium* metacestodes displays an active response. *Journal of Neuroimmunology*, 127: 139-144.
7. Alvarez, J.L., Londono, D.P., Alvarez, A.L., Trujillo, J. Jaramillo, M.M. and Restrepo, B.I. (2002b). Granuloma formation and parasite disintegration in porcine cysticercosis: comparison with human neurocysticercosis. *Journal of Comparative Pathology*, 127: 186-193.
8. Atluri, S.R., Singhi, P., Khandelwal, N. and Malla, N. (2009). Neurocysticercosis Immunodiagnosis using *Taenia solium* cysticerci

- crude soluble extract, excretory secretory and lower molecular mass antigens in serum and urine samples of Indian children. *Acta Tropica*, 110: 22-27.
9. B0a, M.E., Kassuku, A.A., Willingham, A.L 3 rd., Keyyu, J.D., Phiri, I.K. and Nansen, P. (2002). Distribution and density of cysticerci of *Taenia solium* by muscle groups and organs in naturally infected local finished pigs in Tanzania. *Veterinary Parasitology*, 106: 155-64.
 10. Brown, M.A. and Semelka R.C. (2003). *MRI: Basic Principles and Applications*, 3rd ed. Wiley-Liss.
 11. Carabin, H., Krecek, C.R., Cowan, D.L., Michael, L., Foyaca-Sibat, H., Nash, T. and Willingham, L.A. (2006). Estimation of the cost of *Taenia solium* cysticercosis in Eastern Cape Province, South Africa. *Tropical Medicine and International Health*, 11: 906-916.
 12. Carpio A. (2002). Neurocysticercosis: an update. *Lancet infectious diseases*, 2: 751-762.
 13. Carpio, A., Escobar, A., and Hauser, A.W. (1998). Cysticercosis and Epilepsy: A critical review. *Epilepsia*, 39: 1025-1040.
 14. Chung, J.Y., Bahk, Y.Y., Huh, S., Kang, S.Y., Kong Y. and Cho, S.Y. (1999). A recombinant 10-kDa protein of *Taenia solium* metacestodes specific to active neurocysticercosis. *Journal of Infectious Diseases*, 180: 1307-1315.
 15. Correa, D., Tapia-Romero, R., Meza-Lucas, A. and Mata-Ruiz, O. (2002). Antigen-based Immunoassays in the Diagnosis of *Taenia solium* Cysticercosis. In: *Taenia solium Cysticercosis: From Basic to Clinical Science*. Singh, G. and Prabhakar, S, Ed. CABI Publishing, Wallingford. 343-349.
 16. Cox, F. E. G. (2002). History of Human Parasitology. *Clinical microbiology reviews*, 15: 595–612.
 17. Craig, P. and Ita, A. (2007). Intestinal Cestodes. *Current Opinions in Infectious Diseases*, 20: 524-532.

18. de Souza, A., Nalini, A., Kovoov, J.M., Yeshraj, G., Siddalingaiah, H.S. and Thennarasu, K. (2010). Natural history of solitary cerebral cysticercosis on serial magnetic resonance imaging and the effect of albendazole therapy on its evolution. *Journal of the Neurological Sciences*, 288: 135-141.
19. Del Brutto, O.H. (1997). Albendazole therapy for subarachnoid cysticerci: clinical and neuroimaging analysis of 17 patients. *Journal of Neurology, Neurosurgery and Psychiatry*, 62: 659-661.
20. Del Brutto, O.H., Rajshekhar, V., White J, A.C., Tsang, V.C., Nash, T.E. and Takayanagui, O.M. (2001) Proposed diagnostic criteria for neurocysticercosis. *Neurology*, 57: 177-183.
21. Del Brutto, O.H., Santibanez, R., Idrovo, L., Rodriguez, S., Diaz-Calderon, E., Navas, C., Gilman, R.H., Cuesta, F., Mosquera, A., Gonzalez, A.E., Tsang, V.C.W. and Garcia, H.H. (2005). Epilepsy and neurocysticercosis in Atahualpa: A door-to-door survey in rural coastal Ecuador. *Epilepsia*, 46: 583-587.
22. Dias, A.K., Aoki, S.M., Garcia, J.F. and Nunes, C.M. (2007). *Taenia solium* and *Taenia saginata*: identification of sequence characterized amplified region (SCAR) markers. *Experimental Parasitology*, 117: 9-12.
23. Diaz, J.F., Verastegui, M., Gilman, R.H., Tsang, V.C.W., Pilcher, J.B., Gallo, C., Garcia, H.H., Torres, P., Montenegro, T., Miranda, E. and The Cysticercosis Working Group in Peru (CWG). (1992). Immunodiagnosis of Human Cysticercosis (*Taenia solium*): a Field Comparison of an Antibody-Enzyme-Linked Immunosorbent Assay (ELISA), an Antigen-ELISA, and an Enzyme-Linked Immuno-electrotransfer Blot (EITB) Assay in Peru. *American Journal of Tropical and Medicine and Hygiene*, 46: 610-615.
24. Dorny, P., Brandt, J., Zoli, A. and Geerts, S. (2003). Immunodiagnostic tools for human and porcine cysticercosis. *Acta Tropica*, 87: 79-86.

25. Dorny, P., Phiri, I.K., Vercruyssen, J., Gabriel, S., Willingham, A.L. 3rd., Brandt, J., Victor, B., Speybroeck, N. and Berkvens, D. (2004). A Bayesian approach for estimating values for prevalence and diagnostic test characteristics of porcine cysticercosis. *International Journal for Parasitology*, 34: 569-576.
26. Erhart, A., Dorny, P., Nguyen, V.De., Ha Viet, V., Dang, C.T., Nguyen, D.T., Le Dinh, C., Geerts, S., Speybroeck, N., Berkvens, D. and Brandt, J. (2002). *Taenia solium* cysticercosis in a village in Northern Vietnam: Sero-prevalence study using an ELISA for detecting circulating antigen. *Transactions of the Royal Society of Tropical Medicine and Hygiene*, 96; 270-272.
27. First WHO report on neglected tropical diseases (2010): working to overcome the global impact of neglected tropical diseases.
28. Fleury, A., Beltran, C., Ferrer, E., Garate, T., Harrison, L.J.S., Parkhouse, R.M.E., Garcia, E., Fragoso, G., Costa-Cruz, J., Biondi, G., Agapejev, S. and Scuitto, E. (2003). Application of synthetic peptides to the diagnosis of neurocysticercosis. *Tropical Medicine and International Health*, 8: 1124-1130.
29. Flisser, A. (1994). Taeniasis and cysticercosis due to *T solium*. In: Sun T, editor. *Progress in clinical parasitology*. CRC Press; New York: 77-116.
30. Flisser, A., Gonzalez, D., Plancarte, A., Ostrosky, P., Montero, R., Stephano, A. and Correa, D. (1990b). Praziquantel treatment of brain and muscle porcine *Taenia solium* cysticercosis. 2. Immunological and cytogenetic studies. *Parasitology Research*, 76: 640-642.
31. Flisser, A., Gonzalez, D., Rodriguez-Carbajal, J., Shkurovich, M., Correa, D., Cohen, S., Collado, M., Madrazo, I., Rodriguez-del Rosal, E., Fernandez, B., Fernandez, F. and Aluja, A.S. (1990a). Praziquantel treatment of porcine brain and muscle *Taenia solium* cysticercosis. 1. Radiological, physiological and histopathological studies. *Parasitology Research*, 76: 263-269.

32. Flisser, A., Plancarte, A., Correa, D., Rodriguez-Del-Rosal, E., Feldman, M., Sandoval, M., Torres, A., Meza, A., Parkhouse, R.M. and Harrison, L.J. (1990). New approaches in the diagnosis of *Taenia solium* cysticercosis and taeniasis. *Annales de Parasitologie Humaine et Comparee*, 65: 95-98.
33. Flisser, A., Sarti, E., Lightowers, M. and Schantz, P. (2003). Neurocysticercosis: regional status, epidemiology, impact and control measures in the Americas. *Acta Tropica*, 87: 43-51.
34. Fragoso, G., Esquivel-Guadarrama, F., Santana, M.A., Bobes, J.R., Hernández, B., Cervantes, J., Segura, R., Goldbaum, A.F., Scuitto, E. and Rosas, G. (2011). Heterologous Prime-Boost Oral immunization with GK-1 Peptide from *Taenia crassiceps* Cysticerci Induces Protective immunity. *Clinical and Vaccine Immunology*, 18:1067.
35. Garcia, H.H, Armando, E. G, Carlton, A.W.E. and Robert H.G. (2003). *Taenia solium* Cysticercosis. *The Lancet*, 361: 547-556.
36. Garcia, H.H., Del Brutto, O.H., Nash, T.E., White, A.C., Tsang, V.C.W. and Gilman, R.H. (2005). New concepts in the diagnosis and management of neurocysticercosis (*Taenia solium*). *American Journal of Tropical Medicine and Hygiene*, 72: 3-9.
37. Garcia H.H., Evans C.A., Nash T.E., Takayanagui O.M., White A.C Jr, Botero D, Rajshekhar V., Tsang V.C., Schantz P.M., Allan J.C., Flisser A., Correa D., Sarti E., Friedland J.S., Martinez S.M., Gonzalez A.E., Gilman R.H. & Del Brutto O.H. (2002). Current consensus guidelines for treatment of neurocysticercosis. *Clinical Microbiology Reviews*, 15:747-756.
38. Garcia, H.H., Gilman, R.H., Catacora, M., Verastegui, M, Gonzalez, A.E. and Tsang, V.C. (1997). The cysticercosis working Group in Peru. Serological evolution of neurocysticercosis patients after antiparasitic therapy. *Journal of infectious Diseases*, 175: 486-489.
39. Garcia, H.H., Gonzalez, A.E., Gilman, R.H., Moulton, L.H., Verastegui, M., and Rodriguez, S. (2006). Cysticercosis Working

- Group in Peru. Combined human and porcine mass chemotherapy for the control of *T. solium*. American Journal of Tropical Medicine and Hygiene, 74: 850-855.
40. Garcia, H.H., Harrison, L.J.S., Parkhouse, R.M.E., Montenegro, T., Martinez, S.M., Tsang, V.C.W. and Gilman, R.H. (1998). A specific antigen-detection ELISA for the diagnosis of human neurocysticercosis. Transactions of the Royal Society of Tropical Medicine and Hygiene, 92: 411-414.
 41. Garcia, H.H., Herrera, G., Gilman, R.H., Tsang, V.C.W., Pilcher, J.B., Diaz, J.F., Candy, E.J., Miranda, E., Naranjo, J., Torres, P. and others. (1994). Discrepancies Between Cerebral Computed Tomography and Western Blot in the Diagnosis of Neurocysticercosis. American Journal of Tropical Medicine and Hygiene, 50: 152-157.
 42. Garcia, H.H., Parkhouse, R.M.E., Gilman, R.H., Montenegro, T., Bernal, T., Martinez, S.M., Gonzalez, A.E., Tsang, V.C, Harrison, L.J.S. and The Cysticercosis Working Group in Peru. (2000). Serum antigen detection in the diagnosis, treatment, and follow-up of neurocysticercosis patients. Transactions of the Royal Society of Tropical Medicine and Hygiene, 94: 673-676.
 43. Garrido, G.S., de Aluji, A.S. and Casas, F.C. (2007). Early Stages of development of the *Taenia solium* metacestode in pigs. Journal of Parasitology, 93: 238-241.
 44. Gomes, A.B., Soares, K.A., Bueno, E.C., Espindola, N.M., Iha, A.H., Maia, A.A., Peralta, R.H. and Vaz, A.J. (2007). Comparative evaluation of different immunoassays for the detection of *Taenia solium* cysticercosis in swine with low parasite burden. Memorias do Instituto Oswaldo Cruz, 102: 725-731.
 45. Gonzales A.E., Garcia H.H., Gilman R.H., Tsang V.C.W. and Cysticercosis Working Group in Peru. (2003). Control of *Taenia solium*. Acta Tropica, 87: 103-109.

46. Gonzalez, A.E., Cama, V., Gilman, R.H., Tsang, V.C.W., Pilcher, J.B., Chavera, A., Castro, M., Montenegro, T., Verastegui, M., Miranda, E. and Baltazar, E. (1990). Prevalence and comparison of serological assays, necropsy, and tongue examinations for the diagnosis of porcine cysticercosis in Peru. *American Journal of Tropical Medicine and Hygiene*, 43: 194-199.
47. Gonzalez, A.E., Falcon, N., Gavidia, C., Garcia, H.H., Tsang, V.C.W., Bernal, T., Romero, M., and Gilman, R.H. (1997). Treatment of porcine cysticercosis with oxfendazole: a doseresponse trial. *Veterinary Record*, 18.
48. Gonzalez, A.E., Falcon, N., Gavidia, C., Garcia, H.H., Tsang, V.C.W., Bernal, T., Romero, M., and Gilman, R.H. (1998). Time-response curve of oxfendazole in the treatment of swine cysticercosis. *American Journal of Tropical Medicine and Hygiene*, 59: 832-836.
49. Gottstein, B., Tsang, W.C.V. and Schantz, P.M. (1986). Demonstration of Species-specific and cross-reactive components of *Taenia solium* metacestodes antigens. *American Journal of Tropical Medicine and Hygiene*, 35: 308-313.
50. Gracey, J.F and Collins, D.S. (1992). *Meat Hygiene*. Bailliere Tindall, London. 401-421.
51. Herrera, L.A., Benitez-Bribiesca, L., Sotelo, J. and Ostrosky-Wegman, P. (2000). Chemotherapy of cysticercosis. Review about its pharmacokinetics and toxicology. *Gaceta Medica de Mexico*, 136: 477-489.
52. Hsieh, J. (2009), *Computed Tomography: Principles, Design, Artifacts, and Recent Advances*. 2nd ed. SPIE Publications.
53. Huerta, M., Scuitto, E., Garcia, G., Villalobos, N., Hernandez, M., Fragoso, G., Diaz, J., Diaz, A., Ramirez, R., Luna, S., Garcia, J., Aguilar, E., Espinoza, S., Castilla, G., Bobadilla, J. R., Avila, R., Jose, M.V., Larralde, C. and de Aluja A.S. (2000). Vaccination against *Taenia solium* cysticercosis in underfed rustic pigs of Mexico: roles of

- age, genetic background and antibody response. *Veterinary Parasitology*, 27:209–219.
54. Huisa, N.B., Menacgo, A.L., Rodriguez, S., Bustos, A.J., Gilman, H.R., Tsang, W.C.V., Gonzalez, E.A., Garcia, H.H., for the Cysticercosis working group in Peru.(2005). Taeniasis and Cysticercosis in housemaids working in affluent neighborhoods in Lima, Peru. *American Journal of Tropical Medicine and Hygiene*, 73: 496-500.
 55. Ir TIDO, T. (2004). Prevalence of human *Taenia solium* cysticercosis in Mayo-Danay division (Cameroon). Master's Thesis, Institute of Tropical Medicine (ITMA) Antwerp, Belgium.
 56. Ito A, Wandra T, Yamasaki H, Nakao M, Sako Y, Nakaya K, Margono SS, Suroso T, Gauci C, Lightowers MW. (2004). Cysticercosis/taeniasis in Asia and the Pacific. *Vector-borne Zoonotic Diseases*, 4:95-107.
 57. Ito A. & Craig P.S. (2003). Immunodiagnostic and molecular approaches for the detection of taeniid cestode infections. *Trends in Parasitology*. 19, 377-381.
 58. Ito, A., Nakao, M., Kutsumi, H., *et al.* (1993) Serodiagnosis of alveolar hydatid disease by Western blotting. *Transactions of the Royal Society of Tropical Medicine and Hygiene*, 87: 170–172.
 59. Ito, A., Plancarte, A., Ma, L., Kong, Y., Flisser, A., Cho, S.Y., Liu, Y.H., Kamhawi, S., Lightowers, M.W. and Schantz P.M. (1998). Novel antigens for neurocysticercosis: simple method for preparation and evaluation for serodiagnosis. *American Journal Tropical Medicine and Hygiene*, 59: 291-294.
 60. Ito, A., Sako, Y., Nakao, M. and Nakaya, K. (2002). Neurocysticercosis in Asia: Serology/ seroepidemiology in humans and pigs. In *Cestode Zoonoses: Echinococcosis and Cysticercosis*, P. Craig and Z. Pawlowski, eds. IOS Press, 25-31.

61. Kapila, K., Sahai, K. and Verma, K. (2003). Semi-quantitative analysis of soft-tissue reactions in fine needle aspirates from tissue cysticercosis. *Cytopathology*, 14, 208-211.
62. Lapage, G. (1965). *Monnig's Veterinary Helminthology and Entomology*, 5 Ed. London, Bailliere, Tindall and Cassell. 129-131.
63. Le Riche, P.D. and Sewell, M.M. (1978). Differentiation of taeniid cestodes by Enzyme Electrophoresis. *International Journal for Parasitology*, 8: 479-483.
64. Lightowers, M.W. (1990). Cestode infections in animals: immunological diagnosis and vaccination. *Revue Scientifique et Technique (International Office of Epizootics)*, 9: 463-87.
65. Lightowers, M.W. (2003). Vaccines for prevention of cysticercosis. *Acta Tropica*, 87: 129-135.
66. Manoutcharian, K., Rosas, G., Hernándeiz, M., Fragoso, G., Aluja, A., Villalobos, N., Rodarte, L. F. and Scuitto, E. (1996). Cysticercosis : identification and cloning of protective recombinant antigens. *Journal of Parasitology*, 82: 250–254.
67. Mayta, H., Gilman, R.H., Prendergast, E., Castillo, J.P., Tinoco, Y.O., Garcia, H.H., Gonzalez, A.E., Sterling, C.R., for the Cysticercosis Working Group in Peru. (2008). Nested PCR for specific Diagnosis of *Taenia solium* Taeniasis. *Journal of Clinical Microbiology*, 46: 286-289.
68. Meslin, F.X., Stöhr, K. and Heymann, D. (2000). *Revue Scientifique et Technique (International Office of Epizootics)*, 19: 310-317.
69. Murrell, K.D. (1991). Economic losses resulting from food borne parasitic zoonoses. *Southeast Asia Journal of Tropical Medicine and Public Health*, 22: 377-381.
70. Murrell, K.D., Dorny, P., Flisser, A., Geerts, S., Kyvsgaard, N.C., McManus, D.P., Nash, Z.S. and Pawlowski, T.E. (2005). WHO/FAO/OIE Guidelines for the surveillance, prevention and control of taeniosis/cysticercosis.

71. Nash, E.T., Singh, G., White, A.C., Rajshekhar, V., Loeb, A.J., Proano, J.V., Takayanagui, O.M., Gonzalez, A.E., Butman, J.A., DeGiorgio, C., Bel Brutto, O.H., Delgado-Escueta, A., Evans, C.A.W., Gilman, R.H., Martinez, S.M., Medina, M.T., Pretell, E.J., Teale, J. and Garcia, H.H. (2006). Treatment of Neurocysticercosis: Current status and future research needs. *Neurology*, 67: 1120-1127.
72. Nash, T.E. (2003). Human case management and treatment of cysticercosis. *Acta Tropica*, 87: 61-69.
73. Nguekam, J.P., Zoili, A.P., Vondou, L., Pouedet, S.M.R., Assana, E., Dorny, P., Brandt, J. and Geerts, S. (2003). Kinetics of circulating antigens in pigs experimentally infected with *Taenia solium* eggs. *Veterinary Parasitology*, 111: 323-332.
74. Nunes, C.M., Lima, L.G., Manoel, C.S., Pereira, R.N., Nakano, M.M. and Garcia, J.F. (2003). *Taenia saginata*: polymerase chain reaction for taeniasis diagnosis in human fecal samples. *Experimental Parasitology*, 104: 67-69.
75. Onyango-Abuje, J.A., Hughes, G., Opicha, M., Nginyi, K.M., Rugutt, M.K., Wright, S.H. and Harrison, J.J. (1996). Diagnosis of *Taenia saginata* cysticercosis in Kenyan cattle by antibody and antigen ELISA. *Veterinary Parasitology*, 61: 221-230.
76. Pardini, A.X., Peralta, R.H., Vaz, A.J., Machado Ldos, R. and Peralta, J.M. (2002). Use of *Taenia crassiceps* cysticercus antigen preparations for detection of antibodies in cerebrospinal fluid samples from patients with neurocysticercosis (*Taenia solium*). *Clinical and Diagnostic Laboratory Immunology*, 9: 190-193.
77. Parija, S.C. and Raman, G.A. (2011). Anti-*Taenia solium* larval stage IgG antibodies in patients with epileptic seizures. *Tropical Parasitology*, 1:20-25.
78. Pawlowski, Z.S. (2002). *Taenia solium*: basic biology and transmission-*Taenia Solium* Cysticercosis: In: Singh, S.G. and

Prabhakar, S. (Ed.), From Basic to Clinical Science. CBA international 1-14.

79. Peniche-Cardena, A., Dominguez-Alpizar, J.L., Sima-Alvarez, R., Argaez-Rodriguez, F., Fraser, A., Craig, P.S., Rodriguez-Canul, R., 2002. Chemotherapy of porcine cysticercosis with albendazole sulphoxide. *Veterinary Parasitology*, 2381: 1-11.
80. Phiri, I.K., Dorny, P., Gabriel, S., Willingham, A.L 3rd., Sikasunge, C., Siziya, S. and Vercruysse, J. (2006). Assessment of routine inspection methods for porcine cysticercosis in Zambian village pigs. *Journal of Helminthology*, 80: 69-72.
81. Phiri, I.K., Dorny, P., Gabriel, S., Willingham, A.L 3rd., Speybroeck, N. and Vercruysse, J. (2002). The prevalence of porcine cysticercosis in Eastern and Southern provinces of Zambia. *Veterinary Parasitology*, 30: 108: 31-39.
82. Phiri, I.K., Ngowi, H., Afonso, S., Matenga, E., Boa, M., Mukaratirwa, S., Githigia, S., Saimo, M., Sikasunge, C., Maingi, N., Lubega, G.W., Kassuku, A., Michael, L., Siziya, S., Krecek, R.C., Noormahomed, E., Vilhena, M., Dorny, P. and Willingham, A.L 3rd. (2003). The emergence of *Taenia solium* cysticercosis in Eastern and Southern Africa as a serious agricultural problem and public health risk. *Acta Tropica*, 87: 13-23.
83. Poretti, D, Felleisen, E, Grimm, F et al. (1999). Differential immunodiagnosis between cystic hydatid disease and other cross-reactive pathologies. *American Journal of Tropical Medicine and Hygiene*, 60: 193–198.
84. Pouedet, M.S.R., Zoli, A.P., Nguokam, J.P., Vondou, L., Assana, E., Speybeok, N., Berkvens, D., Dorny, P., Brandt, J. and Geerts, S. (2002). Epidemiological survey of swine cysticercosis in two rural communities of West-Cameroon. *Veterinary Parasitology*, 106: 45-54.
85. Prado-Jean, A., Kanobana, K., Druet-Cabanac, M., Nsengyiumva, G., Dorny, P., Preux, M.P. and Geerts, S. (2007). Combined use of an

- antigen and antibody detection enzyme-linked immunosorbent assay for cysticercosis as tools in an epidemiological study of epilepsy in Burundi. *Tropical Medicine and International Health*, 12: 895–901.
86. Prasad, K., Chawla, S., Prasad, A., Tripathi, M., Husain, N. and Gupta, R. (2006). Clinical signs for the identification of neurocysticercosis in swine naturally infected with *Taenia solium*. *Parasitology International*, 55: 151-154.
87. Preux, P.M., Thiemagni, F., Fodzo, L., Kandem, P., Ngoua-fong, P., Ndongo, F., Macharia, W., Dongmo, L. and Dumas, M. (2000). Antiepileptic therapies in the Mifi province in Cameroon. *Epilepsia*, 41: 432-439.
88. Proaño-Narvaez, J.V., Meza-Lucas, A., Mata-Ruiz, O., Garcia-Jeronimo, R.C. and Correa, D., (2002). Laboratory Diagnosis of Human Neurocysticercosis: Double-Blind Comparison of Enzyme-Linked Immunosorbent Assay and Electroimmunotransfer Blot Assay. *Journal of Clinical Microbiology*, 40: 2115-2118.
89. Rajshekhar, V., Joshi, D.D., Doanh, Q.N., De, V.N. and Xiaonong, Z. (2003). *Taenia solium* taeniasis/cysticercosis in Asia: epidemiology impact and issues. *Acta Tropica*, 87: 53-60.
90. Roberts, T., Murrell, K.D. and Marks, S. (1994). Economic losses caused by foodborne parasitic diseases. *Parasitology Today*, 10: 419-423.
91. Rodriguez-Hidalgo, R. (2007). The epidemiology of *Taenia* spp. and cysticercosis in Ecuador. PhD. Dissertation, Universiteit Gent.
92. Rodriguez-Hidalgo, R., Geysen, D., Benitez-Ortiz, W., Geerts, S. and Brandt, J. (2002). Comparison of conventional techniques to differentiate between *Taenia solium* and *Taenia saginata* and an improved polymerase chain reaction-restriction fragment length polymorphism assay using a mitochondrial 12S rDNA fragment. *Journal of Parasitology*, 88: 1007-1011.

93. Rodriguez-Hidalgo, R., Geysen, D., Benítez-Ortiz, W., Geerts, S. and Brandt, J. (2002). Comparison of conventional techniques to differentiate between *Taenia solium* and *Taenia saginata* and an improved polymerase chain reaction-restriction fragment length polymorphism assay using a mitochondrial 12s rDNA fragment. *Journal of Parasitology*, 80: 1007-1011.
94. Rogan, M.T. and Craig, P.S. (2002). Immunological approaches for transmission and epidemiological studies in cestodes zoonoses –The role of serology in human infection. In: *Cestode zoonoses: echinococcosis and cysticercosis; an emergent and global problem.* Craig P. and Pawlowski Z, (Ed). IOS Press, Amsterdam: 135-145.
95. Rosas, N., Sotelo, J. and Nieto, D. (1986). ELISA in the diagnosis of neurocysticercosis. *Archives of Neurology*, 43: 353-356.
96. Sako, Y., Nakao, M., Ikejima, T., Piao, X.Z., Nakaya, K. and Ito, A. (2000). Molecular characterization and diagnostic value of *Taenia solium* low-molecular-weight antigen genes. *Journal of Clinical Microbiology*, 38: 4439-4444.
97. Sánchez, A.L., Medina, M.T. and Ljungström, I. (1998). Prevalence of taeniasis and cysticercosis in a population of urban residence in Honduras. *Acta Tropica*, 69: 141-149.
98. Sarti, E., Flisser, A., Schantz, P.M., Gleizer, M., Loya, M., Plancarte, A., Avila, G., Allan, J., Craig, P., Bronfman, M. and Wijeyaratne, P. (1997). Development and evaluation of a health education intervention against *Taenia solium* in a rural community in Mexico. *American Journal of Tropical Medicine and Hygiene*, 56: 127-132.
99. Sato, M.O., Yamasaki, H., Sako, Y., Nakao, M., Nakaya, K., Plancarte, A., Kassuku, A.A., Dorny, P., Geerts, S., Benitez-Ortiz, W., Hashiguchi, Y. and Ito, A. (2003). Evaluation of tongue inspection and serology for diagnosis of *Taenia solium* cysticercosis in swine: usefulness of ELISA using purified glycoproteins and recombinant antigen. *Veterinary Parasitology*, 111: 309-322.

100. Schantz, P.M., Wilkins, P.P. and Tsang, V.C.W. (1998). - Immigrants, imaging and immunoblots: the emergence of neurocysticercosis as a significant public health problem. In *Emerging Infections*, (W.M. Scheld, W.A. Craig & J.M. Hughes, eds), Vol. 2, ASM Press (Washington, D.C.), 213-242.
101. Schantz, M.P., Moore, C.A., Munoz, L.J., Hartman, J.B., Schaefer, A.J., Aron, M.A., Persaud, D., Sarti, E., Wilson, M. and Flisser, A. (1992). Neurocysticercosis in an Orthodox Jewish community in New York City. *The New England Journal of Medicine*, 327: 692-695.
102. Schantz, P.M. and Sarti-Gutierrez, E. (1989). Diagnostic methods and epidemiologic surveillance of *Taenia solium* infection. *Acta Leidensia*, 57: 153-164.
103. Scheel, C.M., Khan, A., Hancock, K., Garcia, H.H., Gonzalez, A.E., Gilman, R.H. and Tsang, V.C. (2005). Serodiagnosis of neurocysticercosis using synthetic 8-kD proteins: comparison of assay formats. *American Journal of Tropical Medicine and Hygiene*, 73: 771-776.
104. Scuitto, E., Chavarria, A., Fragoso, G., Fleury, A., and Larralde, C. (2007). The immune response in *Taenia solium* cysticercosis: protection and injury. *Parasite Immunology*, 29: 621-636.
105. Scuitto, E., Aluja, A., Fragoso, G., Rodarte, L.F., Hernández, M., Villalobos, M.N., Padilla, A., Keilbach, N., Baca, M., Govezensky, T., Díaz, S. and Larralde, C. (1995). Immunization of pigs against *Taenia solium* cysticercosis: factors related to effective protection. *Veterinary Parasitology*, 60:53-67.
106. Scuitto, E., Fragoso G., Fleury, A., Laclette, J.P., Sotelo, J., Aluja, A., Vargas, L. and Larralde, C. (2000). *Taenia solium* disease in humans and pigs: An ancient parasitosis disease rooted in developing countries and emerging as a major health problem of global dimensions. *Microbes and Infection*, 2: 1875-1890.

107. Scuitto, E., Hernández, M., García, G., de Aluja, A.S., Villalobos, A.N., Rodarte, L.F., Parkhouse, M. and Harrison, L. (1998). Diagnosis of porcine cysticercosis: a comparative study of serological tests for detection of circulating antibody and viable parasites. *Veterinary Parasitology*, 78: 185-194.
108. Sharma, T., Sinha, S., Shah, N., Gopal, L., Shanmugam, M.P., Bhende, P., Bhende, M., Shetty, N.S., Agrawal, R., Deshpande, D., Biswas, J. and Sukumar, B. (2003). Intraocular cysticercosis: clinical characteristics and visual outcome after vitreoretinal surgery. *Ophthalmology*, 110: 996-1004.
109. Shiguekawa, M.Y.K., Mineo, R.J., de Moura, P.L. and Costa-Cruz, M.J. (2000). ELISA and Western Blotting tests in the detection of IgG antibodies to *Taenia solium* metacestodes in serum samples in human neurocysticercosis. *Tropical Medicine and International Health*, 5: 443–449.
110. Sikasunge C.S. (2005). The prevalence and transmission risk factors of porcine cysticercosis in Eastern and Southern provinces of Zambia. Master thesis, University of Zambia.
111. Sikasunge, C.S., Phiri, I.K., Phiri, A.M., Dorny, P., Siziya, S. and Willingham, A.L 3rd. (2007). Risk factors associated with porcine cysticercosis in selected districts of Eastern and Southern provinces of Zambia. *Veterinary Parasitology*, 143: 59-66.
112. Sikasunge, C.S., Phiri, I.K., Siziya, S., Dorny, P. and Willingham, A.L 3rd (2008). Prevalence of *Taenia solium* porcine cysticercosis in Eastern, Southern and Western provinces of Zambia. *The Veterinary journal*, 176: 240-244.
113. Sikasunge, C.S. (2009). Immuno-pathological responses to *Taenia solium* infections in pigs. PhD thesis, University of Copenhagen.
114. Singhi, P. (2011). Neurocysticercosis Therapeutic Advances in *Neurological Disorders*, 4: 67-81.

115. Singhi, P. and Singhi, S. (2004). Neurocysticercosis in children. *Journal of Child Neurology*, 19: 482-92.
116. Slifko, R.T., Smith, V. H. and Rose, B.J. (2000). Emerging parasite zoonoses associated with water and food. *International Journal for Parasitology*, 30: 1379-1393.
117. Smyth D.J. (1994). *Introduction to animal parasitology*. Cambridge press, Britain 330-333.
118. Soulsby, L.J.E. (1982). *Helminths, Arthropods and Protozoa of Domesticated animals*. Baillere Tindal, London, (7 Ed) 111-113.
119. Suzuki, A.L. and Rossi, L.C. (2011). Evaluation of two *Taenia solium* cysticercal antigenic preparations (vesicular fluid and a glycoprotein fraction with affinity for lentil lectin) for the immunodiagnosis of neurocysticercosis by enzyme-linked immunosorbent assay (ELISA). *Arquivos de Neuro-Psiquiatria*, 69: 470-474.
120. Tefera, G. (2008). Development of a dipstick ELISA for the detection of circulating antigens of *Taenia saginata/Taenia solium* cysticercosis. Master's Thesis, Institute of Tropical Medicine (ITM) Antwerpen (Antwerp), Belgium.
121. Toledo, A., Larralde, C., Fragoso, G., Gevorkian, G., Manoutcharian, K., Hernández, M., Acero, G., Rosas, G., Lopez-Casillas, F., Garfias, C. K., Vazquez, R., Terrazas, I. and Scuitto, E. (1999). Towards a *Taenia solium* cysticercosis vaccine: an epitope shared by *Taenia crassiceps* and *Taenia solium* protects mice against experimental cysticercosis. *Infection and Immunity*, 67: 2522–2530.
122. Torres, A., Plancarte, A., Villalobos, M.N.A., De Aluja, A.S., Navarro, R. and Flisser, A. (1992). Praziquantel treatment of porcine brain and muscle *Taenia solium* cysticercosis. Effect of 1-day treatment. *Parasitology Research*, 78: 161-164.
123. Tsang, V.C., Brand, J.A. and Boyer, A.E. (1989). An enzyme-linked immunoelectrotransfer blot assay and glycoprotein antigens for

- diagnosing human cysticercosis (*Taenia solium*). *Journal of Infectious Diseases*, 159; 50-59.
124. Tsang, V.C.W., Pilcher, J.A. and Zhou, W. (1991). Efficacy of the Immunoblot assay for cysticercosis in pigs and modulated expression of district IgM/IgG activities to *Taenia solium* antigens in experimental infections. *Veterinary Immunology and Immunopathology*, 29: 69-78.
 125. Urquhart, G.M., Armour, J., Duncan, J.L., Dunn, A.M. and Jennings, F.W. (1987). *Veterinary Parasitology*. Longman Scientific and Technical, Great Britain 116–122.
 126. Vasconcelos, D. (1990). From cyst to cysticercus granuloma using cranial computerized tomography. *Gaceta Medica de Mexico*, 126: 401–04.
 127. Viera, J.A. and Garrett, M.J. (2005). Understanding and Interobserver Agreement: The Kappa Statistic. *Family Medicine*, 3: 360-363.
 128. White, A. C. (1997). Neurocysticercosis: a major cause of neurological disease worldwide. *Clinical Infectious Diseases*, 24:101-15.
 129. WHO (2010). *Neglected Tropical Diseases in the World Today*.
 130. WHO, (2003). Control of neurocysticercosis. In. Fifty-sixth world health assembly, Provisional agenda item 14.2. A56/10.
 131. Wilkins, P.P., Allan, J.C., Verastegui, M., Acosta, M., Eason, A.G., Garcia, H.H., Gonzalez, A.E., Gilman, R.H. and Tsang, V.C.W., (1999). Development of a serologic assay to detect *Taenia solium* taeniasis. *American Journal of Tropical Medicine and Hygiene*, 60: 199-204.
 132. Wilkins, P.P., Wilson, M., Allan, J.C. and Tsang, V.C.W. (2002). *Taenia solium* Cysticercosis: Immunodiagnosis of Neurocysticercosis and Taeniasis. In: *Taenia solium* Cysticercosis: From Basic to Clinical Science. Singh G. and Prabhakar S., editors. CABI Publishing, Wallingford 329-341.

133. Wilson, A. (1991). Practical meat inspection, Parasitic diseases, (5 Ed), Blackwell scientific publication, 165.
134. Wilson, M. and Schantz, P. (1991). Nonmorphologic Diagnosis of Parasitic Infections. Manual of Clinical Microbiology, (5 Ed), American Society Of Microbiology, Washington, D.C., 717-726.
135. Wilson M, Gryan R, Fried J, et al. (1991). Clinical evaluation of the cysticercosis enzyme-linked immunoelectrotransfer blot in patients with neurocysticercosis. Journal of Infectious Diseases, 164: 1007–09.
136. Winkler, S.A., Willingham, L.A., Skasunge, S.C. and Schmutzhard, E. (2009). Epilepsy and neurocysticercosis in sub-Saharan Africa. Spring Verlag, 121: 3-12.
137. World Health Organization: (2001). Epilepsy: epidemiology, aetiology and prognosis. WHO Factsheet: number 165.
138. Yamasaki, H., Allan, J.C., Sato, M.O., Nakao, M., Sako, Y., Nakaya, K., Qiu, D., Mamuti, W., Craig, P.S. and Ito, A. (2004). DNA differential diagnosis of taeniasis/cysticercosis by multiplex PCR. Journal of Clinical Microbiology, 42: 548-553.
139. Yang, H.J., Chung, J.Y., Yun, D., Kong, Y., Ito, A., Ma, L., Liu, Y., Lee, S., Kang, S. and Cho, S.Y. (1998). Immunoblot analysis of a 10 kDa antigen in cyst fluid of *Taenia solium* metacestodes. Parasite Immunology, 20: 483-488.
140. Zimic, M., Pajuelo, M., Rueda, D., Lopez, C., Arana, Y., Castillo, Y., Calderon, M., Rodriguez, S. Sheen, P. and Vinetz, M.J. (2009). Utility of a Protein Fraction with Cathepsin L-Like Activity Purified from Cysticercus Fluid of *Taenia solium* in the Diagnosis of Human Cysticercosis. American Journal of Tropical Medicine and Hygiene, 80: 964-970.
141. Zoli, A., Shey-Njila, O., Assana, E., Nguekam, J.P., Dorny, P., Brandt, J. and Geerts, S. (2003). Regional status, epidemiology and impact of *Taenia solium* cysticercosis in Western and Central Africa. Acta Tropica, 87: 35-42.

