

CHAPTER ONE

1.1 INTRODUCTION

Breast cancer is a heterogeneous disease, comprising multiple entities associated with distinctive histological and biological features, clinical presentations and behaviours and responses to therapy (Filho, 2008). It remains among the most commonly diagnosed cancers in women. Worldwide, breast cancer comprises 22.9% of all cancers (Wabinga et al, 2003). In Zambia, it is ranked number 2 after cervical cancer (Zambia National Cancer Registry Office-ZNCRO, 2011). In order to organize the heterogeneity and standardize the language, breast cancer classification systems have been developed some of which include the use of histology and immunohistochemistry (IHC) (Ikpat et al, 2005). Histological typing is important as there is a difference in biologic behavior of the various types. The various types interact with other factors to help predict the prognosis and determine the appropriate clinical management (Ikpat et al, 2005).

Breast cancer can be broadly categorized into in situ carcinoma and invasive (infiltrating) carcinoma. Breast carcinoma in situ is further sub-classified as either ductal or lobular. Growth patterns and cytological features form the basis to distinguish between the two types. Ductal carcinoma (DC) is considerably more common than its lobular carcinoma (LC) counterpart and encompasses a heterogeneous group of tumors which include comedo, cribriform, micropapillary, papillary and solid tumours (Adebamowo et al, 2000).

Similar to in situ carcinomas, invasive carcinomas are a heterogeneous group of tumors differentiated into histological subtypes. The major invasive tumor types include infiltrating ductal, invasive lobular, ductal/lobular, mucinous (colloid), tubular, medullary and papillary carcinomas. Of these, infiltrating ductal carcinoma (IDC) is, by far, the most common subtype accounting for 70–80% of all invasive lesions (Adebamowo et al, 2000).

The use of estrogen receptor (ER), progesterone receptor (PR) and human epidermal growth factor receptor 2 (HER2/neu) determinations in IDC exemplifies the potential of molecular biomarkers in guiding clinical decisions. Already, the status of these markers helps determine which patients are likely to respond to targeted therapies (i.e tamoxifen or aromatase inhibitors for ER⁺/PR⁺ patients and trastuzumab or lapatinib for HER2/neu patients) (Gakwaya et al, 2003).

The practical purpose of classification is to describe each individual instance of breast cancer in a way that helps select which treatment approach is anticipated to have the best chance for a good outcome, with increased efficacy and low toxicity. Treatment algorithms rely on breast cancer classification to define specific subgroups that are each treated according to the best evidence available. Classification aspects must be carefully tested and validated, such that confounding effects are minimized, making them either true prognostic factors, which estimate disease outcomes such as disease-free or overall survival in the absence of therapy, or true predictive factors, which estimate the likelihood of response or lack of response to a specific treatment (Gakwaya et al, 2003).

On the other hand, four main molecular classes of breast cancer have been distinguished by gene expression profiling (Perou et al, 2000). These are:

- i. basal-like breast cancers, which are ER-negative, PR-negative and HER2-negative tumors (hence, the name triple-negative tumors)
- ii. luminal-A cancers, which are ER/PR-positive and HER2 negative
- iii. luminal-B cancers, which are ER/PR and HER2-positive but may express low levels of hormone receptors
- iv. HER2-positive cancers which are ER/PR negative

Histologic analysis has changed the way breast cancer is perceived in that it is no longer regarded as a single disease. Moreover, IHC has shown the importance of proliferation as a prognostic factor for ER-positive cancers (Muthupei et al, 2004).

Some studies have shown that luminal types of tumors express high amounts of luminal cytokeratins like CK5 and genetic markers of luminal epithelial cells of normal breast. Luminal B tumors typically have a high genomic grade, similar to basal-like and HER2-positive tumors, whereas luminal A tumors have a genomic grade similar to that of normal breast tissue implying aggressiveness and poor prognosis (Muthupei et al, 2004).

The increased copy-number variation in basal-like tumors indicates more genetic complexity than in the other subtypes, suggesting a greater degree of genetic instability in these cancer tissues and a variety of growth factor receptors, including high levels of vascular endothelial growth factor (VEGF).

This study therefore, aims to describe the histology and immunohistochemical profiles of breast cancer in breast cancer samples stored in the histopathology laboratory at the University Teaching Hospital (UTH) in Lusaka.

1.2 STATEMENT OF THE PROBLEM

The pattern of malignancy in Zambia has not been well established despite efforts made to do so. Prevalence of malignancies still remains at 16% which is rather high. Among the malignancies of concern that have affected Zambia, is the female breast cancer. According to the Zambia National Cancer Registry Office (ZNCRO), breast cancers are ranked number 2 (11%) among the top five (5) cancers in Zambia from 2007 to 2009 as indicated in table 1 below.

Table 1: Malignancies Reported to National Cancer Registry Office

TYPE OF CANCER	2007	2008	2009	TOTAL
Cervix	745 (59%)	763 (62%)	770 (62%)	2278 (60%)
Kaposi Sarcoma	136 (11%)	115 (9%)	144 (12%)	395 (11%)
Eye	164 (12%)	106 (9%)	91 (7%)	361 (10%)
Breast	131 (10%)	141 (12%)	130 (10%)	402 (11%)
Prostate	97 (8%)	102 (8%)	108 (9%)	307 (8%)
TOTAL	1273 (100%)	1227 (100%)	1243 (100%)	3743 (100%)

(ZNCRO, 2011)

In addition, information obtained from Cancer Diseases Hospital showed that the cases of breast cancer referred for treatment are on the increase with a pattern of 71 cases in 2007, 116 cases in 2008, 79 cases in 2009 and 128 cases in 2010, (CDH, 2012).

Furthermore, information from the histology laboratory at the University Teaching Hospital revealed the following pattern of 168, 171 and 170 confirmed cases in 2009, 2010 and 2011 respectively.

In view of the above, the importance of IHC characterization of breast cancer in order to come up with more specific subtypes of breast cancer with their specific prevention and management cannot be overemphasized.

1.3 JUSTIFICATION

Recently, various techniques particularly for histology and gene expression profiling, have been increasingly used to help refine breast cancer classification and to assess prognosis and response to therapy. As the precise role of these newer techniques in the daily management of patients with breast cancer continues to evolve, it is clear that they have the potential to provide value above and beyond that provided by the traditional clinical and pathological prognostic and predictive factors which in turn have a major impact on the management of patients with breast cancer.

Since recent studies have shown that breast cancer is not a single disease with variable morphologic features and biomarkers, immunohistochemical characterization of breast cancer will help reveal that breast cancer is rather a group of molecularly distinct neoplastic disorders. Moreover, it may uncover new molecular signatures that could influence clinical care. The histological evaluation is essential to determine the most effective approaches to hormone and chemotherapy, if recommended.

Furthermore, understanding frequency of occurrence of specific breast cancer subtypes may facilitate breast cancer prevention, screening and treatment strategies tailored to the unique risk groups. This study therefore, seeks to characterize breast cancer and analyze the immunohistochemical profiles of P53, HER-2, VEGF and CK 5/6.

CHAPTER TWO

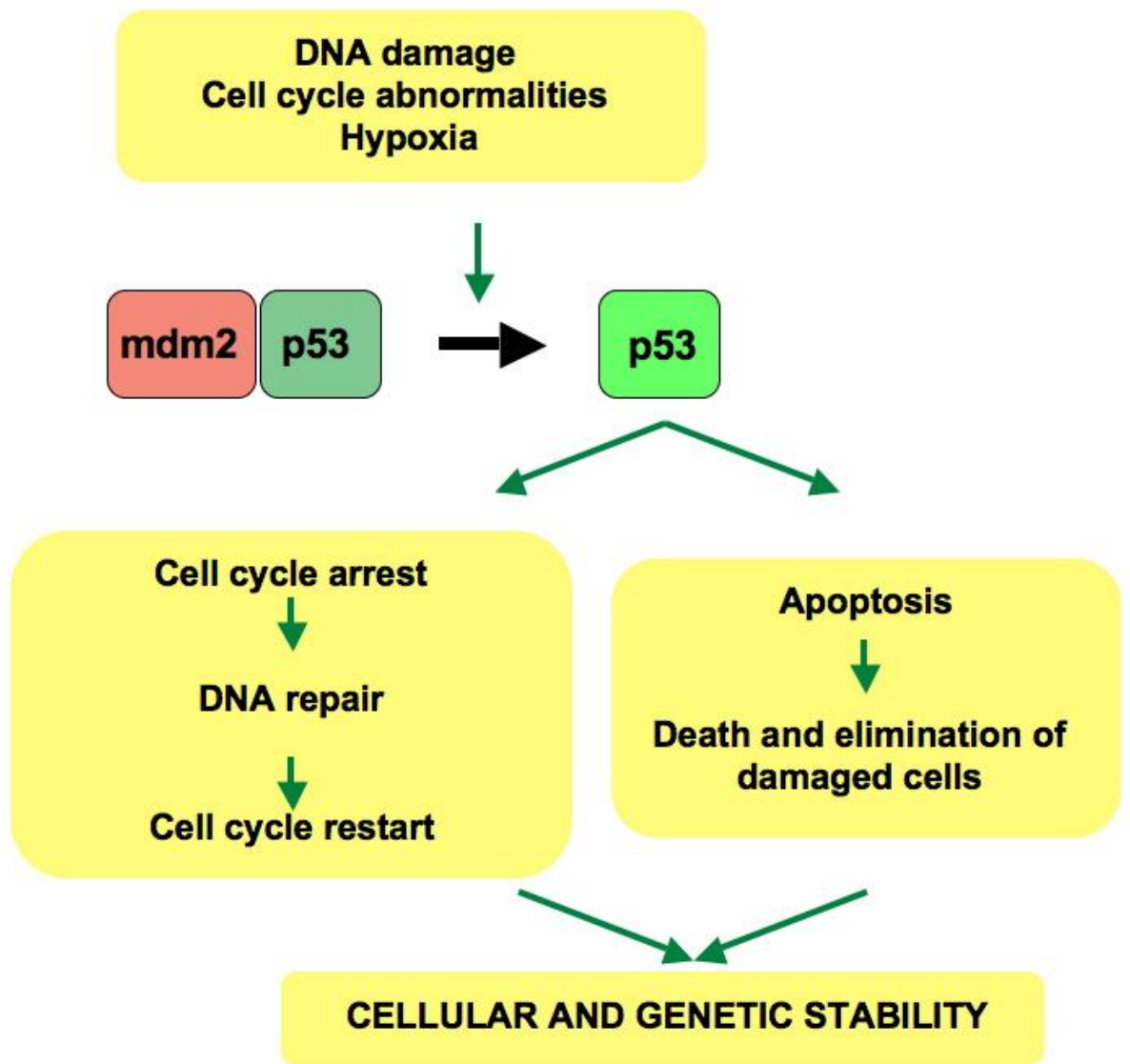
2.1 LITERATURE REVIEW

Breast cancer is a genetically and clinically heterogeneous disease and in order to organize and standardize the language, breast cancer classification systems have been developed of which histology and IHC are some of them. Literature reviewed in this chapter covers information on breast cancer histology as well IHC analysis. The literature reviewed on histology highlights different types of breast cancer as reported by other researchers. IHC information reviewed will provide insight on biomarkers detection. This technique is able to determine tissue constituents like proteins just to mention one. The technique identifies specific antibodies that can be visualized through staining. In this study, the proteins under consideration are p53, HER2, VEGF and CK5/6

2.1.1 P53

P53, also known as tumour protein (TP) or cellular tumour antigen, is a protein that in humans is encoded by the TP53 gene and is located on the short arm of chromosome 17. p53 gene is crucial in multicellular organisms because it regulates the cell cycle, therefore functions as a tumour suppressor preventing cancer. As such, p53 has been described as the guardian of the genome because of its role in conserving stability by preventing genome mutations. p53 becomes activated in response to stressors, including but not limited to DNA damage (induced by either UV, IR, or chemical agents such as hydrogen peroxide), oxidative stress and osmotic shock. p53 has many mechanisms of anticancer function and plays a role in apoptosis, genomic stability and inhibition of angiogenesis. In its anticancer role, p53 works through the following mechanisms: it can activate DNA repair protein when DNA has sustained damage. Thus, it may be an important factor in ageing. It can arrest growth by holding the cell cycle at the G1/S regulation point on DNA damage recognition (if it holds the cell here long enough, the DNA repair proteins will have time to fix the damage and the cell will be allowed to continue the cell cycle). Finally, p53 can also induce-programmed cell death if DNA damage proves to be irreparable.

Figure 1: The role of p53 in cancer development



In normal cells, p53 is activated by its negative regulator mdm² as shown in the figure above. Upon DNA damage, or exposure to other stresses various pathways will lead to dissociation of p53 and mdm² complex. Once activated, p53 will induce cell cycle arrest to allow either repair or survival of the cell or apoptosis to discard the damaged cell. If the *TP53* gene is damaged, tumor suppression is severely reduced.

People who inherit only one functional copy of the *TP53* gene will most likely develop tumors in early adulthood, a disorder known as Li-Fraumeni syndrome which is characterized by a high incidence of multiple early cancers, including breast tumours (Ferrara, 2002).

2.1.2 HER2

Human epidermal growth factor receptor 2 (HER2) is a gene that makes HER2 proteins which are receptors on breast cells. Normally, HER2 receptors help control how a healthy breast cell grows, divides, and repairs itself. However, in about 25% of breast cancers, the HER2 gene doesn't work correctly and makes too many copies of itself (known as HER2 gene amplification). All these extra HER2 genes tell breast cells to make too many HER2 receptors (HER2 protein over-expression). This makes breast cells grow and divide in an uncontrolled way. Breast cancers with HER2 gene amplification or HER2 protein over-expression are called HER2-positive in the pathology report. HER2 positive breast cancers means HER2 genes are overproduced, causing the affected cells to grow and divide quickly creating a cancer. HER2 positive breast cancers are therefore associated with increased disease aggressiveness, recurrence and poor prognosis and therefore, HER2 is one such gene that can play a role in the development of breast cancer (Folkman, 1995).

2.1.3 VEGF

Vascular endothelial growth factor (VEGF) is a signal protein produced by cells that stimulates vasculogenesis and angiogenesis. It is part of the system that restores the oxygen supply to tissues when blood circulation is inadequate. VEGF's normal function is to create new blood vessels during embryonic development, new blood vessels after injury, to muscles following exercise, and new vessels (collateral circulation) to bypass blocked vessels. Angiogenesis, the formation of new blood vessels, is essential for the development, progression, and metastasis of breast cancer (Folkman 1995, Ferrara 2002).

Angiogenesis is regulated in part by vascular endothelial growth factor (VEGF), the most potent endothelial cell regulator of vascular permeability and is the target for numerous biologic therapies in breast cancer and other malignancies.

In the absence of angiogenesis, tumors cannot grow beyond 1–2 mm³ in size (Bergers & Benjamin 2003). Vascular endothelial growth factor (VEGF) is a primary stimulus of angiogenesis in tumors and functions through binding VEGF receptor-2 expressed on endothelial cells (Ferrara *et al.* 2003). Two secretory forms of VEGF are typically produced by endothelial and breast tumor cells: VEGF₁₆₅ and VEGF₁₂₁ (Folkman 1995, Ferrara 2002). VEGF also acts as a survival or an anti-apoptotic factor and has been shown to induce Bcl-2 in endothelial cells as well as in breast cancer cells (Pidgeon *et al.* 2001). Bcl-2 is an anti-apoptotic protein that functions in cell survival, tumor progression, and drug resistance, and is induced in response to VEGF in breast cancer cells. Interestingly, clinical studies have shown that tumors with high levels of VEGF fail to respond to hormone therapy (Foekens *et al.* 2001, Manders *et al.* 2003) suggesting that VEGF production might be involved in anti-hormone resistance. Among the factors that can trigger angiogenesis, the lack of oxygen (hypoxia) is of special importance. All solid tumors eventually activate angiogenesis in order to overcome lack of oxygen and nutrients after reaching a certain burden. One of the most important mediators of hypoxia-activated angiogenesis is the vascular endothelial growth factor (VEGF-A), produced by tumor cells after sensing low oxygen levels. Once released, VEGF may elicit several responses including cell survival, movement, or further differentiate. Hence, VEGF is a potential target for the treatment of cancer. Without an independent blood supply, tumors must rely on diffusion to obtain oxygen and other nutrients, and typically cannot grow more than 2 mm³ in size. Thus, a growing tumor without sufficient vasculature will be hypoxic—that is, lacking in oxygen-areas. In response to hypoxic conditions, tumors secrete vascular endothelial growth factor (VEGF) in order to recruit new vasculature, which then provides a supply of oxygen.

2.1.4 CK5/6

Cytokeratins are intermediate filament proteins that reflect state of tissue growth, differentiation and functional status. Its expression is associated with triple negative breast cancer. Triple-negative breast cancer (TNBC) is a heterogeneous subgroup of breast cancer characterized by the lack of estrogen receptor (ER), progesterone receptor (PR) and the human epidermal growth factor receptor 2 (HER2) expressions.

This subgroup of the disease tends to have aggressive clinical behavior, high frequency of metastasis and lack of response to current hormonal or targeted therapies. It is also associated with young age.

Li et al, 2003 in a study entitled Trends in Incidence Rates of Lobular and Ductal Breast Carcinoma, reported that histological types of breast cancer tumors differed significantly by age at diagnosis. The proportion of ductal carcinomas, the most common type (81.4%), was rather constant across age groups, but tended to be slightly less common in women diagnosed below age 30 years and above age 60 years. The proportion of lobular tumors, accounted for 6.3% of all cases, increased markedly with increasing age. Similar findings were reported by Dixon et al in a study called Lobular Carcinoma of the Breast.

In another study to determine breast cancer histology conducted in Kumasi Ghana, results revealed that ductal carcinoma was the most common (78%). Overall 40% were grade 3, but 48% of ductal carcinomas were grade 3. Estrogen receptor was positive in 60% overall and in 51% of ductal carcinomas. HER2/neu was overexpressed in 11% (Mbonde et al, 1998).

A study conducted in Nigeria showed that ductal carcinoma constituted the majority of the breast cancers diagnosed (82%).

Other subtypes of breast cancer such as infiltrating medullary ductal carcinoma, lobular carcinoma, malignant connective tissue tumor, infiltrating mucinous ductal carcinoma, infiltrating papillary ductal carcinoma, as well as ductal carcinoma in situ, malignant phylloide tumor, infiltrating squamous cell carcinoma, and carcinoid tumor represented a small fraction of the diagnosed breast diseases (Adebamowo et al, 2008)

In Kenya, similar findings were obtained in a study where the majority of the patients had ductal carcinoma (91.5%) followed by mucinous carcinoma (5.2%), lobular carcinoma (3%) and in situ ductal carcinoma (0.3%) (Nyagol et al, 2006).

In another retrospective study to determine breast cancer histology in Bugando in Tanzania, results revealed that of all patients, 91.5% had ductal carcinoma, 3% had lobular carcinoma and 5.2% had mucinous carcinoma, only one patient had in situ ductal carcinoma. 56.4% of the patients had histological grade 3, 42.1 % grade 2 and 1.5% grade 1.

On the other hand, Lowery et al found that epidermal growth factor receptor (EGFR) may be important in the etiology of breast cancer and may represent a possible therapeutic target. He also found that p53 was mutated in most cases of breast cancer. His findings were in line with those by Kendal et al, 2004 who found that HER2 and VEGF were overexpressed and p53 was mutated in most cases of breast cancer.

Perou et al (2000) and Sorlie et al (2003) were the first to show that breast carcinomas can also be subdivided based on gene-expression analysis, (Prat et al 2011). Their studies demonstrated that the expression profiles of breast cancer showed a systematic variation and allowed the classification of breast cancer into five main groups luminal A and B, normal breast-like, ERBB2 (HER2) and basal-like breast carcinomas (Perou et al., 2000; Sorlie et al., 2001; Rouzier et al., 2005; Reis-Filho et al., 2006).

They discovered that breast carcinomas could be subdivided into several subgroups that differ in their overall gene-expression profile.

The largest difference in overall gene-expression profile was observed between tumours that are ER positive and those that are ER negative. These ER-negative tumours were further sub-divided into tumours with gene characteristics of HER2-positive tumours, normal breast tissue and basal epithelial/myoepithelial cells.

The study further revealed that high levels of either HER2 gene amplification or protein expression tend to result in a poorer breast cancer prognosis. Therefore, a monoclonal antibody therapy was developed to counter the effects of HER2, (trastuzumab), and its use has been shown to reduce rates of recurrence and mortality in HER2 positive early stage breast cancers.

The luminal and basal clusters were defined based on their expression of keratin genes, and were not specifically associated with epithelial cell lineages. The luminal group formed the largest cluster, and the expression profiles of these tumours were characterized by the expression of estrogen receptor. Tumours which were negative for ESR1 expression segregated into two distinct clusters, basal-like and ERBB2+. The basal gene expression cluster expressed genes which are considered characteristic of basal epithelial cells including keratin 5/6, keratin. The ERBB2+ cluster expressed genes associated with expression of the Erb- B2 oncogene. This was emphasized by the fact that 70 – 80% of the ERBB2-positive and basal tumours, and 67% of luminal B+C tumours harbored mutations.

In another study conducted by Rakha et al, 2009 in Nigeria to characterize breast carcinomas, results showed that the signatures for ER, HER2, and proliferation could be used to group the tumors into breast cancer subtypes analogous to those described by Perou et al and Sorlie et al which are luminal A, luminal B, HER2, and basal-like. In addition, proliferation genes like VEGF were found to be the common driving force behind all of the prognostic signatures.

Another study conducted in Houston, Texas, USA to examine comprehensive gene-expression patterns of breast cancer, results revealed that P53 was mutated in most breast cancer tissues and HER-2 was overexpressed (Rouzier et al, 2005).

By examining gene expression profiles using immunohistochemistry, Sorlie et al categorized breast carcinoma into five different groups that were associated with different clinical courses. One of these groups was designated basal-like (because its gene expression profile was similar to normal breast basal cells), and represented 19% of tumors in the study group (of >300 cases). These basal-like breast carcinomas were typically negative for ER and PR, and also negative for HER-2 over-expression (or HER-2 gene amplification).

Furthermore, they assessed their expression for either cytokeratin 5/6 or EGFR (HER-1) where they were able to identify 16 of the 21 basal-like tumors, giving sensitivity for basal-like tumors of 76% and a specificity of 100%. One of these groups was designated "basal-like" (because its gene expression profile was similar to normal breast basal cells), and represented 19% of tumors in the study group (of >300 cases). These basal-like breast carcinomas were typically negative for ER and PR, and also negative for HER-2 over-expression (or HER-2 gene amplification). Follow up data on this group of immune-histochemically-defined basal-like tumors confirmed the worse prognosis of this group. The criteria for interpreting the stains were as follows: ER positive = nuclear staining (weak or strong) in any invasive tumor cells.

HER-2 positive = strong membrane staining on >20% of invasive tumor cells (equivalent to a 3+ Herceptest score; cases with a Herceptest score of 0, 1+, or 2+ are all considered negative). Cytokeratin 5 positive = any (weak or strong) cytoplasmic staining of invasive tumor cells. EGFR positive = any (weak or strong) cytoplasmic staining of invasive tumor cells (Nielsen et al, 2004). Multiple immunohistochemical markers (that stain normal breast basal cells) have been used by different investigators to recognize basal-like differentiation, including cytokeratin 5 (or cytokeratin 5/6, which is diagnostically equivalent to cytokeratin 5), cytokeratin 14, cytokeratin 17, and EGFR. This group included 21 cases that showed gene expression profiles of basal-like tumors.

In a profiling study of invasive breast carcinoma carried in North Carolina USA, immunohistochemical stains for ER, HER2, EGFR, p63, CD10, cytokeratin 8/18, vimentin, and cytokeratin 5/6 were performed on 18 basal-like, 16 luminal, and 12 HER2+/ER- invasive breast carcinomas identified by gene microarray analysis.

The basal-like tumors were ER- (0/18, 0%) and HER2- (0/18, 0%), while the luminal subtype tumors were ER+ (18/18, 100%) and HER2- (0/18, 0%), and the HER2+/ER- subtype tumors were ER- (0/12, 0%) and HER2 over expressed (11/12, 92%) (Kapp et al, 2006).

The rate of EGFR expression seen in the basal-like (13/18, 72%) tumors was significantly higher than that observed in luminal tumors (0/23 0%). Most HER2+/ER- (7/12, 58%) subtypes also expressed EGFR; thus, in this study, EGFR expression was seen exclusively in the basal-like and HER2+/ER- subtypes (Galukande et al, 2008) .

2.2 RESEARCH QUESTION

2.2.1 What are the histological types of breast cancer at UTH?

2.2.2. What are the immunohistochemical (IHC) profiles of breast cancer at UTH?

2.3 GENERAL OBJECTIVE

To characterize the histology of breast cancer and their immunohistochemical profiles at UTH.

2.3.1 Specific Objectives

- To histologically classify breast cancer
- To analyze IHC profiles of HER2, p53, VEGF and CK 5/6 in breast tissues which can be used to distinguish between the subgroups.

CHAPTER THREE

3.1 METHODOLOGY

3.1.1 The study design, site and period

This was a laboratory based cross-sectional study and was done at the University Teaching Hospital (UTH), department of Pathology and Microbiology (Histopathology laboratory) in Lusaka, Zambia for a period of six months. The histopathology component of this study (tissue sectioning, H & E staining, cover slipping and microscopic examinations) was done in the UTH histopathology laboratory under the supervision of a trained pathologist.

3.1.2 The sample size and sampling frame

A convenient sampling method was used to select the specimen sample size of forty four (44) formalin fixed-paraffin embedded tissue blocks (FFPE) of breast tissue diagnosed with breast cancer on histology for the year 2012 for this study. The specimens were from patients between 21 and 70 years old. Similar sample sizes were used in other studies: Yemin et al, 2008 used 42 samples in his study entitled Immunohistochemical Characterization of Subtypes of Breast Carcinoma. In Australia, Benjamin et al, 2000, used 45 samples in a study called Characterization of Columnar Cell Lesions of the Breast.

3.1.3 Materials and Methods for Histology

3.1.3.1 Specimen Collection

The formalin fixed-paraffin embedded breast cancer specimens were collected from the histopathology archives. All examinations were carried out on formalin fixed paraffin embedded (FFPE) tissue blocks.

A convenient sampling method was used to select the 44 specimens sample size for this study and the age range was between 21 and 70 years.

3.1.3.2 Specimen Labeling

Each archival breast tissue specimen was given a new identification code and number for easier identification. The letters “BC” (which stand for breast cancer) plus a three digit numbering system (ie 000) was used. Hence specimens were labeled like BC 031, BC 032 etc.

3.1.3.3 Specimen Sectioning

Before the specimens were sectioned on the microtome machine, the blocks to be sectioned were placed face down on an ice-cold plate for 20 minutes. The water bath was also turned on and the temperature was set at 35-37⁰C. The paraffin block was then placed in the block holder of the microtome machine and advanced it closer to the microtome blade. The dial was set to cut 5-10 μ m sections. The blade was angled 4-6⁰. The rough trimming of the paraffin section was done until a complete section was seen in the block. By utilizing a clean section of the blade, a ribbon was obtained. The ribbon was picked by the forceps and transferred to the water bath. The ribbon was laid on the water bath to allow the sections to stretch for a few seconds. The sections were then carefully separated and each section picked on a glass slide. The sections were picked at an angle to allow the water to exit the slide and section. The slide sections were allowed to drain for a few minutes before putting the specimen slide on the hot plate. To remove some more water from the tissue section, the tissue section was put on the hot plate. The glass slides were then placed in a warm plate for about 15 minutes to help the section adhere to the slide.

3.1.3.4 Ehrlich’s Hematoxylin and Eosin (H & E Stain) Staining

In order to facilitate penetration of the water based H and E stain, mounted specimen sections were softened using ethanol and rehydrated to accept the stain.

Sections were taken to water, that is deparaffinized in two changes of xylene (2 minutes each), washed in 2 changes of absolute alcohol (2 minutes each) then in water for 2 minutes. The slides were then stained with Ehrlich's Hematoxylin solution for 25 minutes. After staining the slides were washed in running tap water for 5 minutes then differentiated in 1% hydrochloric acid in 70% alcohol (1% acid alcohol) for 15-30 seconds. The slides were further blued in running tap water for 10 minutes and counter stained in 1% aqueous eosin for 2-5 minutes. Finally , the slides were rinsed in 95% alcohol (10 dips), dehydrated in 2 changes of absolute alcohol for 2 minutes in each, cleared in 2 or 3 changes of xylene for 2 minutes each.

3.1.3.5 Cover Slipping

The slides were placed on a clean horizontal bench surface. A drop of DPX Mountant was applied to each tissue section and at the far end of the slide away from the frosted end. The cover-slip was then carefully applied by placing one end of the slip on top of the drop of DPX Mountant at the far end of the slide. Slowly and gently the cover slip was rolled down the side, only using enough pressure to allow the medium to spread evenly. The slides were then placed flat on the bench for 2 hours to eliminate bubbles under the cover slip. When the slides were dry they were removed from the bench and ready for microscopic examination.

3.2 Analyzing the IHC of *HER2*, *p53*, *CK5* and *VEGF*

3.2.1 Human Epidermal Growth Factor Receptor 2 (HER-2)

Breast cancer sections were de-waxed and antigen retrieval performed in citrate buffer with pH 6.0 for 20 minutes. Pre-diluted anti-HER-2/*neu* monoclonal antibody CB11 were used with ready-to-use detection kits according to the manufacturer's specifications to detect HER-2/*neu* . Each antigen-retrieved slide was labeled with the appropriate bar code specifying the staining procedure.

The sequence of staining procedures carried out included application of inhibitor solution to decrease endogenous peroxidase activity (4 minutes, 37°C), application of primary antibody (CB11, prepared by the manufacturer at approximately 0.63 µg/mL, 32 minutes, 37°C), application of biotinylated secondary antibody (8 minutes, 37°C), application of avidin/streptavidin-enzyme conjugate (8 minutes, 37°C), and application of diaminobenzidine chromogenic substrate.

The immunostaining was scored as 0, 1+, 2+, and 3+, with 2+ and 3+ considered over-expression (Reference N^o. AB 405303, expiring in 2017).

3.2.2 p53

Immunohistochemical measurement of p53 protein levels and the determination of the degree of staining was done using (clone B p53-12) Reference number 628201/25 from UK expiring 2017). Thin sections of formalin-fixed, paraffin-embedded tissues were stained with the p53-specific monoclonal antibody DO-1 (p53 [Ab-6], Oncogene and a second layer of biotinylated rabbit anti-mouse immunoglobulins followed by peroxidase-conjugated streptavidin biotin. Slides were then incubated with primary antibody overnight. Immunostaining was assessed using a microscopy. The degree of staining was scored based on a scale of 0 to 7. Sections with 0 staining were classified as non-staining, and a score between 2 and 4 was classified as weak staining. Sections with a score of 5 and above were classified as showing moderate to strong staining and were considered to be positive for p53 protein. (Nuclear staining equal to or greater than 10% was considered positive while less than 10% staining was considered negative).

3.2.3 Cytokeratins 5/6 (CK 5/6)

Four µm thick sections were cut from formalin-fixed paraffin-embedded blocks containing representative tumor samples. Sections were dewaxed in toluene and rehydrated. Endogenous peroxidase was blocked by immersion in 0.3% hydrogen peroxide for 20 minutes. Sections were then rinsed in Tris buffer. Antigen retrieval was performed with EDTA, pH 8.0), and heating for two 5 minutes periods in a microwave oven at 750 W, followed by cooling at room temperature for 20 minutes.

The primary antibody was incubated overnight at 4°C, followed by a commercial streptavidin-biotin-peroxidase technique. Diaminobenzidine (0.05% for 10 minutes at room temperature) was used as chromogen. Staining was done and cytoplasmic immunoreactivity was later assessed (reference No: AB: 17068, expiring in 2017).

Cut-off points

Negative means no staining seen in cancer cells

Positive-weak or strong staining

3.2.4 VEGF

Archived formalin fixed and paraffin embedded tissues were used. Four-µm-thick sections were mounted onto Super frost Plus-coated slides and dried for 60 minutes at 65 degrees Celsius. Sections were then de-waxed in Tissue-Tek Tissue-Clear Xylene Substitute and rehydrated through graded series of ethanol and rinsed in water. Endogenous peroxidase activity was blocked with 3% hydrogen peroxidase for 10 minutes. Heat-induced antigen retrieval was performed in a microwave oven in 10 mM Tris/EGTA (pH = 9) by heating for 10 minutes followed by 15 minutes of boiling. Sections were cooled for 15 minutes at room temperature and rinsed in Tris-buffered saline (TBS) with 0.05% Tween 20 for at least 5 minutes. Sections for incubation in anti VEGF-B were additionally treated with 0.5% casein in TBS for 10 minutes to block non-specific binding sites. The individual tissue sections were incubated with primary antibody for 30 minutes: anti-VEGF-A, rabbit polyclonal antibody, dilution 1:250, anti-VEGFR-1, rabbit polyclonal antibody, dilution 1:100 (Ab-1, RB-1527-P, or anti-VEGF-B, rabbit polyclonal antibody, dilution 1:250 (H-70, SC-13083). Detections were performed using Super Sensitive Polymer-HRP IHC Detection System Super Enhancer link which was added for 20 minutes and polymer-HRP for 30 minutes followed by visualization with DAB chromogen for 12 minutes. Sections were rinsed in water, and 0.5% cobber sulfate in TBS was added to enhance the staining intensity. Between incubations, the sections were washed several times in TBS buffer.

Finally, sections were counterstained with hematoxylin, dehydrated, and cover slipped. The cytoplasmic staining intensity of invasive tumor cells were scored using the following scoring technique: an overall intensity score with 3 levels 1 = weak or no staining; 2 = moderate staining; and 3 = strong staining (reference No: AE: 130-10059-200).

3.3 Data Analysis

Findings were analyzed using statistical software SPSS for Windows, Version 20. Age, histology and immunohistochemical results were variables under consideration. The differences in the distribution of the study variables were evaluated by the use of Pearson Chi-square and when necessary, by Fisher's Exact test. A P-Value of 0.05 was used to indicate statistical significance.

3.4 Utilization of findings

The results from this study will be used for furthering understanding of the natural history of breast cancer and this may in due course provide insight into response to therapy and prognosis thereby improving the current management modalities.

3.5 Validity

Validity was maintained by ensuring that the reagents used in this study were not expired (Vectastain Kit-PK 60100, expiring in 2017). The study diagnosis was compared to the reported clinical diagnoses which were similar.

3.6 Reliability

The same data information sheet and reagents were used to indicate the histology and IHC profiles present in tissues.

3.7 Ethical considerations

Ethical clearance was sought from the University of Zambia Biomedical Research Ethics Committee (UNZABREC) (Appendix 2). Permission to conduct a study was obtained from the Senior Medical Superintendent at UTH.

Anonymity and confidentiality were maintained by ensuring that no name but only serial numbers appeared on the data information sheet. After data analysis, all used data information sheets were kept under lock and key and no one had access to the completed data sheets apart from the researcher. Specimens were not identified by name but by code.

CHAPTER FOUR

4.1 RESULTS

Data was presented and analyzed using the following tables:

Age frequency of participants, histology and immunohistochemical results.

Figure 2: Age frequency participants (n = 44)

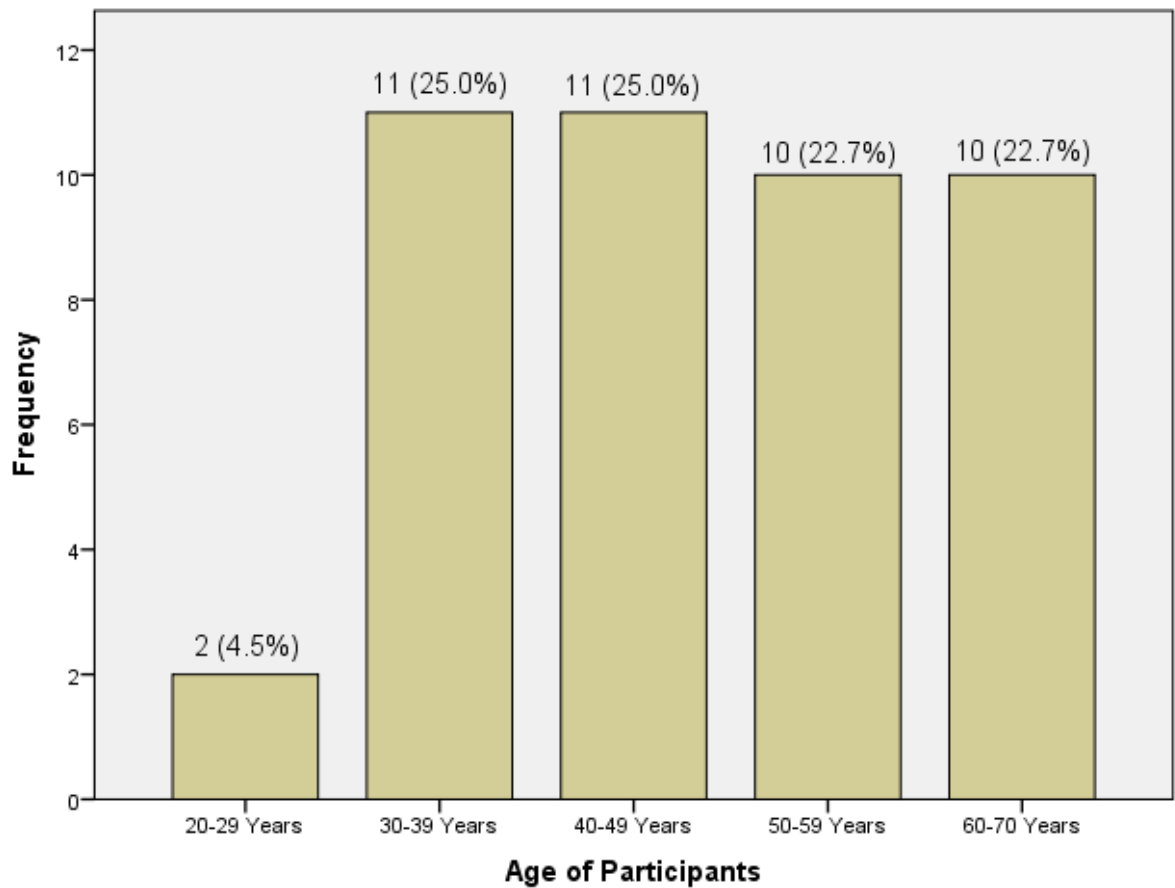


Figure 2 shows that breast cancer was more prevalent in the samples from patients that were aged between 30-49 years than in those that were 50 years and above.

Figure 3: Histological types of Breast Cancer (n = 44)

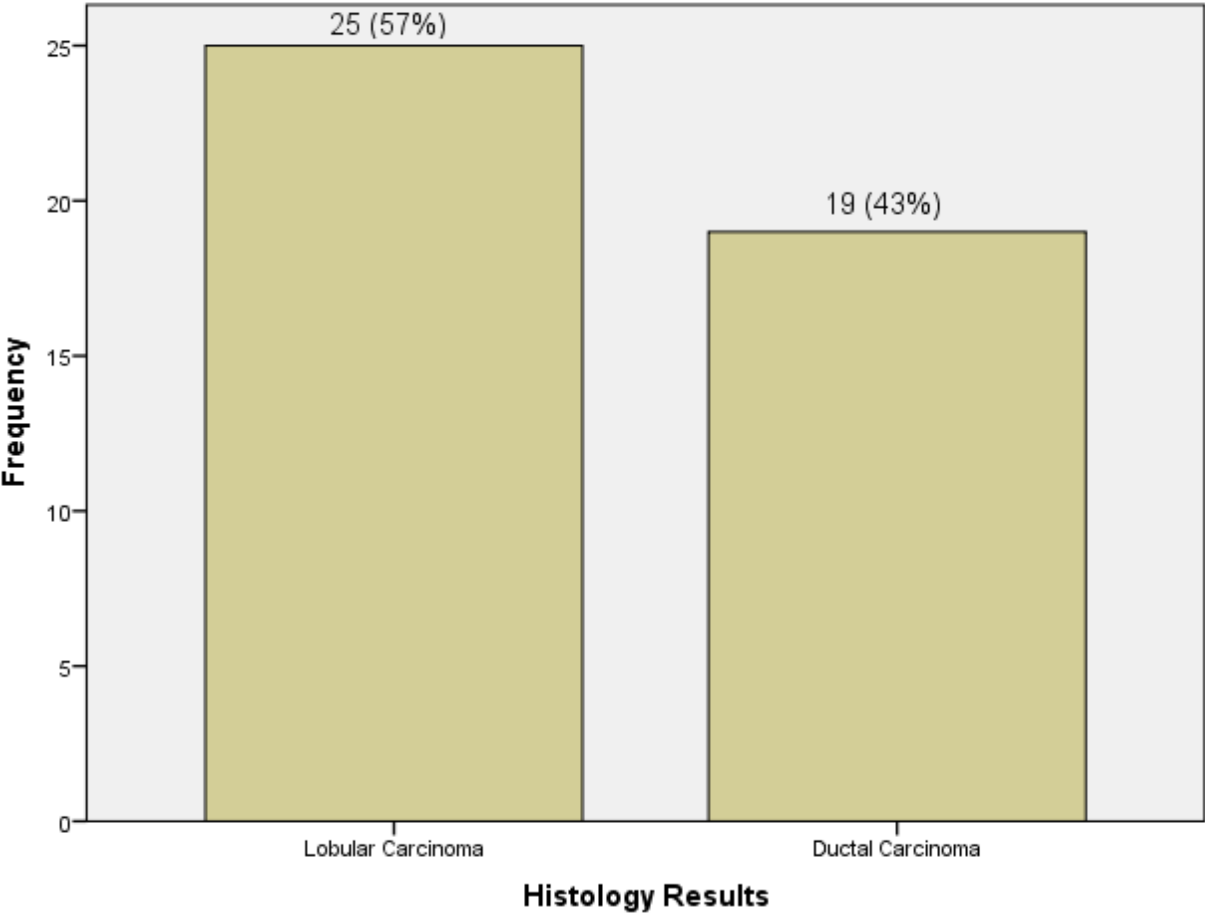


Figure 3 shows that there were 2 histological types of breast cancer of which lobular carcinoma was more predominant in indigenous black Zambians.

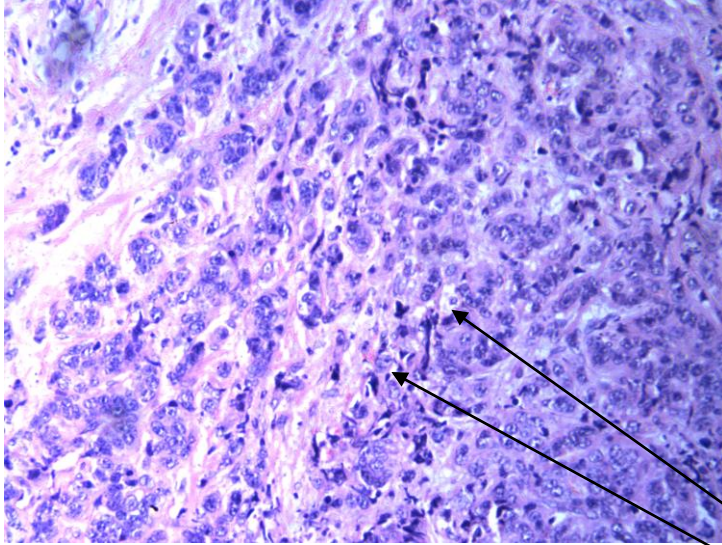


Figure 4: A positive lobular carcinoma of the breast on histology

Non cohesive cells
individually dispersed

Figure 5: Histology results by age (n = 44)

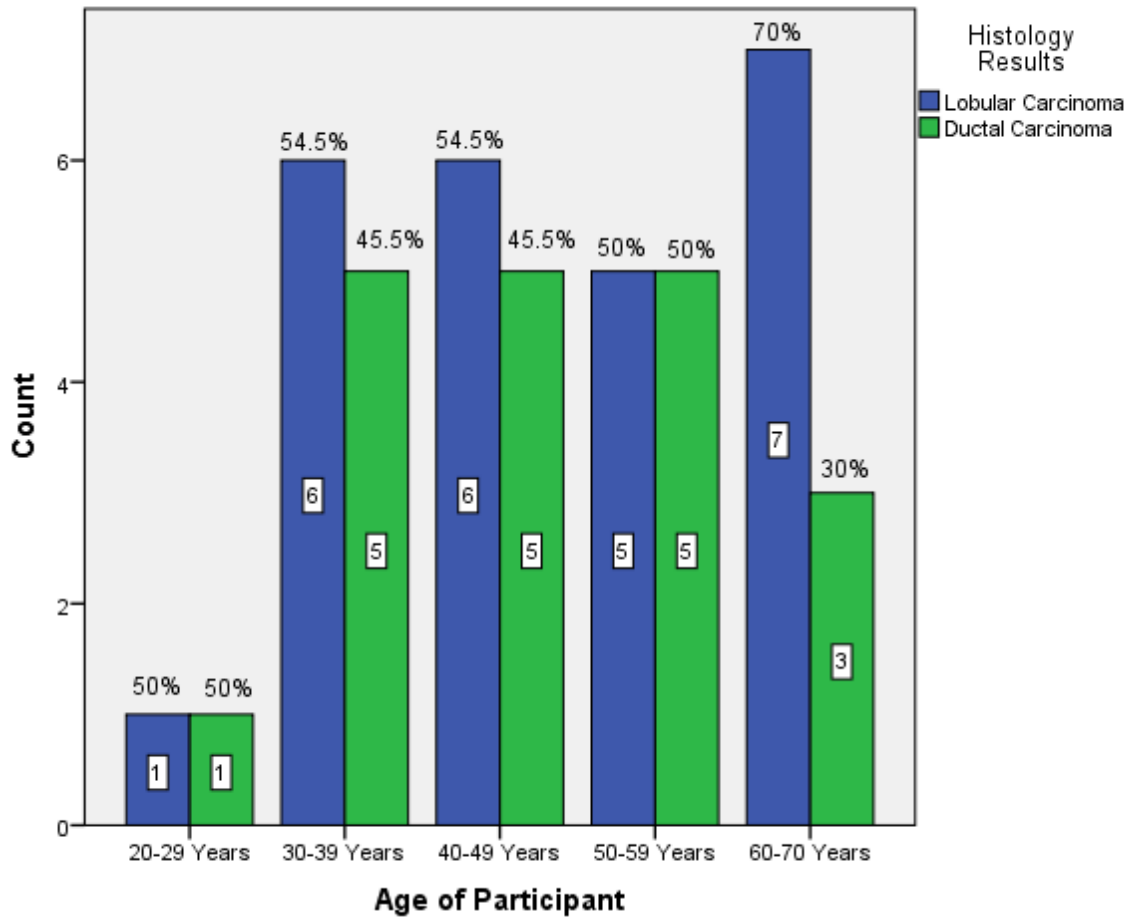


Figure 5 above shows that of the 2 histological types, lobular carcinoma was more common than ductal carcinoma in both the young and old women with breast carcinoma (Fisher's Exact Test: P=0.0912)

Table 2: Immunohistochemistry of p53 (n = 44)

P₅₃	Frequency	Per cent
Negative	2	4.5
Positive	42	95.5
Total	44	100

Table 2 above illustrates that p53 was overexpressed in the majority of tissues with breast cancer.

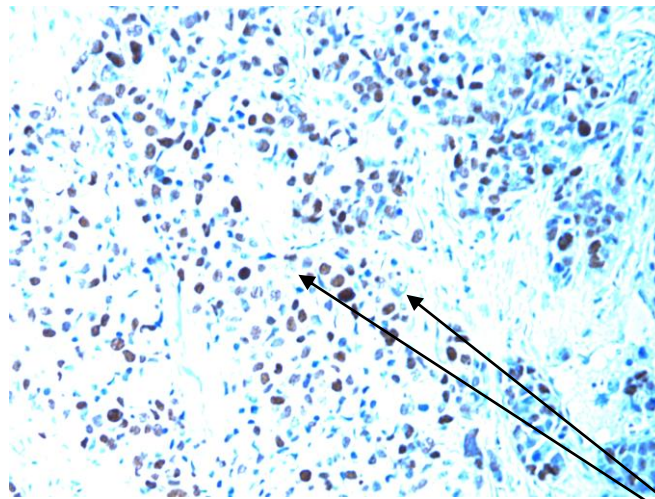


Figure 6: A positive p53 result

Positive nuclear stained cells (p 53)

Table 3: Immunohistochemistry of HER2 (n = 44)

HER2	Frequency	Percent
Negative	26	59.1
Positive	18	40.9
Total	44	100

The table above showed that 2/3 of breast cancer did not express HER2 proteins.

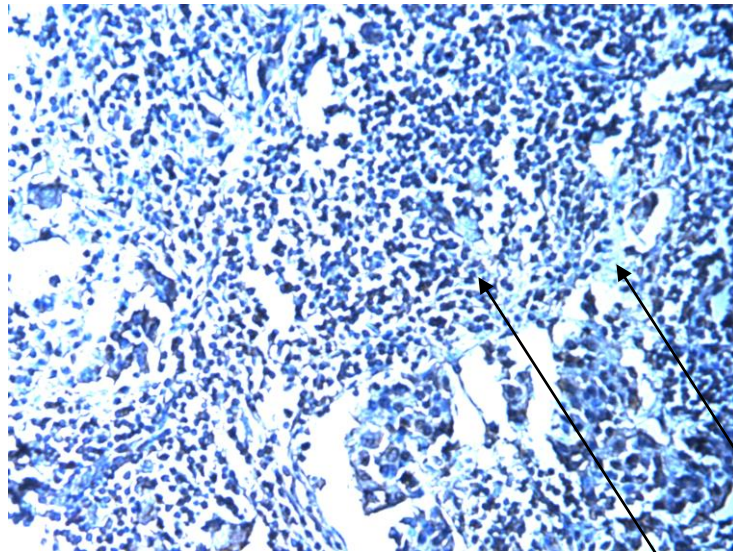


Figure 7: Positive HER2

Diffuse circumferential membrane staining (chicken wire staining pattern)

Table 4: Immunohistochemistry of VEGF (n = 44)

VEGF	Frequency	Per cent
Negative	9	20.5
Positive	35	79.5
Total	44	100

Table 4 shows that VEGF was much more expressed by breast cancer.

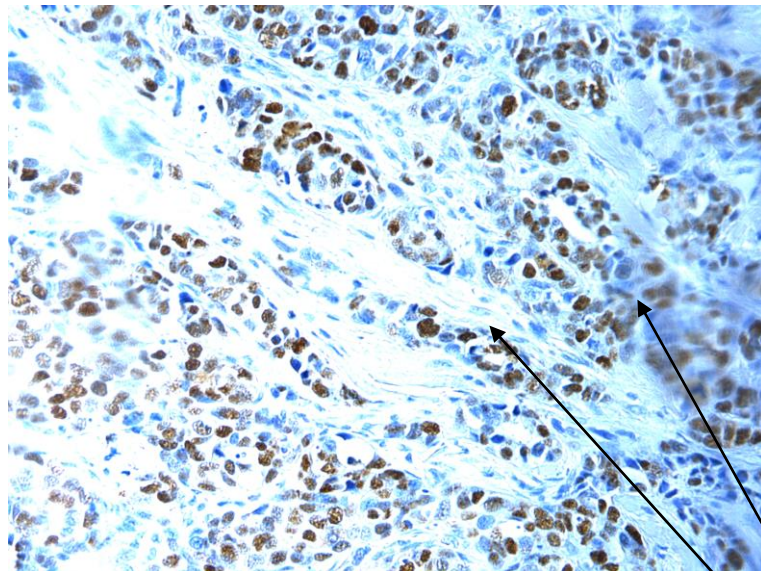


Figure 8: Positive VEGF

Positive
Cytoplasmic
staining of
cancer cells

Table 5: Immunohistochemistry of CK5/6 (n = 44)

CK5/6	Frequency	Per cent
Negative	23	52.3
Positive	21	47.7
Total	44	100

In the table above, almost ½ of breast cancer tissues expressed CK5/6 proteins.

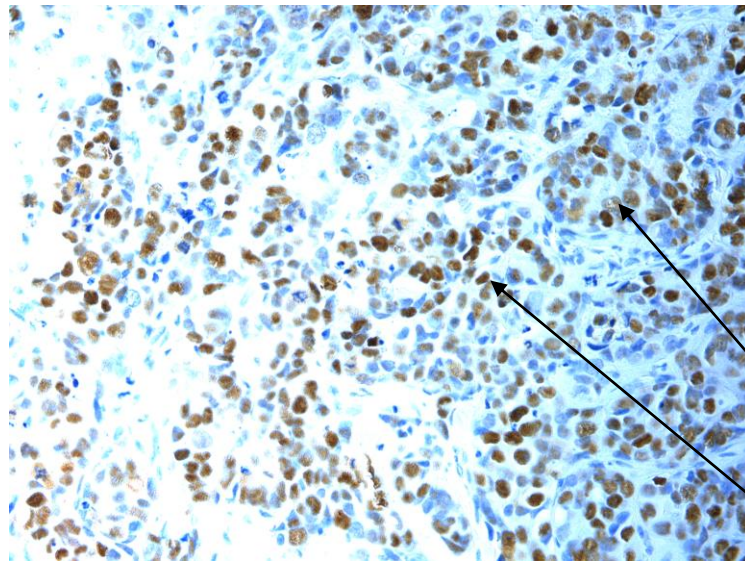


Figure 9: Showing a positive CK5/6 result

Positive
cytoplasmic
staining in
cancer cells

Figure 10: Histology results by Immunohistochemistry-p53 test (n = 44)

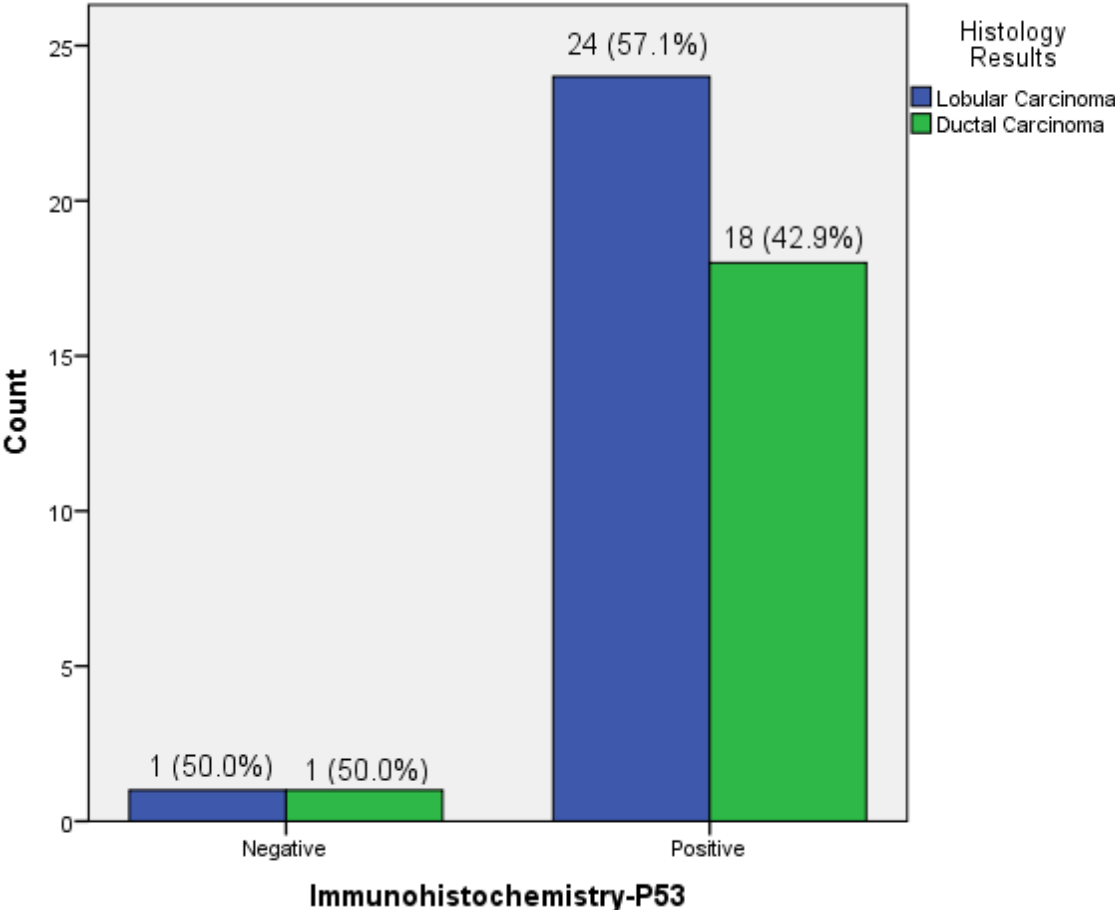
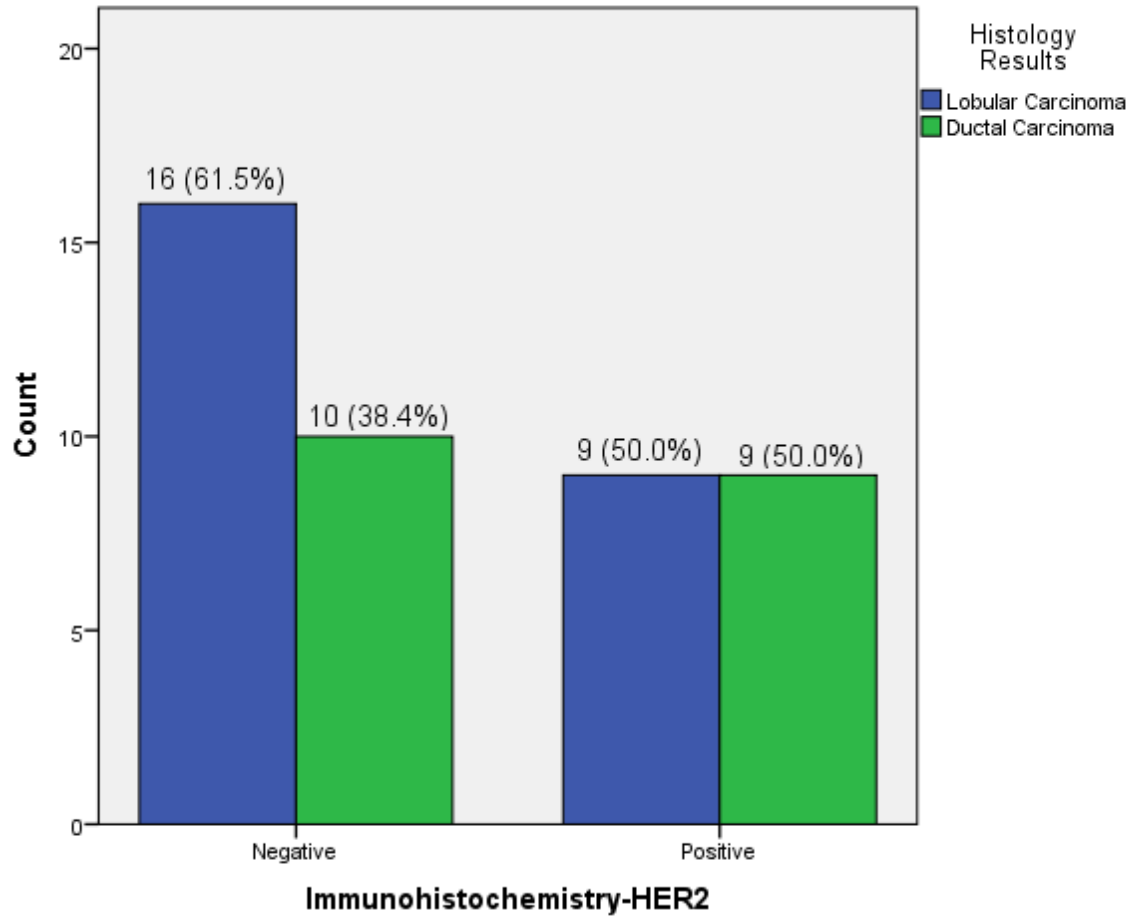


Figure 10 shows that p53 protein was more expressed by lobular than ductal carcinoma. (Fisher’s Exact Test, P = 0.001).

Figure 11: Histology results by Immunohistochemistry-HER2 Test

(n = 44)



The figure above shows that HER2 was equally expressed in both lobular and ductal carcinomas.

(Pearson Chi-Square $P = 0.027$).

Figure 12: Histology results by Immunohistochemistry-VEGF Test (n = 44)

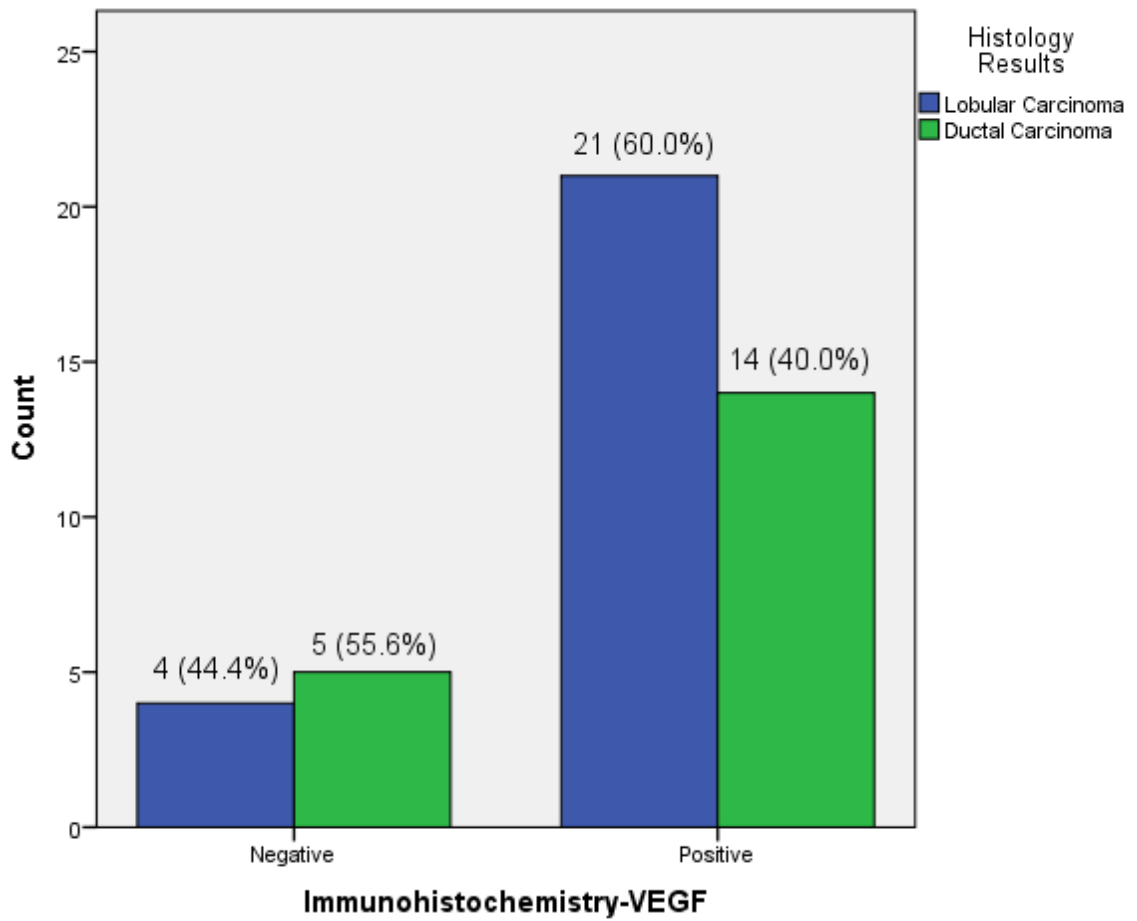
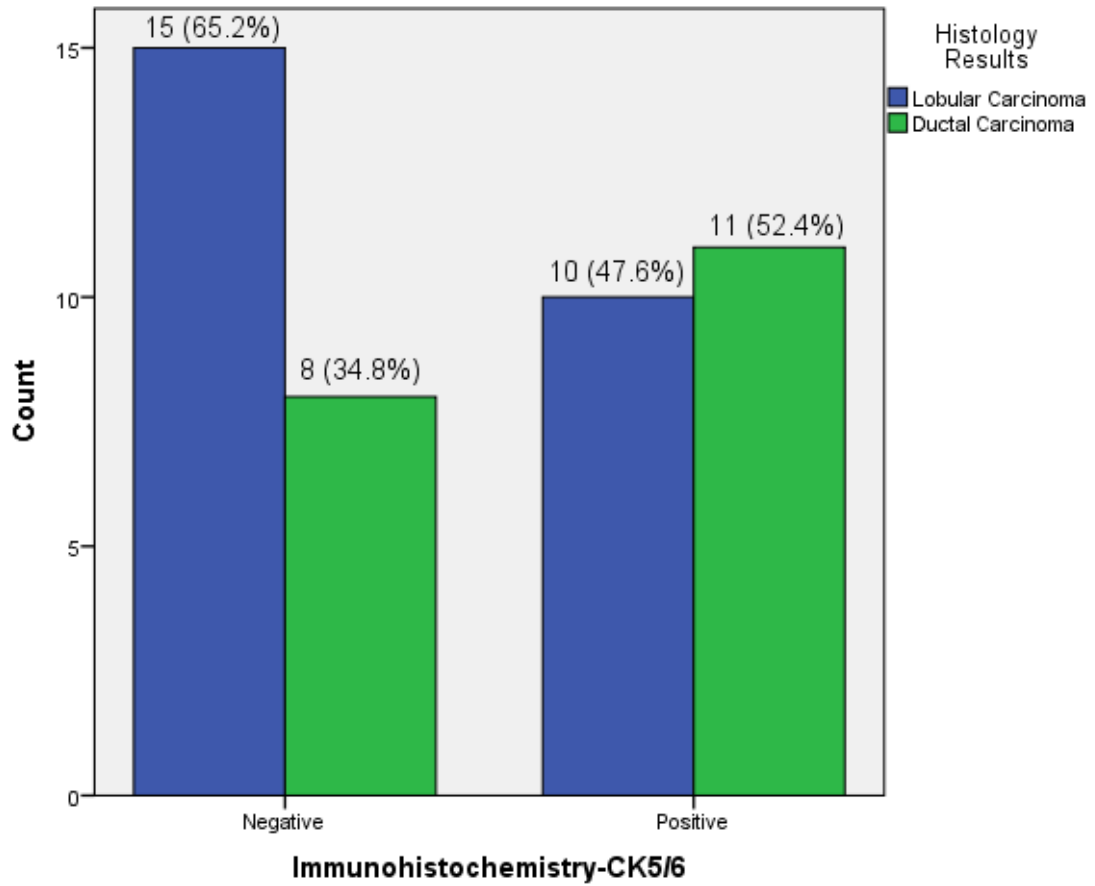


Figure 12 above shows that lobular carcinoma expressed more VEGF than ductal carcinoma. (Fisher's Exact Test, P = 0.036).

Figure 13: Histology results by Immunohistochemistry CK5/6 (n = 44)



In the figure above, CK5/6 were more expressed by ductal than lobular carcinoma. (Chi-square - $p = 0.023$).

CHAPTER FIVE

5.1 DISCUSSION

Breast cancer is a heterogeneous group of disease that can be characterized into clinically, morphologically and biologically distinct subgroups. By histology and Immunohistochemistry (IHC), breast cancers can be classified into subtypes. The current study examined the histology and IHC patterns of breast cancer at the University Teaching Hospital (UTH). Age, histology and IHC results were variables under analysis. The histological phenotypes were characterized by age and IHC by expression of the protein p53, VEGF, HER2 and CK 5/6. The differences in the distribution of study variables were evaluated by the use of Pearson Chi-Square and when necessary, Fisher's Exact test with a statistical significance when P-Value was less than 0.05.

5.1.1 AGE FREQUENCY

The youngest age was 21 while the oldest was 70 years and both presented with ductal carcinoma. Findings in this study are in contrast with those by Mbonde in Kenya in a study to characterize benign lesions and carcinomas of the female breast in Sub-Saharan population who found that the youngest age at presentation was 35 years compared to this study where most samples 24 (54.4%) in the age range 30-49 years were positive for cancer as compared to 20 (45.5%) in those aged 50 years and beyond. The results are also in agreement with what was reported by Li and Dixon in separate studies who reported 20 and 25 years respectively as the youngest ages at diagnosis. However, this result conflicts with what was reported by Gwakaya in a study called "Breast Cancer guidelines for Uganda" and Barnes in a study entitled "p53, Apoptosis and Breast Cancer" where he found that breast cancer had a higher frequency in those above 50 years than in those below 50 years. The differences in findings could be attributed to a difference in environmental factors, ethnicity, HIV status and probably genetic make up which might be influencing breast cancer development.

In this study therefore, this implies that breast carcinoma was more prevalent between 30 and 49 years (25%) than in those who were 50 years and above (22.7%) (Figure 5).

5.1.2 HISTOLOGY

A total number of 44 samples were analyzed to determine their histological types. The findings showed that there were 2 histological types of breast cancer (Lobular and Ductal carcinoma) of which lobular carcinoma was more predominant as (57%) of 44 samples while (43%) had ductal carcinoma (Figure 3). Of the 2 histological types, lobular carcinoma was found to be common in both the young 13 (52%) and the old 12 (60%) (Figure 5). Findings in this study are in contrast to those by Mbonde in Kenya, who found that the commonest histological type of breast cancer was ductal carcinoma (75%) and the youngest age at presentation was 35 as opposed to 21 which was the youngest age in this study. The disparity in findings could be associated with the protocols used during experiments as well as environmental factors. The other reason could be that Mbonde's study was done some years back (1998) and the pattern may have changed by this time. However, findings in this study are consistent with those by Adebamowo in Nigeria in a study entitled "Immunohistochemical and Molecular Subtypes of Breast Cancer" who reported higher prevalence of lobular (71%) than ductal carcinoma (29%). This means that in Zambia, breast cancer is more aggressive and requires aggressive treatment and has poor prognosis.

5.1.3 IMMUNOHISTOCHEMISTRY

Immunohistochemical profiling of the 44 positive breast cancer samples was done based on the evaluation of p53 and HER2 over-expression and VEGF and CK5/6 proliferation.

5.1.3.1 p53

In this study, we observed that p53 expression had the highest frequency as 42 (95%) out of 44 samples were positive while only 2 (5%) were negative (Table 2). Out of all the 42 samples that tested positive for p53, 24 (57.1%) were lobular carcinoma while 18 (42.9%) were ductal carcinoma. (Fisher's Exact Test, $P = 0.001$).

This means that lobular carcinoma tend to overexpress p53 protein than ductal carcinoma (figure 10), showing that there is a strong association between breast cancer and p53 overexpression. The results further justifies why lobular carcinomas tend to be more aggressive than ductal carcinoma.

These results are in line with those reported by Nyagol in a study entitled “Routine Assessment of Hormonal Receptor and HER-2/neu status underscores the need for more therapeutic targets” in Kenyan Women with breast cancer and Muthupei in a study called “Carcinoma of the breast” at Ga-Rankuwa Hospital histopathology laboratory (South Africa). It is important to note that p53 overexpression is associated with p53 mutations and this is a diagnostic marker. This entails that p53 is dysfunctional in most breast cancer patients thereby failing to carry out its functions of cell cycle regulation, DNA repair and inducing apoptosis for defective cells. p53 overexpression therefore means severity in disease with subsequent poor prognosis. p53 is also a predictor of treatment strategy; because p53 status is an important determinant of tumour responsiveness to antineoplastic agents ie p53 mutations have been associated with poor response to systemic therapy. Therefore, loss of p53 function can potentially result in the relative resistance of breast cancer to chemotherapy agents due to the loss of apoptotic properties since the function of anticancer agents is to induce cell death/apoptosis. As a predictor of poor prognosis, p53 accumulation is associated with a high tumour proliferation rate, early disease recurrence and early death. It is therefore a marker for more aggressive tumours.

5.1.3.2 HER2

In this study, HER₂ had the lowest prevalence as only 18 (41%) out of 44 samples were positive for HER2 while 26 (60%) were negative (Table 3). Furthermore, it was noted that for the positive samples, HER2 was equally expressed in both lobular and ductal carcinoma at 9 (50%) (Pearson Chi-Square, P = 0.027) (Figure 11). This result indicates that there is a strong association between breast cancer and HER2.

The findings are similar with those reported by Kendal in Ghana but not consistent with those by Adensukanmi in Nigeria in a study to determine gene expression in breast cancer. His findings showed that HER2 was one of the most expressed proteins.

The difference in findings between this study and that by Adensukanmi could be due to a difference in the way results were being interpreted as the method is subjective. HER2 positive breast cancers tend to be more aggressive than those that are negative for HER2. These cancers are also less responsive to hormonal therapy leading to poor prognosis. HER2 over expression is a diagnostic marker and could be used for routine testing of women diagnosed with invasive breast cancer because the results help in determining the treatment plan (use of Trastuzumab in combination with other drugs). In conclusion this study showed that 2/3 of breast cancer did not express HER2. This means that treatment outcome in 60% of patients will be good.

5.1.3.3 VEGF

Results in this study showed that 35 (79.5%) out of 44 samples were positive for VEGF while only 9 (20.5%) samples were negative. Further analysis showed that the prevalence of VEGF was higher in lobular carcinoma at 21 (48%) as compared to 14 (32%) in ductal carcinoma (Fisher's Exact Test, $P = 0.036$) (Figure 12). This means that there is a strong association between breast cancer and VEGF over-expression. These results are in line with those by Ziyaie and Benjamin in separate studies who reported similar findings. This may explain the higher prevalence of lobular than ductal carcinoma as well as the aggressiveness of the cancer. Angiogenesis plays a major role in breast cancer development, invasion and metastasis. When VEGF is over-expressed, it contributes to cancer progression with reduced survival and of course poor prognosis. As a diagnostic marker, over-expression of VEGF may be an early indication of metastasis. Treatment must be aimed at blocking of new blood vessels from sprouting. Most of the breast cancers were well served with oxygen/nutrients which ensured survival/metastasis, therefore, poor outcome.

5.3.1.4 CK5/6

In this study, results revealed that 23 (52%) of the 44 samples tested negative for CK5/6 while 21(48%) were positive. Out of the 23 samples that tested positive, 18 were ductal while 15 were lobular carcinoma. (Pearson Chi-Square, $P = 0.023$) (Figure 13). If a breast cancer is positive for CK5/6, it implies basal like (negative for estrogen receptor, progesterone receptor and HER2) and signifies poor prognosis. Tosten and Alejandran in their separate studies also had similar study findings. These tumours require aggressive treatment. Moreover, patients with this type of breast cancer along with their first degree relatives must be subjected to BRCA 1 mutation test because it could be familial. In our study, this could justify the screening for BRCA 1 in majority of women in this country to predict breast cancer development.

5.2 Conclusion

The study has shown that breast cancer is more frequent between the ages of 30-49 years. It has further revealed that breast cancer in Zambia is predominantly of lobular and ductal carcinoma histological types although lobular carcinoma is found to be with higher frequency than ductal carcinoma.

Based on selective immunostaining with specific antibodies, it has been found that P53 and VEGF are over expressed in lobular carcinoma which could be the reason why lobular carcinoma tends to be more aggressive with subsequent poor prognosis. CK5/6 was over expressed in ductal carcinoma than lobular although in lower percentage. This could justify the screening of all women for BRCA 1 mutation.

5.3 Limitation

5.3.1 Limited sample size such that results cannot be generalized to the whole country.

5.4 Recommendations

5.4.1 To scale up breast cancer screening programmes

5.4.2 All histological types of breast cancer to be subjected to immunohistochemistry

6.0 REFERENCES

Adebamowo CA, Ajayi OO. **Breast Cancer in Nigeria**. West Africa Journal of Medicine. 2000;19:179–191

Adebamowo CA, Famooto A, Ogundiran TO, Aniagwu T, Nkwodimmah C, Akang EE. **Immunohistochemical and molecular subtypes of breast cancer in Nigeria**. Breast Cancer Research Treatment. 2008; 110:183–188. [PubMed](#)

Adesunkanmi, ARK, OO Lawal, KA Adelusola, and MA Durosimi . **The severity, outcome and challenges of breast cancer in Nigeria**. *Breast* 2006. 15:399–409.

Barnes DM, Camplejohn RS: **p53, apoptosis and breast cancer**. *J Mammary Gland Biol Neoplasia* 1996, 1:163-175. [PubMed]

Bjerregaard, B and A Kung'u . **Breast cancer in Kenya: a histopathologic and epidemiologic study**. East Afr Med J 1992. 69:22–26. [\[Medline\]](#)

Carlson RW, Anderson BO, Burstein HJ, et al. **Invasive breast cancer**. *J Natl*

Dixon JM. **“Breast-conserving surgery: the balance between good cosmesis and local control,”** in *A Companion to Specialist Surgical Practice: Breast Surgery*. Ed. Dixon JM. Edinburgh: Elsevier, 2009.

Ferrara et al 2002. **Journal of Clinical Investigations**. 2012 Sep 4;122(9):3101-13. 10.1172/JCI61209. Epub 2012 Aug 13.

Filho M et al 2011. **Triple-Negative Breast Cancer**. [Journal Clinical Oncology](#). 2012 May 20;30(15):1879-87. doi: 10.1200/JCO.2011.38.2010. Epub 2012 Mar 26

Folkman J. 1995: **The influence of angiogenesis: Research on management of patients with Breast Cancer.** 1995;36(2):109-18. Review. PMID: 8534860 [PubMed - indexed for MEDLINE]

Fregene A, Newman LA: **Breast cancer in sub-Saharan Africa:** 2003, 1:170-198

Gakwaya A, Kigula-Mugambe JB, Kavuma A, Luwaga A, Fualall J, Jombwe J,

Galukande M, Kanyike D. **Cancer of the breast: 5-year survival in a tertiary hospital in Uganda.** Br J Cancer. 2008;99:63–67. [PMC free article] [PubMed]

Gakwaya, AM , P Baguma , and JB Kigula-Mugambe . et al. **The Uganda Breast Cancer Working Group: breast cancer guidelines for Uganda.** Africa Health Sciences 2003. 3:47–50.

Galukande M, Jombwe J, Fualal J, *et al.*: **Cancer of the breast: 5-year survival in a tertiary hospital in Uganda.** *Breast Cancer Journal* 2008, **99**(1):63-67.
[PubMed Abstract](#) | [Publisher Full Text](#) | [PubMed Central Full Text](#)

Harris CC: **p53 tumor suppressor gene from the basic research laboratory to the clinic: an abridged historical perspective.** *Carcinogenesis* 1996, 17:1187-1198. [PubMed]

Ikpatt OF, Kuopio T, Ndoma-Egba R, Collan Y: **Breast cancer in Nigeria and treatment**

Li et al 2003: **Influence of neoadjuvant chemotherapy on HER2/neu status in invasive breast cancer.** <http://www.ncbi.nlm.nih.gov/pubmed/23103368#>

Manders P 2003: **Vascular endothelial growth factor levels do not predict efficacy of systemic adjuvant treatment as assessed in breast cancer patients.** Internation Journal Oncology. 2004 Aug; 25(2):511-

Mbonde MP, Amir H, Mbembati NA, Holland R, Schwartz-Albiez R, Kitinya JN. **Characterisation of benign lesions and carcinomas of the female breast in a sub-Saharan population.** *Pathology, Research and Practice*. 1998;194:623–629. [PubMed]

Muthuphei, MN **Carcinoma of the breast at Ga-Rankuwa Hospital histopathology laboratory (South Africa).** *Central African Journal of Medicine* 1994. 40:254–257.

Nielsen M, *Breast Cancer Research*. 2014 Apr 8;16 (2):R37. PMID: 24713478 [PubMed]

Paredes, J , N Lopes , and F Milanezi . et al. **P-cadherin and cytokeratin 5: useful adjunct markers to distinguish basal-like ductal carcinoma in situ.** *Virchows Arch* 2007. 450:73–80. [[Medline](#)]

Nyagol J, Nyong'o A, Byakika B, Muchiri L, Cocco M, de Santi MM, Spina D, Bellan C, **and HER-2/neu status underscores the need for more therapeutic targets in Kenyan women with breast cancer.** *Analytical and quantitative Cytology and Histology*. 2006;28:97–103. [PubMed]

Perou CM, Jeffrey SS, Rijn M, Rees CA, Eisen MB, Ross DT, Pergamenschikov A, Williams CF, Zhu SX, Lee JC, Lashkari D, Shalon D, Brown PO, Botstein D: **Distinctive gene expression patterns in human mammary epithelial cells and breast cancers.** *Proceedings of the National Academy of Sciences of USA*

Rakha et al 2014. **Molecular Profiling of Breast Cancer in Nigeria.**
<http://www.ncbi.nlm.nih.gov/pubmed/24763230>

Sorlie T, Perou CM, Tibshirani R, et al. **Gene expression patterns of breast carcinomas distinguish tumor subclasses with clinical implications.** *National Academy of Science USA* 2001; **98**: 10869-10874. PubMed

Vorobiof DA, Sitas F, Vorobiof G. **Breast cancer incidence in South Africa.** *J Clin Oncol.* 2001;19(18 Suppl):125S–127S. [PubMed]

Wabinga, HR, DM Parkin, F Wabwire-Mangen, and JW Mugerwa. **Cancer in Kampala, Uganda, in 1989-91: changes in incidence in the era of AIDS.** *Int J Cancer* 1993. 54
1:26–36.

Weigelt B, Baehner FL, Reis-Filho JS. **The contribution of gene expression profiling to breast cancer classification, prognostication and prediction:** a retrospective of the last decade. *J Pathol* 2010;

Appendix 1: Data abstraction form

HISTOLOGIC CHARACTERIZATION AND IMMUNOHISTOCHEMICAL
PROFILES OF p53, HER2, VEGF AND CK5/6 OF BREAST CANCER AT THE
UNIVERSITY TEACHING HOSPITAL, LUSAKA, ZAMBIA

SERIAL NUMBER:

DATE:

INSTRUCTIONS.....

1. No name should appear on/and or in this form.
2. Answer all the questions.
3. Use a pen/pencil
4. Information obtained in this data abstraction form will be kept confidential.

SECTION A: BACKGROUND INFORMATION

1. Age of patient

2. Laboratory serial number.....

SECTION B: LABORATORY RESULTS

3. Histology results

.....

4. Immunohistochemical profile of specimen

.....