

**CASE REPORT**

# Subdural Empyema: A Case Report from Southern Zambia and a Review of the Literature

G Musa, A Gots

Department of Surgery, Livingstone Central Hospital, P. O. Box 60091, Livingstone, Zambia

## ABSTRACT

A 14yr old male presented with subdural empyema following a right frontal subaponeurotic abscess. Presented with a Glasgow coma scale of 8/15, left sided hemiplegia and a history of convulsions for 4 days. Other history was unremarkable. CT brain showed diffuse subdural empyema. There was no neurosurgeon on site and the patient declined referral to the nearest centre with neurosurgical services. Hence he was managed on IV chloramphenicol and metronidazole for 4weeks with clinical improvement evidenced by a Glasgow coma scale of 15/15, absence of seizures and an increase in power on the left side to 4/5. A repeat CT brain at 4weeks showed localised right parietal and occipital parafalcine empyema with cerebral oedema. Two craniotomies were done to drain the pus. He was then continued on cefotaxime, metronidazole for 3 more weeks, mannitol and dexamethasone for one week. Primary duraplasty was not done as the patient deteriorated in theatre due to anaesthetist complication. Klebsiella species was cultured sensitive to cefotaxime, chloramphenicol and ciprofloxacin. Repeat CT scan showed no residue empyema on day 7 post operation. Secondary duraplasty was done on day 11 post craniotomy due to cerebrospinal fluid leakage. On day 11 he was treated for malaria. The patient recovered well, neurologically intact, without any complications and no cerebrospinal fluid leak. He was discharged on day 10 post duraplasty on oral antibiotics for 4weeks after which cranioplasty was done.

## INTRODUCTION

Subdural empyema is a rare and rapidly progressive condition which is fatal if it remains unrecognised and untreated. It can occur as a complication of meningitis, paranasal sinusitis, trauma and otitis media. It usually presents with headache, fever and altered mental status. In some cases, with seizures. It can complicate to cerebral oedema, hydrocephalus, cerebral infarction from thrombosis of the cortical veins or cavernous sinuses or from septic venous thrombosis of contiguous veins in the area of subdural empyema.

It is usually a sequelae and difficult to distinguish from meningitis hence the attending clinician must have a high index of suspicion. Prompt management with early neurosurgery intervention accompanied by long term intravenous and oral antibiotics is the gold standard treatment.

## LITERATURE REVIEW

In a 10-year case series, authors concluded that altered sensorium, fever, vomiting, and headache should alert the clinician to the possibility of Intracranial Subdural Empyema. A history of neurosurgical procedure (44%), sinusitis (28%), otitis media (14%), or skull trauma increases the likelihood of this differential. Management includes sensitive antibiotic therapy and surgical drainage. Compared with burr hole, craniotomy is associated with less recurrence of intracranial subdural empyema. They also concluded that Common organisms associated with neurosurgical operations are *Staphylococcus aureus* and *Propionibacterium acnes*. *Streptococcus milleri* and *Fusobacterium necrophorum* are common in patients with sinusitis,

and *Bacteroides fragilis* and *Staphylococcus aureus* are common otogenic sources. Their findings were consistent with what has been reported in the literature.<sup>1</sup> In a case series done at the University teaching hospital, gram positive cocci comprising streptococci and staphylococcus were isolated in 10 of 18 patients with intracranial infections while 4 patients had negative cultures. Actinomycetes was seen in one patient.<sup>2</sup>

In another case series of 45 patients, young males were more affected than females and that complete evacuation of pus and eradication of the source of infection is the goal of treatment.<sup>3</sup> Feuerman et al<sup>4</sup> reported incidence of recurrence of subdural empyema following a burr hole and evacuation of pus in about 40% cases. Other authors have shown that results of burr hole, craniectomy and craniotomies are comparable. Recently, some authors have reported good results with a mini craniotomy or use of endoscope after a burr hole. In a Kenyan case series, they noted a 50% mortality in cases managed with burr hole as first treatment followed by craniotomy and only 14.2% mortality in cases managed with primary craniotomy.<sup>5</sup> This is similar to the findings of Bannister et al who reviewed 375 cases and concluded that craniotomy was superior to burr holes. This is because it offers a more complete pus removal which may be too thick or loculated for burr holes.<sup>6</sup> There are situations where burr holes are recommended over craniotomy like patients with septic shock or with parafalcine empyemas.<sup>7</sup> Other indications for burr hole use include emergency situations or if the patient is considered frail.<sup>8</sup>

However, in a paper on Management of subdural intracranial empyema should not always require surgery, seven patients were treated on antibiotics alone. 6 patients recovered with no sequelae and one required delayed surgery and recovered with epilepsy. In this study intravenous antibiotics were given for up to 4 to 6 weeks and then oral antibiotics until CT scan was clear of empyema.<sup>9</sup> In this case review the drug of choice before culture results was

chloramphenicol due to the cerebrospinal fluid and brain permeability. However, if the organism is unknown, then an oxacillin plus ceftriaxone/cefotaxime plus metronidazole is recommended;<sup>10</sup> however, if there is a suspicion for methicillin-resistant *Staphylococcus aureus*, then vancomycin instead of oxacillin is warranted.<sup>10</sup> Linezolid is an alternative treatment in case of conventional antibiotic regimen failure.<sup>11</sup>

As far as the duration of antibiotic treatment, it differs among practices. For instance, one of the practices recommends at least two weeks through the intravenous route, followed by six weeks of oral therapy. If osteomyelitis concurs with subdural empyema, then the oral route is usually eight weeks.<sup>10</sup> The second practice states that intravenous route should be for six weeks followed by an oral course of four to six weeks.<sup>12</sup> Other adjuvant therapy includes intravenous steroids and mannitol for reducing edema and intracranial pressure respectively.

## DESCRIPTION OF CASE REPORT

The patient, a 14yr old male, came to us as a referral from the local hospital. He presented with a two-week history of headache, left sided weakness for 1 week and convulsions for 4 days. He had a right frontal subaponeurotic abscess from which pus and small hematomas were drained. However, there was no history of trauma. He was then treated with ceftriaxone, dexamethasone, diazepam and phenobarbitone as a case of meningitis for 3 days and then referred to the neurosurgeon.

He was HIV negative with no other known chronic diseases. He had no known drug allergies and no history of herbal medication use. The family history was unremarkable.

## Examination

Ill looking, mildly pale, febrile, not jaundiced or cyanosed, Glasgow coma scale: E-1, V-2, M-5 (8/15), no anisocoria, saturating at 95% on room air, hemodynamically stable blood pressure

113/70mmHg, pulse rate 90/min, random blood sugar 5.1mmol/L, temperature 38°C, respiratory rate 18/min.

He had left sided hemiplegia with loss of sensation on the same side (crude and light touch tested), with 1+ reflexes and left medial squint.

He had a clean wound on right frontal region packed and dressed.

Normal cardiovascular, respiratory and abdominal exam

### Investigations

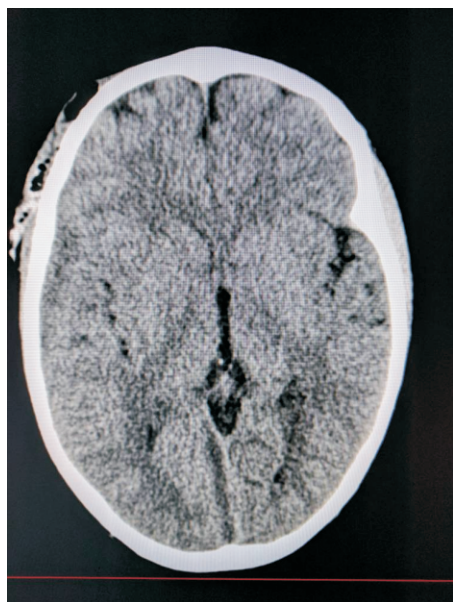
Full blood count- Haemoglobin(Hb) 6.8g/dL, White cell count(WCC)-  $20.90 \times 10^9$ , differential count unavailable, Platelets (plts)- 392

Normal liver and kidney function tests

Lumbar puncture- Unremarkable

CT brain- diffuse subdural effusion, most likely empyema.

### figure 1



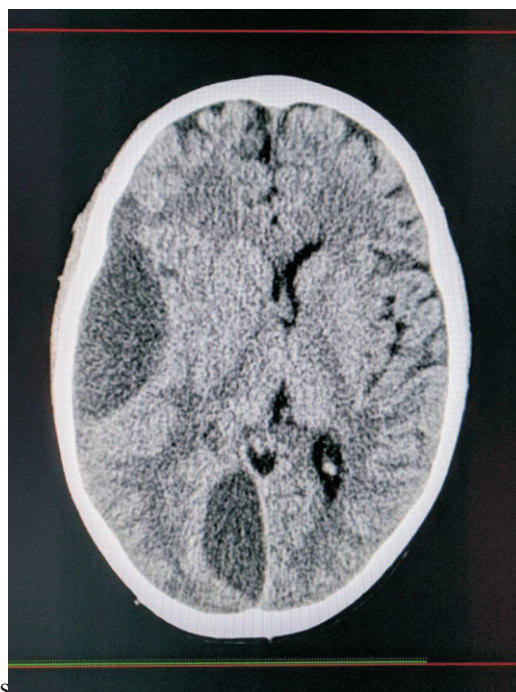
Many other full blood counts done for monitoring of treatment with progressive normalisation of the cell counts.

4weeks later-

Full Blood Count- WCC-  $3.26 \times 10^9$ , Hb 9.4g/dL, plts-161

CT Brain- localised in right parietal and occipital parafalcine subdural empyema with midline shift.

### figure 2



Pus and pus cells cultured, sensitive to cefotaxime, chloramphenicol and ciprofloxacin.

Day11 Post-operative

WCC- $15.9 \times 10^9$ , Hb-11.3g/dL, plts-199, neutrophils 93.6%, Malaria parasite slide- positive, CSF culture- no growth (taken during duraplasty)

### Treatment

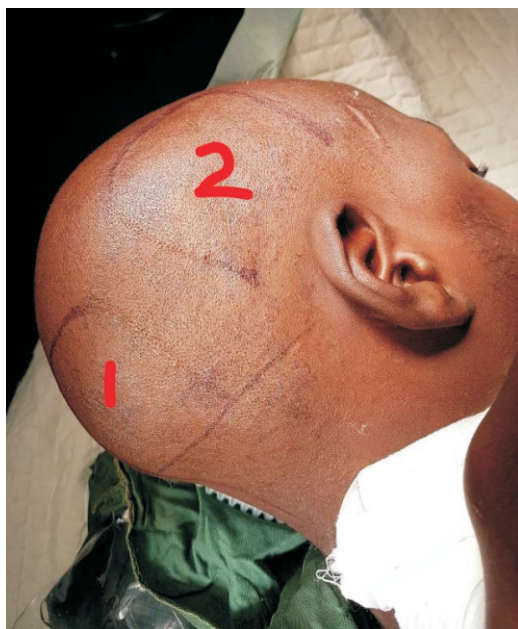On admission: Intravenous antibiotics- chloramphenicol and metronidazole for 4weeks. By week 4, he had shown marked clinical improvement. He was ambulant with left side power of 4/5.

Craniotomy done 4 weeks post admission. Two pockets of localised pus with locules and serous



fluid in the right parietal and occipital parafalcine region where drained (figure 3). The cavities opened, evacuated and washed with hydrogen peroxide. Ceftriaxone was used to wash the cavities. On the parietal region craniotomy was done. However, on the occipital region craniectomy done.

**figure 3**



Due very high intracranial pressure, the brain tissue was herniating through the craniectomy site.

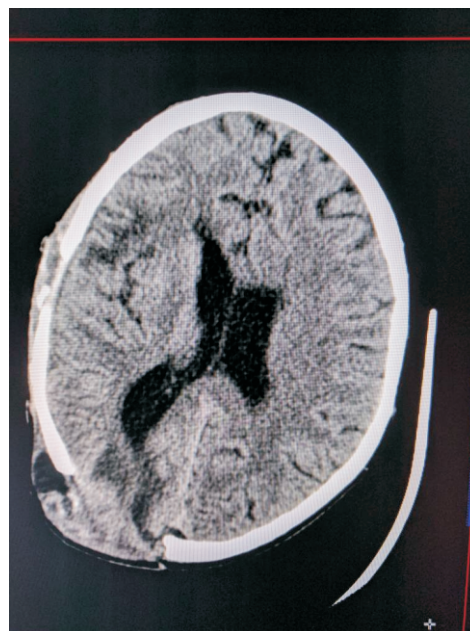
Intraoperatively, the patient de-saturated due to an improperly secured endotracheal tube which lodged into the right main bronchus. Hence primary duraplasty was not done in order to reduce operative time and to allow stabilization of the patient. Dura was approximated and skin closed.

Postoperatively, intravenous cefotaxime and metronidazole were given with mannitol and dexamethasone.

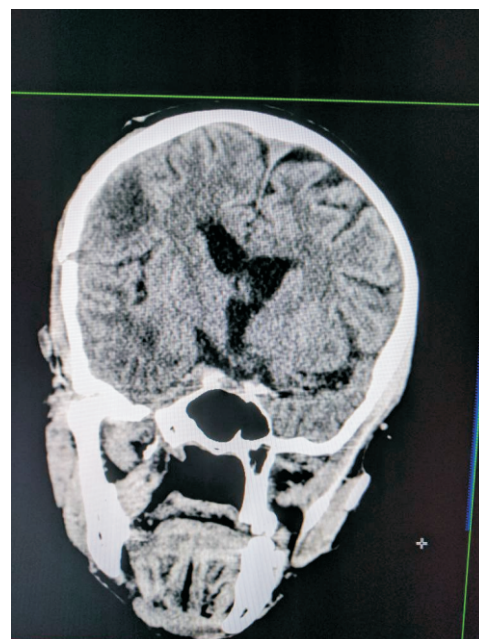Day 7 post-operative CT brain showed no residual empyema. (figure 4 and 5)

Day 4 to 10 post-operative, the patient had on and off CSF leakage on the occipital craniectomy site. On day 10, the sutures were removed. There was increased occipital region CSF leak, the parietal site was uneventful.

**figure 4**



**figure 5**



Day 11, secondary duraplasty was done using fascia lata. He was continued on cefotaxime, metronidazole, mannitol and dexamethasone.

Day 11, he was diagnosed with malaria and started on artesunate.

Patient improved with no CSF leak post Duraplasty

Repeat Malaria slide on day 5 was negative.

Physiotherapy consultation for physical rehabilitation.

On day 10 post duraplasty, the patient was discharged in good condition, with no complaints, no paresis and no cerebrospinal fluid leakage. He was given cephalexin and metronidazole for 4weeks.

## DISCUSSION

The features of subdural empyema may be non-specific to mimic meningitis. However, the development of neurological deficits such as hemiplegia as seen in our patient, features of increased intracranial pressure and persistent fever makes subdural empyema a differential. In a few cases, the diagnosis has been made in the absence of focal neurological deficits. However, altered sensorium has been a more common finding in most cases. Literature suggests that subdural empyema is more common following neuro-surgical procedures, sinusitis, otitis media and post trauma. However, our patient developed the condition post frontal subaponeurotic abscess. The frontal abscess could have been the source of infection into the subdural space or vice versa due to the valve-less diploic venous drainage communication between the scalp and the intracranial venous system. This is a very rare complication. The development of subdural empyema following a subaponeurotic abscess is not documented in the literature reviewed. Hence, clinicians must consider the diagnosis in a patient presenting with altered consciousness following a subaponeurotic abscess.

Treatment involves early neurosurgical intervention and long term intravenous antibiotics followed by long term oral antibiotics. At the time of diagnosis, there was no neurosurgeon on site and the patient declined referral to the nearest centre with neurosurgical services. Hence the patient was treated with intravenous chloramphenicol and metronidazole. Intravenous chloramphenicol is the

recommended drug because it has good penetration of the blood-brain barrier in the presence of inflamed meninges. Our patient was managed as such with an addition of metronidazole to cover anaerobic bacteria for 4 weeks prior to surgery with close monitoring. Intra-operative pus swab culture and sensitivity revealed klebsiella species sensitive to chloramphenicol, cefotaxime and ciprofloxacin, hence the patient was switched to cefotaxime to avoid side effects of chloramphenicol which he had received for 4weeks already. As recommended in literature he was continued on intravenous antibiotics for 6 weeks and switched to oral antibiotics for another 4 weeks. Our patient presented with cerebral oedema and increased intracranial pressure, hence short courses of mannitol and dexamethasone were given post operatively.

Intraoperatively, the pus pockets were loculated with thick pus and serous fluid. In retrospect, complete removal of pus could not have been possible if burr holes had been used instead of the generous craniotomies. This is in agreement with the current guidelines. However, this doesn't apply to critically ill or frail patients where burr holes can be done to reduce anaesthetic time. We had two operative sites: (figure 3) site 1 (parietal) a craniotomy was done whereas on site 2 (occipital), craniectomy was done due to herniation of brain tissue intraoperative as a result of high intracranial pressure. Primary duraplasty was not done due to anaesthetic complication requiring a shorter operative time. However, secondary duraplasty was done 11 days later due to cerebrospinal fluid leakage with no complications.

After 7 weeks of hospital admission, the patient was discharged with no complications. On his one-month review, he had normal function with no signs of neurological or mental deficits. Cranioplasty was done with no complications.

## CONCLUSION

Due to the non-specific clinical features, there is

need for high index of suspicion to make a diagnosis of subdural empyema and the importance of early diagnostic brain CT-scan cannot be overemphasized. Once diagnosis is made, early neurosurgical consultation and surgical drainage of the pus is required, accompanied by aggressive and prolonged use of intravenous and oral antibiotics. Intravenous chloramphenicol remains the first line drug of choice due to its good cerebral penetration. Antibiotics should be switched appropriately as per culture and sensitivity.

## REFERENCES

1. Heath F et al, Intracranial Subdural Empyema: A 10-Year Case Series. *Ochsner Journal*. 2014 Summer; 14(2): 188–194.
2. Chikoya L. Non traumatic intracranial infection at the University teaching hospital Lusaka, Zambia. *Medical journal of Zambia* 2010;37(2): 89-92.
3. Tewari MK, Sharma RR, Shiv VK, Lad SD. Spectrum of intracranial subdural empyemas in a series of 45 patients: current surgical options and outcome. *Neurology India*. 2004 Sep;52(3): 346–349..
4. Feuerman T, Wachym MP, Gade GF, Dubrow T. Craniotomy improves outcome in subdural empyema. *Surgical Neurology* 1989; 32:105-10.
5. Ruberti R.F. subdural empyema in the Kenyan Africa. *African journal of neurological science*. 1997..
6. Bannister G, Williams B, Smith S. Treatment of subdural empyema. *Journal of Neurosurgery* 55:82-88, 1981
7. Nathoo N, Nadvi SS, Gouws E, van Dellen JR. Craniotomy improves outcomes for cranial subdural empyemas: computed tomography-era experience with 699 patients. *Neurosurgery*. 2001;49(4): 872-7; discussion 877-8.
8. Ramamurthi B, Panole A. Surgery of pyogenic infections. *Textbook of Operative Neurosurgery*. Vol. 1. New Delhi: BI publications pvt ltd; 2007. pp. 310–313.
9. D Leys et al. Management of subdural intracranial empyemas should not always require surgery. *Journal of Neurology, Neurosurgery, and Psychiatry* 1986;49:635-639.
10. De Bonis P, Anile C, Pompucci A, Labonia M, Lucantoni C, Mangiola A. Cranial and spinal subdural empyema. *Journal of Neurosurgery*. 2009;23(3):335–340.
11. Lefebvre L, Metellus P, Dufour H, Bruder N. Linezolid for treatment of subdural empyema due to Streptococcus: case reports. *Surgical Neurology*. 2009;71(1):89–91.
12. Kurschel S, Mohia A, Weigl V, Eder H. G. Hyperbaric oxygen therapy for the treatment of brain abscess in children. *Childs Nervous System*. 2006; 22:38–42.