

VESICO-URETERIC REFLUX IN URINARY BILHARZIASIS

(Observation in Zambia)

* B. Elem FRCS.

Summary

Cystoscopic, urographic and voiding cystogram findings on 75 consecutive patients with urinary bilharziasis have been presented. 8 cases (14 ureters) showed grade 3 vesico-ureteric reflux. An attempt has been made to identify the group of patients likely to have reflux and should be selected for micturating cystogram. Aspects of management of this disorder have been briefly discussed and it has been suggested that bilharzia associated vesico-ureteric reflux is unlikely to resolve on expectant measures alone.

Introduction.

Gelfand as early as 1948 first suggested the causal association between urinary bilharziasis and vesico-ureteric reflux. Its exact incidence is difficult to establish as voiding cystogram is not routinely performed in schistosoma haematobium infection of the urinary tract but has been reported between 3% (Weinberg and Gelfand, 1968) and 13% (Lehman et al, 1973). This paper reports its incidence in Zambia along with an analysis of the clinico-pathological features of the patients with vesico-ureteric reflux. On the basis of clinical, cystoscopic and urographic findings an attempt has also been made to identify patients of urinary bilharziasis with higher risk of reflux.

Patients and Methods

75 consecutive adult Zambian males (mean age 30 years) with urinary tract bilharziasis diagnosed by cysto-biopsy underwent micturating cystogram. During cystoscopy under general anaesthesia, the extent and distribution of sandy patches, appearance of the ureteric orifices and the bladder capacity were recorded. All patients also had preliminary intravenous urograms which were critically analysed with a view to identifying any characteristic appearance consistent with the probable presence of reflux.

Findings

Refluxing patients (Table)

8 patients demonstrated grade 3 reflux; 6 bilateral and unilateral in the remaining 2. Ex-

tensive sandy patches in the bladder mucosa were present in all 8 cases. The ureteric orifices were patulous on the refluxing sides in 4 cases. In others, poor visibility due to reduced bladder capacity, led to failure of visualization of the ureteric orifices. The bladder capacity was grossly reduced (200 mls or less) in 4 cases. Radiological calcification of the urinary bladder was observed in 5 (68%) cases, one of these patients also had bilateral ureteric calcification. The urograms of 4 cases elaborated a characteristic disposition of the pelvic ureters (Figs. 1 & 2) — an exaggerated lateral convexity with their apparent insertion at the vault of the bladder — an appearance aptly described as "cow-horn" type of deformity (Umerah, 1977). A moderate to severe degree of upper tract dilatation was present in all cases; the dilatation was most marked in 4 cases with the characteristic ureteric deformity.

Non Refluxing Group

All 67 patients in this group also showed extensive sandy patches at cystoscopy, the bladder capacity was reduced — less than 300 mls — in 4 cases (5.9%). The ureteric orifices in 6 cases looked stenosed and appeared normal in others. Radiological calcification of the bladder was observed in 20 (29%) cases. The urograms were abnormal in half of these cases. The characteristic ureteric deformity was also present in 6 cases (8.8%), none of which, however, were associated with ureteric dilatation of any significance.

Discussion

Our findings of 10% is well within the reported incidence of vesico-ureteric reflux in urinary bilharziasis. The subjects investigated in this study, similar to most reported series, were patients with moderate to severe symptoms related to this parasitic infection; a probable indication of an advanced and high intensity infection. It would thus be erroneous to accept the present figure as representative of its incidence among the population at large in an endemic situation. The latter figure is likely to

* Consultant Urologist and Honorary Lecturer, Unit of Urology, Department of Surgery, University Teaching Hospital, Lusaka, Zambia

be much lower.

As to the criterion of selecting patients with urinary bilharziasis for micturating cystogram, there appear to be no pathognomonic clinical features. Patulous ureteric orifices at cystoscopy is strongly suggestive of existing reflux but their visualisation is often difficult due to reduced bladder capacity. Urographic appearance may also prove to be helpful in the selection of high risk patients. The "cow-horn" type of urographic appearance is not infrequently observed in urinary bilharziasis; its clinical significance remains unclear. According to the present findings this appearance may well be indicative of the presence of vesico-ureteric reflux. Such deformity was observed in 50% of refluxing patients as opposed to 6% in the patients without reflux. The presence of reflux becomes highly probable when this appearance is associated with dilated ureters. Cases of bilharzial reflux also elaborate a few distinct and important patho-physiological features. Such cases are not infrequently associated with severe and irrevocable structural damage of the vesico-ureteric components; the involved ureters also exhibit impaired peristalsis of varying severity due to damaged muscle linings. In some of the ureters, the loss of muscular tissue may be severe enough to render them atonic. The atonic state of the

ureters even in the presence of vesico-ureteric incompetence, perhaps paradoxically produces some degree of ureteric stasis. The composite effects of reflux as well as ureteric stasis is likely to result in renal functional impairment of far more severity than in simple reflux and adds urgency to its surgical correction. The associated structural damage of the affected bladders and ureters, however, not infrequently make antireflux surgery a sheer technical impossibility (Fig. 1). In such patients vesico-ureteric reflux, although an important lesion, is merely one facet of an overall complex picture; simple surgical correction of the former is unlikely to halt the progression of renal damage and may even make the situation worse. The results of ureteric reimplantation by submucosal tunneling for prevention of reflux leaves much to be desired. Whilst such a procedure in suitable cases effectively rectifies vesico-ureteric incompetence, it nonetheless exposes the reimplanted segments to the vulnerable situation of future involvement in recurring vesical fibrosis. It would seem that a simple nipple type of reimplantation is likely to be an effective alternative technique in this situation but a meaningful evaluation of this procedure in bilharzial reflux is still awaited.

TABLE I
SYMPTOMATOLOGY, BIOCHEMICAL AND RADIOLOGICAL FINDINGS OF 8 PATIENTS WITH REFLUX

No.	Patient & Age	Symptoms	Cystoscopy & Capacity	Cystogram	Urea Creatinine	Ivu Findings Appearance
1.	W.S. 24 yrs.	Pain both loins Terminal haematuria	500mls Patulous ureteric Orifices	Bilateral reflux	91 3	"Cow horn." Gross bilateral hydroureter & hydronephrosis.
2.	J.M. 30 yrs	Rt. loin pain	200 mls orifices Not Seen	Bilateral reflux	50 2	"Cow horn" deformity. Gross hydronephrosis & bilateral hydroureters
3.	B.K. 50 yrs	Uralgia	200 mls Orifices not visualized	Bilateral reflux	40 1.5	Bilateral gross hydronephrosis & hydroureter.
4.	S.M. 32 yrs.	Uralgia & urge incontinence	less than 200 mls orifices not seen	Bilateral reflux	60 3	"Cow horn". Gross bilateral hydronephrosis & hydroureter.
5.	E.M. 29 yrs.	Uralgia & frequency	650 mls Patulous Rt. orifice	Right Reflux	20 0.8	Mild right calycosis.
6.	F.M. 38 yrs.	Both loin pain (hypertension)	400 mls Patulous orifices	Bilateral reflux	25 1	Bilateral moderate hydro-nephrosis & hydroureters.
7.	S.B. 18 yrs	Urinary frequency & uralgia	350 mls Orifices not seen Bladder calculus	Left reflux	50 1.2	Bilateral gross hydronephrosis & hydroureters.
8.	A.G. 25 yrs.	Lower abdominal pain & uralgia	200 mls Patulous orifices	Bilateral reflux	60 2.5	"Cow-Horn" Gross bilateral hydronephrosis & hydroureters.

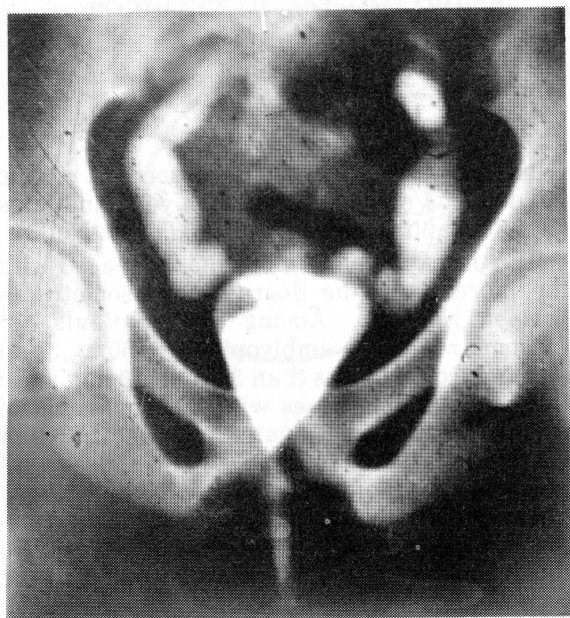


Fig. 1. Micturating cystogram of S.M. (patient 6). Bilateral reflux, grossly contracted bladder and marked hydroureters. IVU of this patient also depicted an identical "cow horn" type of appearance.

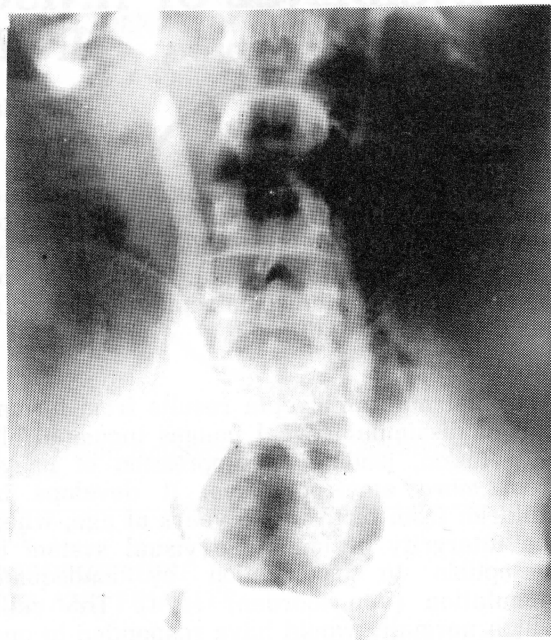


Fig. 2. Urogram of J.M. (patient 2) with bilateral reflux. Depicting typical "cow horn" type of appearance.

Acknowledgements

I thank the Permanent Secretary for authorising publication and Mr A. Ansary, Head, Department of Medical Illustration, University of Zambia for assistance with the Illustrations.

References

1. Gelfand M. (1948). Bilharzial affection of the ureter. (A study of 110 consecutive necropsies). *British Medical Journal*. 1, 1228-1230.
2. Lehman J.S. (Jr.), Farid Z., Smith J.H., Bassily S. and El-Masry N.A., (1973). Urinary

schistosomiasis in Egypt: Clinical, Radiological, Bacteriological & Parasitological correlation. Trans. of the Roy. Soc. of Tropical Med. & Hygiene. 67, 384-399.

3. Umerah B.C. (1977). The less familiar manifestations of schistosomiasis of the urinary tract. *Brit. J. of Radiology*. 50, 105-109.
4. Weinberg R.W. & Gelfand M. (1968). Observations on the incidence of vesico-ureteric reflux in urinary bilharziasis. *British Journal of Urology*. 40, 68-71.