

Giant-Cell Tumour of the Tendon Sheath

Review of Literature and Report of a Case

Mr P.K. Parekh, M.B.; B.S.; M.S. (ORTH)

Department of Surgery,
The University Teaching Hospital,
LUSAKA

For reprints send your request to: P.O. Box 50130, LUSAKA – ZAMBIA.

SUMMARY

An unusual case of giant-cell tumours of the tendon sheath (syn. Pigmented villonodular tenosynovitis or fibrous xanthoma) of a long thumb flexor is presented.

The unusual features are: two distinctly different tumours of almost similar size and shape arising from the tendon sheath at its either ends but with a segment of normal tendon sheath in between and presence of early malignant changes in the distal tumour with a benign proximal one, confirmed microscopically. Lastly, radiograph showed definite bony involvement in the proximal phalanx of the thumb.

On extensive review of the literature, I found reports of rare presentation of malignant changes and bony erosion, but none had these various features.

INTRODUCTION

Giant cell tumour of the tendon sheath was first reported by Chassaignac (1852). And Jaffe-et-al (1941) coined the term "Pigmented Villonodular Tenosynovitis", for a tumour-like swelling arising from the synovium of a tendon sheath.

Case History:

E.M.; A young (22 years) Zambian male was admitted to the University Teaching Hospital, Lusaka on 6th August 1980, with complaints of multiple swellings over his right thumb and over the front of the wrist on the same side for two years. Patient also complained of (1) pain over the thumb, (2) limitation of thumb and band wrist movements, and (3) inability to grasp the object with same hand.

A small peanut size swelling appeared over the front of the thumb and gradually increased in size over 2 years to cover the thumb on sides. After about six months a similar swelling appeared on the wrist gradually increasing in size, with restriction of thumb and the wrist movements.

An incisional biopsy of the thumb swelling was reported as "Giant cell tumour of the tendon sheath," at a district hospital in early 1980.

The first swelling measured 6.3 x 3.3 cms, was well defined, nodular and situated over the volar surface of the right thumb extending from 1 cm proximal to the proximal

thumb crease to just distal to the interphalangeal joint. The overlying skin was normal. Firm in consistency, it was adherent to a biopsy scar and was tender. Interphalangeal joint movement was lost and there was considerable restriction of the mobility of the metacarpo-phalangeal joint.

The second was similar but more diffuse and was palpable just proximal to the flexor retinaculum (Fig. 1). Both swellings seemed to be related to the long flexor tendon of the thumb and limited flexion. Regional lymphnodes were clinically normal.

Reoentgenogram showed bony infiltration of the proximal phalanx of the thumb on the radial side. Chest radiograph, heamatology and serum chemistry were normal.

The swelling over the thumb was explored by multiple 'Z' incisions and that over the wrist by a lazy 'S' approach.

On exploration, the distal swelling was fusiform, nodular, dark yellow coloured, firm in consistency, extending from the neck of the first metacarpal to the base of the distal phalanx and was enveloping the flexor pollicis longus in front. It gave grating sensations on cutting. The cut surface showed multiple lobules, few septa and some brownish deposits.

The swelling was surrounded by a fibrous capsule except near the previous biopsy scar, the interphalangeal joint capsule and proximal phalanx, infiltrating the later two structures and soft tissues on its dorsal aspect. On dividing the swelling to free the tendon, a few millilitres of thick, semigelatinous yellowish fluid was obtained.

The proximal swelling over the wrist extended from under the carpal tunnel, to the lower forearm (Fig. 2) with similar features, enveloping the same tendon, with some fluid within it and without infiltration of the surrounding structures.

Both tumours were excised leaving the long flexor tendon of the thumb intact and the space was drained by a suction drain and compressed by a firm bandage. Wound healed primarily in seven days.

On histopathological examination, the section showed high cellularity with few giant cells and infiltration of the capsule suggestive of low grade malignancy of the distal swelling. However, proximal swelling appeared benign (Figs 3 and 4).

DISCUSSION

Although this tumour typically occurs in association with the flexor tendons as a solitary, firm encapsulated, irregular, multicolored nodule in a middle aged person (Boyes - 1964), two separate

FIG. 1



Clinical appearance. Marking shows only the most prominent part of swellings.

tumours were found in a young black Zambian male. It is second most common tumour of the hand (Willis - 1967), fingers being the commonest single site of its origin. Both the tumours in this case not only involved the same hand but a single tendon of the long thumb flexor muscle, arising from the single flexor tendon sheath on its either ends, with a segment of a normal tendon sheath as if it were seeded along the tendon. Both the tumours resembled each other in their size, shape and showed typical features of villonodular tenosynovitis. The distal tumour presented as a painful swelling which is an unusual feature.

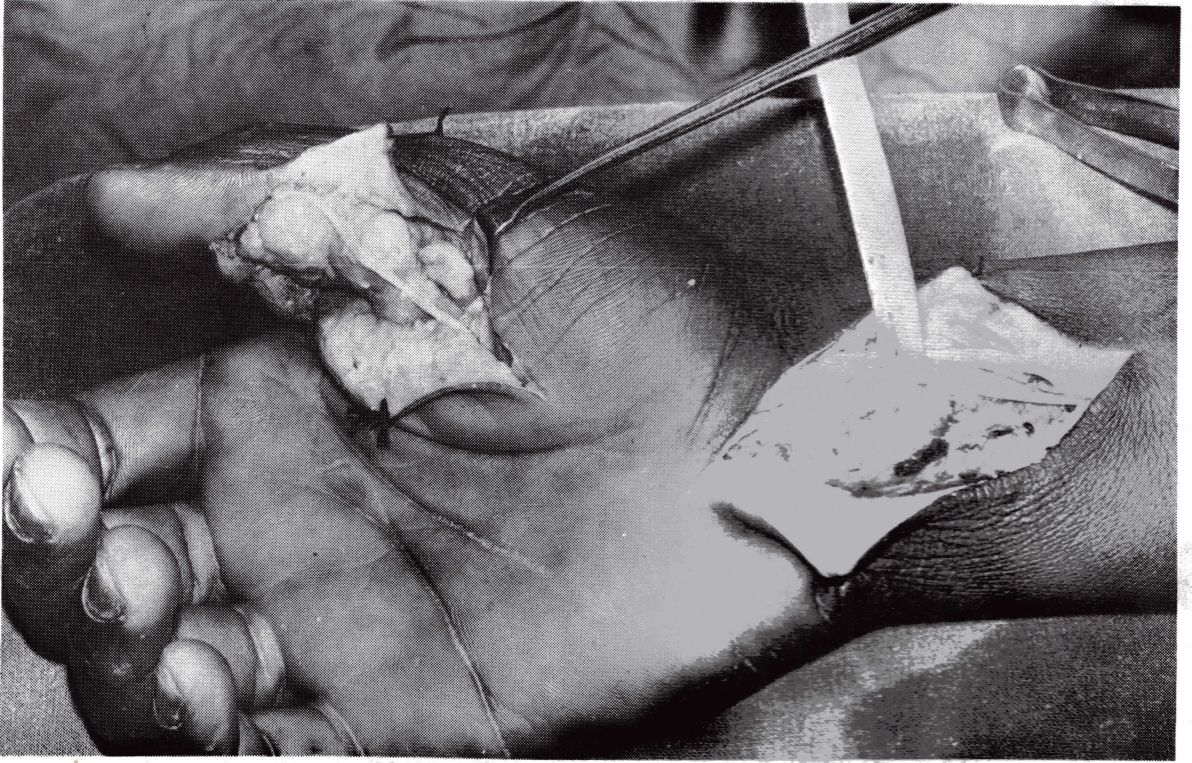
The pathogenesis of the lesion is controversial Jaffe, Lichtenstein and Sutro (1941) proposed inflammatory hyperplasia of synovial lining cells and histiocytes; followed by a spontaneous involution resulting in extensive fibrosis and collagenization. The evolutionary cycle may go on to completion as in a long standing tendon sheath nodule or may renew itself as in more exuberant lesion in the knee joint (Lichtenstein - 1972). However others (Wright - 1951 and Ackerman - et - al - 1971) believe in a neoplastic origin supported by experimental reproduc-

tion of a proliferative feature of the pigmented villonodular synovitis by inducing prolonged haemarthrosis in dogs, was lacking the essential component of diffuse histiocytic proliferation. Stout (1966) classified this lesion as neoplasm of histiocytic origin. In the opinion of a Bennett (1947) and Willis (1967) the lesion is initiated by inflammation causing hyperplasia of the synovium and the process might continue to neoplasia.

The tumours described in this case report, show different pattern of infiltration. The distal swelling with fixity to the bone clinically, infiltration of the capsule of the interphalangeal joint and the proximal phalanx of the thumb and soft tissues on exploration, involument of the proximal phalanx on radiography and malignant characteristics on microscopy suggested early malignant transformation. The proximal swelling showed characteristics of a benign, encapsulated tumour clinically, on exploration and microscopy.

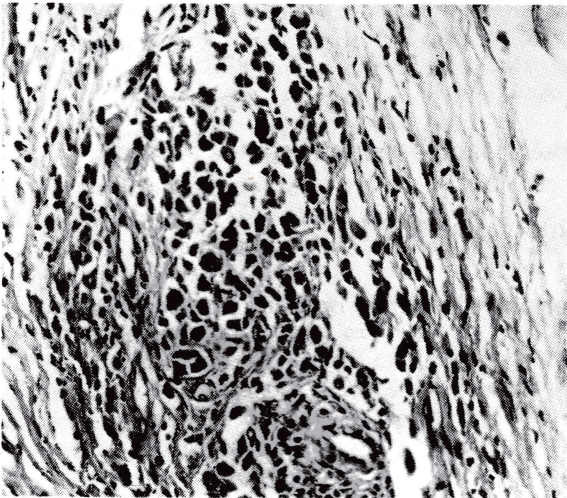
The view expressed before I believe explains the benign nature of the proximal and early malignant nature of the distal tumour, in different phases of development.

FIG. II



On exploration, Nodular appearance. Radial digital nerve for thumb crosses the distal swelling while a median nerve is retracted by a nerve-tap in front of the wrist.

FIG. III



Microphotograph of the proximal tumour (x 250-H. & E. stain); Definite capsular infiltration and early malignant changes as against benign features of the previous section.

FIG. IV

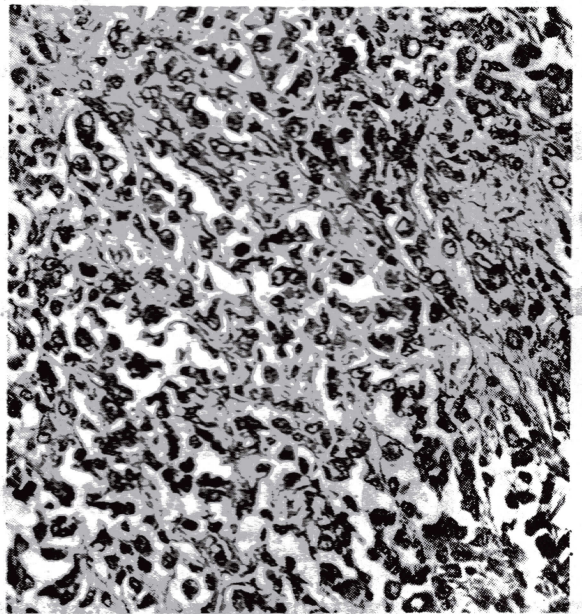


TABLE I
MALIGNANT TRANSFORMATION

Author and Year	Cases	Site	Primary Excisions	Subsequent Treatment	Later Metastasis to
Kobak and Parlow 1949	One	Triceps tendon	Many times	Irradiation	Axillary Nodes, Lungs and Viscera
Decker and Owen 1954	One	Ankle tendons	Twice	Amputation	Vertebrae, Lungs
Bliss and Reed 1968	Four	Hand	Many times	—	Distant organs

TABLE II
RADIOLOGICAL CHANGES

Author and Year	Cases	Site	BONY CHANGES		
			Pressure Erosion	Bony Destruction	Others
Fletcher and Horn 1951	8 out of 43	Hand	+	+	Cystic bone defects
Ackerman-et-al 1962	Few	Fingers and feet	+	—	—
Jones-et-al 1969	Half of 91	Hand	—	—	Degenerative joint changes
Sterm and Gauger 1977	One	Ring Finger	—	—	Sub-periosteal new bone formation
Beecher-et-al 1979	One	Foot	+	—	Punched out destruction of cuboid

Literature reports very rare malignant transformation of tendon sheath lesion with so called giant cell tumour character (Table 1).

Although uncommon, this lesion causes pressure erosion or cystic radiographic defect of adjacent bones in hand due to mechanical pressure (Table II).

However in our case a true tissue infiltration on the radial border of the proximal phalanx of thumb was found while excision, with pressure effect on volar aspect of the same bone.

Local excision is recommended although re-

currence is as high as 12 to 48% in different series. Wide local excision of both swellings has shown no clinical or radiological sign of recurrence for last 10 months of follow up in the present case. Rarely, local excision and radiotherapy in early malignant or amputation in a malignant tumour is recommended.

ACKNOWLEDGEMENT

I am grateful to Professor Krishnamurthy for his expert view on histopathology, Dr J.B. Patel for radiological opinion, Mr Ansari and Mr Jayasingha for

Medical Journal of Zambia

beautiful illustrations and Mrs Fostina Mwango for her Secretarial assistance.

REFERENCES

1. Ackerman, L.V., and del Regato, J.A. (1971): "Cancer: diagnosis, treatment and prognosis", C.V. Mosby Co., St Louis, U.S.A.
 2. Ackerman, L.V. and Spjut, H.J. (1962): *Tumours of Bone and Cartilage*, Armed Forces Institute of Pathology, Washington – 25 D.C.
 3. Beecher, J.L., Dockeray, G.C., Raja, R. (1979) *Proceedings of Association of Surgeons of East Africa*. 2:193.
 4. Jones, F.E., Soule, E.H. and Coventry, M.B. (1969): *The Journal of Bone and Joint Surgery*, 51-A: 76.
 5. Lichtenstein, L., (1972): "Bone Tumours", 4th Edition, The C.V. Mosby Co., St Louis, U.S.A.
 6. Stern, R.E. and Gaugers, D.W. (1977): *The Journal of Bone and Joint Surgery*, 59-A: 560.
 7. Willis, R.A. (1967): "Pathology of Tumour", Fourth Edition, The C.V. Mosby Co., St Louis, U.S.A.
-