

THE TREATMENT OF TIBIAL DIAPHYSIAL BONE DEFECTS IN ADULTS

*IZHAR U. HAQUE M.B., FRCS(Ed.) FICS

Summary

Twenty cases of established non-union of the tibial diaphysis with bone defects ranging from 2.5 centimetres to 7.5 centimetres (mean 3.5 centimetres), were treated between 1976 to 1981. In six cases complications were compounded by ipsilateral femoral shaft fractures and multiple other injuries. Previous operative attempts for reconstruction had been made on three cases. Average period from reconstructive operation to union was twenty three weeks with a range for eight to seventy-two weeks. Permanent limb shortening occurred in all the cases ranging from 2.5 centimetres to 7.5 centimetres (mean 3.5cms).

Among the various remedial techniques used obtaining union in nineteen cases, Posterolateral tibio-fibular synostosis emerged as the best salvage procedure in our environment with minimal hospitalisation and complications.

Introduction

Despite the availability of a wide range of techniques for treating tibial diaphysial fractures, non-union remains a common complication (Sakellarides, Freeman and Grant 1964). The high risk of non-union in open and comminuted fractures with severe soft tissue damage caused by high velocity trauma is well documented (Rosenthal, McPhall and Ortiz 1977).

This paper reports various techniques found useful in the treatment of complicated non-union with the tibial diaphysial bone defects in adults. No one method is suitable for all cases, selection of technique usually depending upon the type and site of the non-union and the associated complications.

Patients & Methods

Sixteen men and four women, who had established non-union of fractures of the tibial diaphysis with bone defects ranging from 2.5 centimetres to 7.5 centimetres were admitted under my care at the University Teaching Hospital, Lusaka between 1976 to 1981. The average age was thirty years with a range of sixteen to forty eight years.

Initial Trauma.

All patients had open and comminuted fractures with soft tissue damage. Seventeen fractures were due to automobile accidents, involving eleven pedestrians; one driver, three passengers and two motor cyclists. Two patients had fallen from height and one was involved in a landmine explosion.

In addition to the local complication there were ipsilateral femoral shaft fractures and other injuries involving head, thorax and abdomen in six patients and three had bilateral tibial fractures.

Previous Treatment

All these fractures were initially treated by debridement, skeletal traction through the os calcis and multiple skin grafting procedures. All but one of the ipsilateral femoral fractures were fixed internally with Kuntscher nails. One of these open tibial fractures had been plated elsewhere after healing of the wounds. The site became infected, exposing the plate and producing a sequestrum and established non-union.

Previous Surgery for Non-union

Three patients had previous attempts to treat non-union employing plating and cancellous graft, anterior hemicylindrical sliding graft and prolonged immobilisation on skeletal traction through os calcis with cancellous bone grafting of the defect.

Duration of Non-union

The average period from the initial fracture to the bone grafting operation was nine months with a range of three months to thirty months. One patient however underwent successful reconstruction after seven years of established non-union. Previous attempts to effect union in this case were made in 1973 and 1976 in a private clinic in London (England).

Methods of treatment

The following methods of treatment were used:-

A. Hemicylindrical sliding bone graft:

This procedure was selected for three patients. Good soft tissue and skin cover allowed an anterior approach in these cases.

*Consultant Orthopaedic Surgeon, University Teaching Hospital, P.O. Box 50110, LUSAKA, ZAMBIA

* Address for Correspondence — Hospital for Joint Diseases — Orthopaedic Institute, Bernard Aronson Plaza, 301.E-17th St. New York, NY 10003 U.S.A.

B. Posterolateral tibio-fibular synostosis.
This procedure was employed for eight of the most complicated, non-unions with large segmental defects and extensive soft tissue damage which precluded the use of anterior approaches.

C. Rigid Plating and Cancellous Bone Grafting.

This method was used for seven cases with bone defects ranging from 2.5cm to 3 centimetres, in whom antero-lateral approaches were feasible.

D. Immobilisation with the external fixator and cancellous bone grafting.

This method which is now extensively employed universally in cases with extensive soft tissue loss, was used in only one case in this series. It was found quite useful in a case of non-union of distal, shaft of tibia from which an infected plate and sequestrum had been removed.

E. Inlay cortico-cancellous bone grafting with plaster of Paris immobilisation.

This method was used for a non-union with 2.5 centimetres bone defect in the youngest patient in our series. The quality of soft tissues was poor on the medial aspect of the leg. Through a lateral approach, a bed was cut in the tibia to receive a five centimetre long cancellous block taken from the iliac crest. The leg was initially placed in a plaster of Paris back slab which was replaced by a complete cast after two weeks.

Results

A. In the three patients treated with hemicylindrical sliding bone grafts the non-union healed without complications in 12,13 and 24 weeks respectively (Figs. 1 & 2).

B. The patient who had been treated elsewhere with a sliding bone graft which failed because of infection, became the only failure in this series when treated by attempting a posterior tibio-fibular synostosis. The bone ends were sclerotic and deep infection was still present when he left the country for his home in Kenya. Possibly insufficient cancellous bone was used. In all other seven cases, the non-union was healed in average time of 23 weeks (range 14 weeks to 38 weeks); (Figs. 3,4,5,6,7 and 8).

C. All seven cases of non-union, treated by rigid plating with cancellous bone grafting, healed in an average time of 24 weeks (range 8 to 72 weeks).

D. The non-union treated by immobilisation with external fixator and cancellous bone grafting healed in 24 weeks.

E. The case treated with an "In-Lay" cancellous bone block and plaster immobilisation healed in 16 weeks (Fig. 9).

Functional Results.

The functional results were graded as:-

Excellent: When the fracture united without residual symptoms in the leg, shortening of less than 2.5 centimetres and knee flexion of over 120°. This result was obtained in eight patients.

Good: Indicated union with limb shortening of under three centimetres and knee flexion of at least 90° with ankle dorsiflexion to the neutral position. Six cases satisfied this standard.

Fair: This represented union with more than three centimetres shortening, angulation of less than ten degrees at the site of union, knee flexion upto sixty degrees; but the ability to walk without aids and without a pronounced limp. Six patients achieved this rating.

Poor: Residual non-union with persistent discharging sinuses, inability to walk without aids and presence of pronounced limp.

Complications

Complications were mostly associated with anterolateral rigid plating with or without compression, where split-skin grafting had been employed previously. Skin necrosis occurred in three patients exposing the plate partially in two, and almost completely in one. Union occurred in spite of this skin loss in two patients, and the skin healed after removal of the plates. The third patient developed cortical bone necrosis under the plate with deep infection. Sequestered bone was taken out after removal of some of the screws. This complication was probably due to pressure necrosis from over-compression.

This fracture eventually united after packing cancellous bone chips into the defect, but the original plate was retained throughout because it held the segments rigidly. This patient had the longest period (18 months) before obtaining union.

One patient treated elsewhere with a hemicylindrical sliding bone graft, developed deep infection causing sequestration of the whole graft. This is the only case which proved eventually

to be a total failure after attempted posterolateral tibiofibular synostosis. There were no postoperative complications in any of the remaining seven patients in whom this method was employed. The limited knee function seen in a few patients and the limb shortening in the majority of patients, were present before their reconstructive procedures were attempted. In two patients major problems resulted from infected Kuntscher nails in their ipsilateral femora while their complicated tibial non-unions healed after bone grafting.

Discussion

Many surgical procedures have been described to treat non-union with tibial diaphyseal defects. Every technique has its limitations. For non-union of closed fractures, without skin scarring and bone defects the following methods have been advocated:

1. Early weight bearing after fibular osteotomy with a patellar-tendon-bearing close-fitting plaster cast, (Brown and Urbar 1969).
2. Electrical and electro-magnetic stimulation to enhance union. This method is currently receiving much attention. The success rate in small series has been up to 70% (Brighton et al, 1977 and Jorgensen 1977).
3. Rigid osteosynthesis with compression. This technique is now well established and has proven its worth.

However, these methods are not applicable to patients with severely comminuted segmental fractures with soft tissue damage, extensive skin adherence and scarring and large bone defects. The choice of operation in such circumstances should depend upon individual preference and have regard to the site of the fracture, the size of the bone defect, the presence of infection and the extent of soft tissue damage. In such situations the following methods can be used:

1. **Rigid fixation and packing of the defect with cancellous bone.** This is not an ideal method in the presence of skin scarring and infection, but well-documented large series have been published by members of the Association for the Study of Internal Fixation (ASIF/AO) in which this method has been successful even in the presence of infection. It is now accepted that rigid fixation helps to control infection.
2. **The external fixator** — It is now quite popular especially for the treatment of fractures with soft tissue damage. Nursing care is facilitated and adjacent joints can be exercised while the fractures re-

main stable. Non-union may be treated by packing cancellous bone chips into bony defects after external fixation. Pin track infection is a common complication during prolonged use.

3. **Tibiofibular cross-peg grafting (McMaster and Hohl, 1975).** This has given good results, but needs extensive exposure. There is a risk of fracture at the donor site and 10% of cases needed supplementary bone-grafting.
4. **Hemicylindrical sliding cortical bone graft.** This can be a good salvage procedure in the proximal and distal segments of the tibia. Disadvantages are that, if infection occurs, it causes sequestration of a large segment of bone and there is also some danger of fracture at the donor site.
5. **Posterolateral tibiofibular synostosis with cancellous bone grafting.** This is an invaluable salvage approach in patients who have large segmental tibial defects with extensive skin scarring anteriorly, and in the presence of discharging sinuses, but it needs an intact fibula or a healed fibular fracture. Success rates have been reported ranging from 80% to 90% in large series. The main advantage is that it is a single non-destructive procedure with a high success rate. In addition the patient can be discharged in a plaster cast soon after operation and the method does not require special instruments. However it cannot be used to non-union of the proximal tibia because of the course of the posterior tibial vessels. In addition the long period of immobilisation in a plaster cast carries a risk of joint stiffness and muscle wasting.

Tibiofibular synostosis is not a simple procedure and needs careful attention to the anatomical landmarks but in our limited experience, it has proved to be the best salvage procedure for the most complicated non-unions. To reduce morbidity in cases of open comminuted tibial diaphyseal fractures with segmental loss and low-grade infection, this procedure may be employed as soon as the fibular fracture is united without waiting for healing of discharging sinuses. This pre-operative period can be further reduced by internal fixation of the fibular fracture and using posterolateral tibiofibular synostosis as a primary procedure (Reckling and Waters 1980).

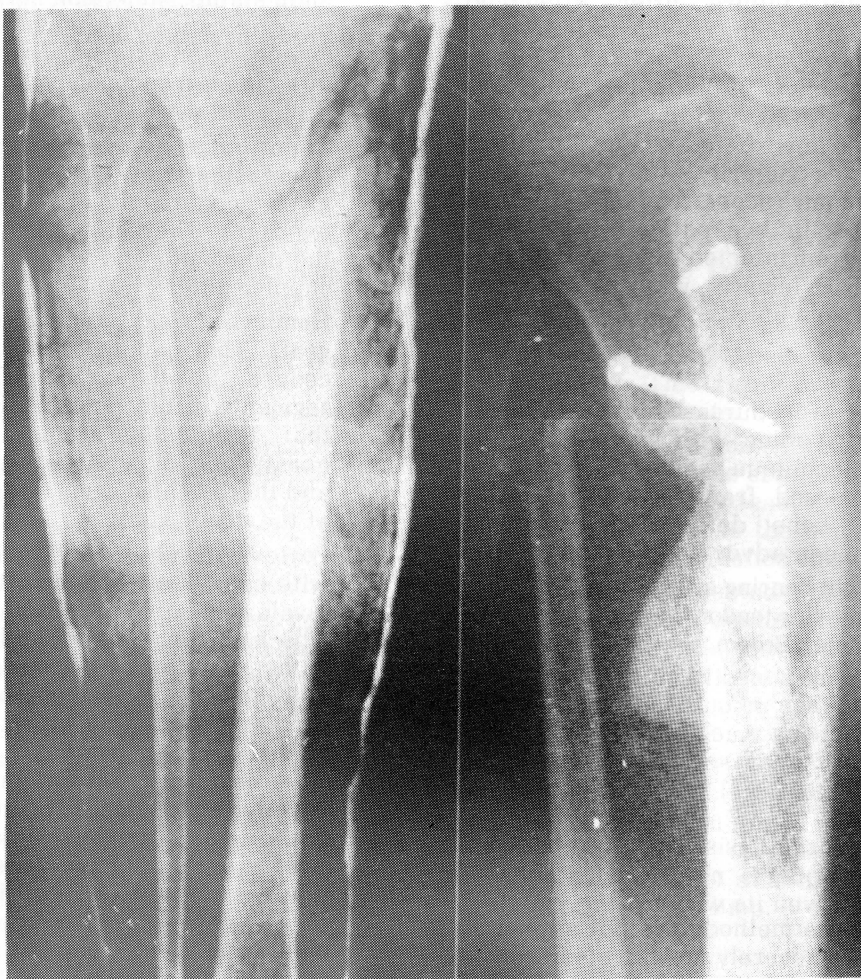

FIG. 1
High tibial bone defect successfully treated by hemicylindrical sliding graft.

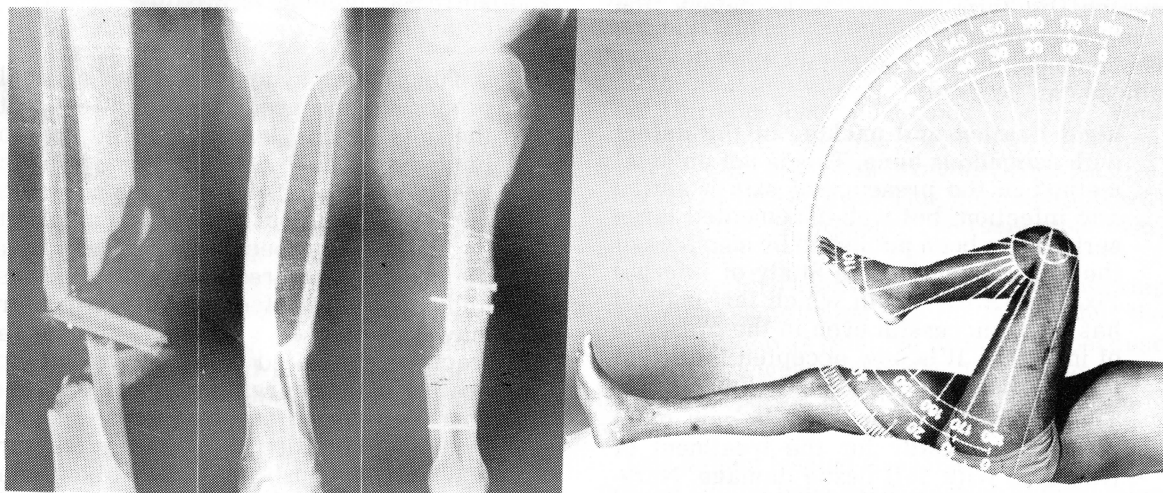


FIG. 2 A yawning gap in the lower tibial diaphysis bridged by hemicylindrical sliding graft with gratifying functional results.

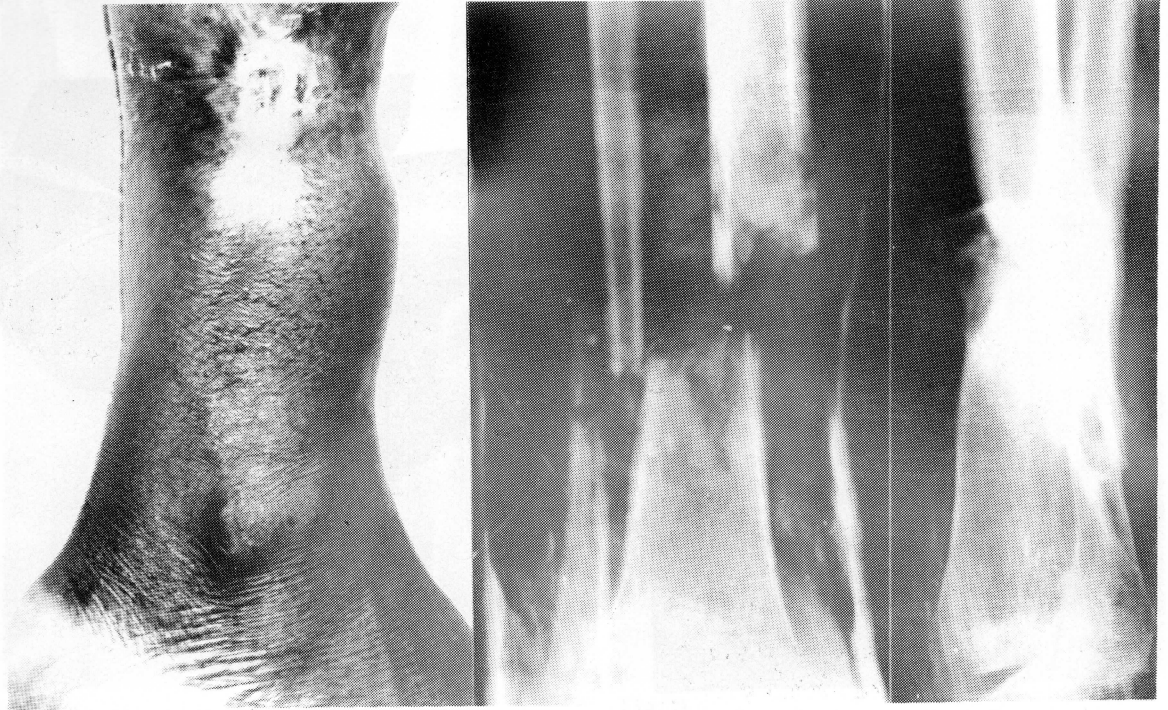


FIG. 3.
FIGS. 3,4,5,6,7 & 8 Some examples of tibial bone defects treated by postero-lateral tibio-fibular synostosis. Extensive antero-medial skin scarring and adherence precluding conventional antero-medial approaches is also demonstrated.

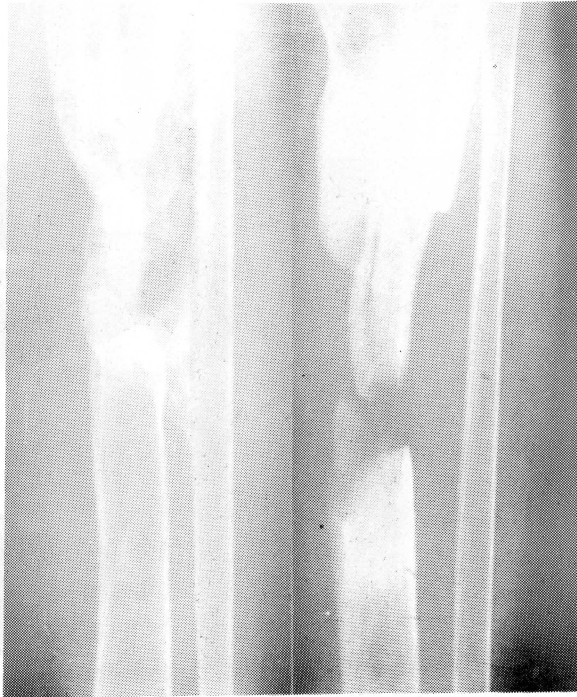

Fig. 4

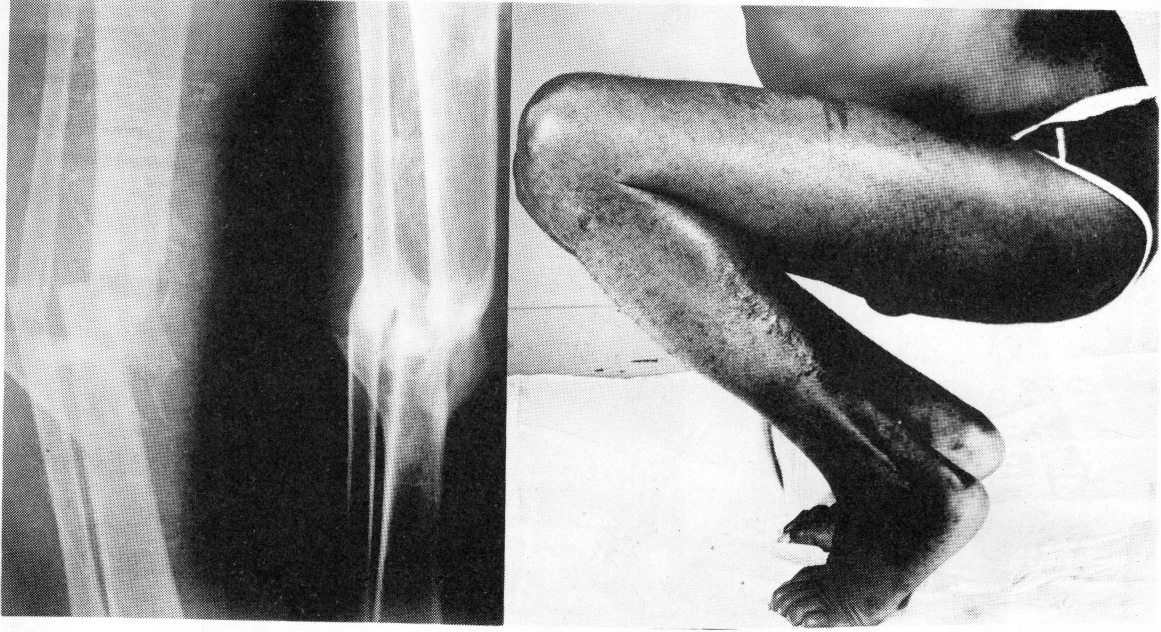

Fig. 5

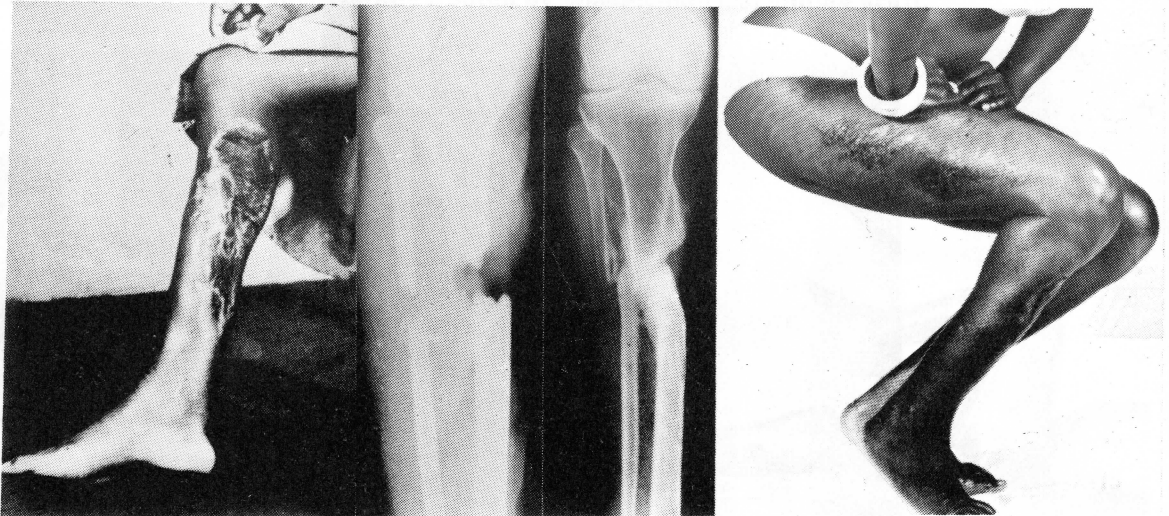


Fig. 6

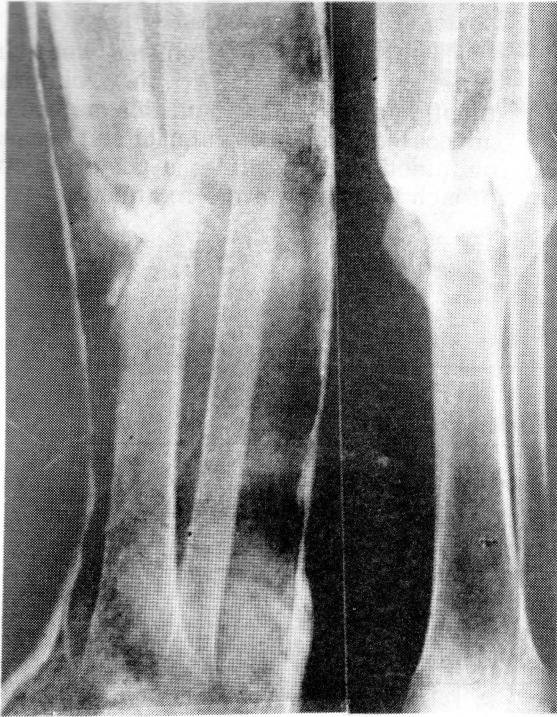

Fig. 7

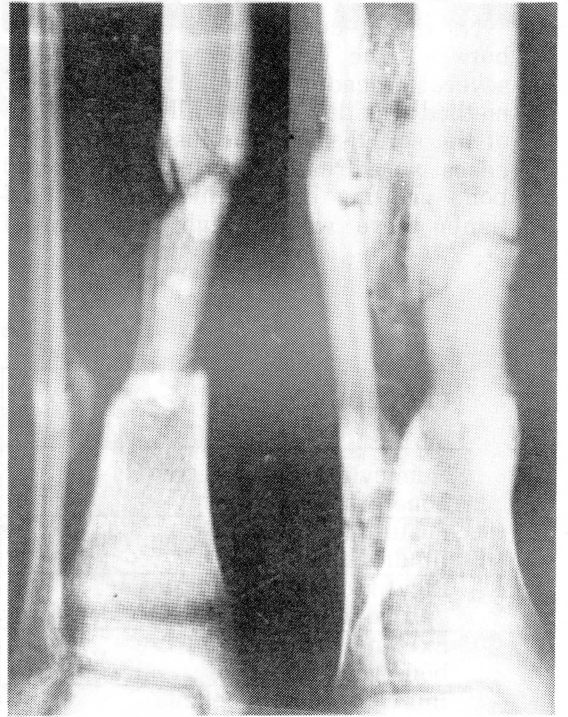

Fig. 8

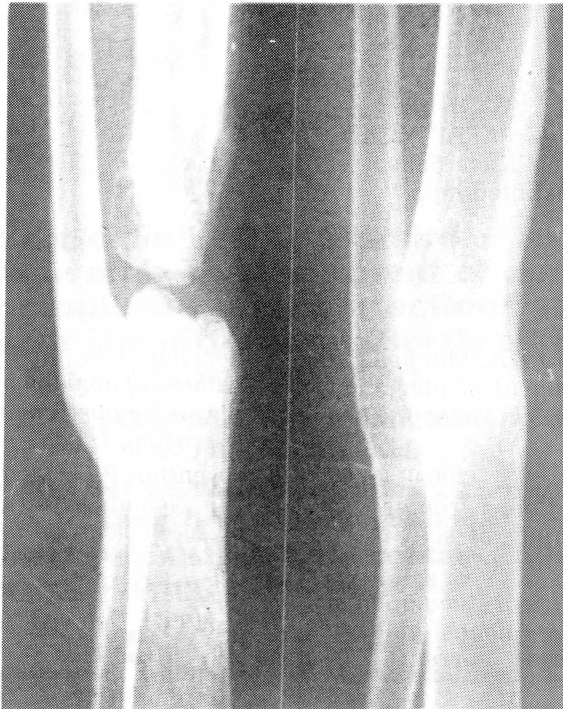

FIG. 9

A bone defect bridged by a large cancellous bone block and POP immobilisation in the youngest patient in this series.

No direct comparisons can be made between the functional results of the several procedures (Table 1) because the method was dictated usually by the state of the soft tissues. The less complicated cases were treated by rigid plating and bone grafting but in this group of patients there was a high incidence of

postoperative complications.

The most difficult problems were, in general, treated by posterolateral tibiofibular synostosis and this method is advocated when poor anterior soft tissues or infection necessitates a posterior approach without internal fixation.

TABLE 1

PROCEDURE	No. of Patients	Excellent	Good	Fair	Poor
Hemicylindrical sliding bone graft	3	1	—	2	—
Postero-lateral tibio-fibular synostosis	8	1	3	3	1
Rigid fixation with plates and bone grafting	7	4	2	1	—
External fixation and bone grafting	1	1	—	—	—
Inlay cortico cancellous bone grafting and plaster immobilisation	1	1	—	—	—

Acknowledgment

The author is indebted to Mr M.A. Ansary, Head of Medical Illustration Unit, School of medicine, Lusaka for his unstinted help.

References

- Brighton C.T., Friendenberg Z.B., Mitchell E.I. and Booth R.E. (1977) Treatment of non-union with constant direct current *Clin Orthopaedics* 124: 106-123.
- Brown P.W. and Urbar J.G. (1969) Early weight bearing treatment of open fractures of the tibia. An end result study of sixty-three cases *J. Bone Joint Surg.* 51 A: 59-77.
- Jorgensen T.E. (1977) Electrical stimulation in human fracture healing by means of slow pulsating asymmetrical direct current. *Clin Orthopaedics* 124: 124-127.
- McMaster P.E. and Hohl M (1975) Tibio-fibular cross-peg grafting *J. Bone Joint Surg.* 57 A: 720-721.
- Reckling F.W. and Waters III C.H. (1980) Treatment of non-union of fractures of the tibial diaphysis by posterolateral cortical cancellous bone-grafting *J. Bone Joint Surg.* 62 A:936-941.
- Rosenthal R.E., MacPhail J.A. and Ortiz J.E. (1977) Non-union in open tibial fractures. Analysis of reasons for failure of treatment *J Bone Joint Surg.* 59 A: 244-248.
- Sakellarides H.T., Freeman P.A. and Grant B.D. (1964) Delayed union and non-union of tibial shaft fractures *J Bone Joint Surg.* 46 A: 557-569.