

**PREVALENCE OF OCULAR MANIFESTATIONS OF HIV/AIDS AMONG  
PATIENTS ATTENDING ADULT INFECTIOUS DISEASE CENTRE (AIDC) OF  
EXCELLENCE AT THE UNIVERSITY TEACHING HOSPITAL IN LUSAKA,  
ZAMBIA**

**PHYLLIS MAKALA MOONGA**

**(MD)**

**Dissertation submitted to the University of Zambia in partial fulfillment of the  
requirements for the degree of Master of Medicine in Ophthalmology, Department of  
Surgery, School of Medicine.**

**THE UNIVERSITY OF ZAMBIA**

**LUSAKA**

**2017**

## **COPYRIGHT**

All rights reserved; no part of this dissertation may be reproduced, stored in a retrieval system or transmitted in any form by any other means, electronic, mechanical, photocopying or recording without prior consent from the author.

By Dr. Phyllis Makala Moonga

2017

## DECLARATION

I, PHYLLIS M. MOONGA hereby declare that this dissertation is a product of my own work and has never been submitted, in part or in full, for a diploma or a degree in any other university.

Date.....

Candidate.....

Sign

**CERTIFICATE OF COMPLETION OF THE DISSERTATION**

I, PHYLLIS M. MOONGA, hereby certify that this dissertation is a product of my own work and that it has never been submitted in part or whole to any other university.

Date.....

Student.....

Sign

I, Dr G.Chipalo-Mutati, having supervised and read this dissertation confirm that the work has been done satisfactorily and is ready for presentation.

Date.....

Supervisor.....

Sign

Date.....

(Head of department, School of Medicine,  
University of Zambia)

.....

Sign

## APPROVAL

This dissertation by **Phyllis M Moonga** is approved as partial fulfillment of the requirement for the award of the Master of Medicine (Ophthalmology) degree of the University of Zambia

1. Examiner's Name: .....

Date..... Signature.....

2. External Examiner's Name:.....

Date..... Signature.....

3. External Examiner's Name:.....

Date..... Signature.....

## ABSTRACT

Prevalence of ocular manifestations of HIV/AIDS among patients attending Adult Infectious Disease Centre (AIDC) of excellence at UTH, Lusaka. HIV and AIDS related ocular manifestations may affect 50-75% of HIV positive patients at some point in the course of their illness. Zambia has an HIV prevalence rate of 13.0%. This study was conducted in order to establish the prevalence and types of ocular manifestations in HIV/AIDS patients. This study was undertaken in order to determine the prevalence of ocular manifestations of HIV/AIDS in patients attending AIDC at UTH in Lusaka Zambia as well as to establish the types and categorize the HIV/AIDS ocular manifestations. Hospital based cross-sectional study. Adult Infectious Disease Centre (AIDC) of excellence at UTH, Lusaka.

A total of 385 HIV/AIDS patients attending routine clinic at the AIDC were randomly sampled and enrolled for the study. Patient's medical records were used to obtain information on age, sex, HIV stage and CD4-T cell count. Ophthalmic examination included visual acuity assessment, anterior segment examination with slit-lamp biomicroscope and posterior segment examination using indirect ophthalmoscope and with the help of a 20D lens. Histopathological examinations were conducted on the specimen excised from patients who had conjunctival growths that were suspicious for Squamous Cell Carcinoma (SCC). The Statistical Package for Social Scientists (SPSS) version 22 was used to store and analyze the data. Inferential statistics was performed and a  $p < 0.05$  was considered significant.

Ethical approval was obtained from UNZA Biomedical Research and Ethics Committee.

The prevalence of ocular manifestations in this study was 74.0%. Out of the 385 participants (64.0%) were female and (36.0%) were males. Three hundred and Seventy Three 373 (96.9%) participants were on HAART for an average period of 7.8 months. A total of 211 (54.8%) participants had CD4 T-cell count  $\geq 350$  cells/ $\mu$ L, 79 (20.5%) had CD4 T- cell count between 200-350, and 88 (22.9%) had CD4 T-cell count below 200 cells/ $\mu$ L.

The most common ocular manifestations were anterior segment seen in 89.6% which included Keratoconjunctivitis sicca 50.4% and conjunctival microvasculopathy 27.5%. Other manifestations were, retinal microvasculopathy, 8.8%, and uveitis, 6.0%. Cytomegalovirus (CMV) retinitis was noted in 2.1% of the patients and it was the cause of blindness in 1.6% of the participants. Age above 40 years was associated with an increase in the prevalence of ocular manifestations with a p-value of 0.000288.

The prevalence of ocular manifestations of HIV/AIDS at AIDC of excellence at UTH was 74.0%. These included anterior segment manifestations, 89.6%, posterior segment, 13.5%, adnexae, 6.0% and neuro-ophthalmic manifestations, 2.2%. In terms of specificity, the most common ocular manifestations noted were keratoconjunctivitis sicca, conjunctival microvasculopathy, retinal microvasculopathy, cataracts and uveitis.

## **DEDICATION**

I dedicate this work to my beloved husband Jagger, and my lovely children Joseph, Lois and Ethan. I could not have done this without your support, understanding and great love. Love you all.



## **ACKNOWLEDGEMENTS**

My acknowledgements go to Dr. Grace Chipalo – Mutati who has been of great help in my clinical learning and very instrumental in helping me, write this work from the beginning. Dr Fatson Liche, May His Soul Rest in Peace, who taught me what the world of ophthalmology really is and to take it as a lifestyle and not a career.

To the Kitwe eye annex personnel, for their great help and patience in shaping my surgical techniques.

To all the staff of UTH eye clinic, thank you for everything, without you, I would not have made it this far.

The staff and management at AIDC, for their support in helping me setup a temporal eye unit at the centre to conduct the study.

And lastly, to the pathologists at UTH, who helped in reading the specimen for histopathology.

## TABLE OF CONTENTS

<b>COPYRIGHT .....</b>	
<b>DECLARATION .....</b>	
<b>CERTIFICATE OF COMPLETION OF THE DISSERTATION.....</b>	
<b>APPROVAL .....</b>	
<b>ABSTRACT .....</b>	<b>IV</b>
<b>DEDICATION.....</b>	<b>VI</b>
<b>ACKNOWLEDGEMENTS.....</b>	<b>VII</b>
<b>TABLE OF CONTENTS.....</b>	<b>VIII</b>
<b>LIST OF FIGURES.....</b>	<b>X</b>
<b>LIST OF TABLES.....</b>	<b>XII</b>
<b>LIST OF APPENDICES.....</b>	<b>XII</b>
<b>ABBREVIATIONS AND ACRONYMS .....</b>	<b>XIII</b>
<b>CHAPTER ONE - INTRODUCTION.....</b>	
1.1 Introduction .....	1
1.2 Rationale.....	2
1.3 Objectives.....	2
1.3.1 Main Objective.....	2
1.3.2 Specific Objectives.....	2
<b>CHAPTER TWO – LITERATURE.....</b>	
2.1 Literature Review.....	3
2.1.1 Adnexal Manifestations.....	3
2.1.2 Anterior Segment Manifestations.....	4
2.1.3 Posterior Segment Manifestations.....	4
2.1.4 Orbital Manifestations.....	5
2.1.5 Neuro-Ophthalmic Manifestations.....	5
<b>CHAPTER THREE – METHODOLOGY .....</b>	
3.1 Methodology.....	6

3.1.1	Study Design.....	6
3.1.2	Study Durations.....	6
3.1.3	Study Variables.....	6
3.1.4	Study Setting .....	6
3.1.5	Study Population.....	6
3.1.6	Sample Size.....	7
3.2	Inclusion Criteria.....	7
3.3	Exclusion Criteria.....	7
3.4	Resource Personnel.....	7
3.5	Data Collection Procedure.....	7
3.6	Eye Examination Flow Chart.....	9
3.7	Data Management and Analysis.....	9
3.8	Ethical Approval.....	9
3.9	Data Confidentiality.....	9
<b>CHAPTER FOUR - RESULTS.....</b>		
4.1	Results.....	10
<b>CHAPTER FIVE- DISCUSSION.....</b>		
5.1	Discussion.....	21
<b>CHAPTER SIX - CONCLUSION .....</b>		
6.1	Conclusion.....	27
6.2	Recommendations.....	27
6.3	Limitations.....	27
<b>REFERENCES.....</b>		<b>28</b>
<b>APPENDICES.....</b>		<b>31</b>

## LIST OF FIGURES

<b>Figure 1:</b> Flow chart diagram showing response rate of the participants	11
<b>Figure 2:</b> Biographical characteristics of the participants	12
<b>Figure 3:</b> Distribution of ocular manifestations	15
<b>Figure 4:</b> The categories of ocular manifestation	16
<b>Figure 5:</b> Distribution of anterior segment manifestations	17
<b>Figure 6:</b> Distribution of CD4 T-cell count level	18
<b>Figure 7:</b> HIV stage and ocular manifestations	21

## LIST OF TABLES

<b>Table 1:</b> Characteristics of the participants	13
<b>Table 2:</b> Visual acuity	14
<b>Table 3:</b> Other parameters	14
<b>Table 4:</b> Adnexal manifestations	16
<b>Table 5:</b> Posterior segment ocular manifestations	17
<b>Table 6:</b> Summary statistics on HAART duration and CD4 T-cell count	19
<b>Table 7:</b> Distribution of the frequency on age and ocular manifestations	20
<b>Table 8:</b> Chi square test of age by ocular manifestations	20
<b>Table 9:</b> summary of the study variables	20
<b>Table 10:</b> Comparison of results in this study with studies done in other African countries	24
<b>Table 11:</b> comparisons of results in this study with studies done elsewhere in the world	25

## LIST OF APPENDICES

<b>Appendix I:</b> Patient information sheet	31
<b>Appendix II:</b> Consent form	34
<b>Appendix III:</b> Questionnaire	39
<b>Appendix IV:</b> WHO visual impairment classification	41
<b>Appendix V:</b> Photographs showing some of the encountered ocular manifestations	42

## **ABBREVIATIONS AND ACRONYMS**

<b>AIDC</b>	Adult Infectious Diseases Centre
<b>AIDS</b>	Acquired Immunodeficiency Syndrome
<b>ARV</b>	Antiretroviral
<b>CMV</b>	Cytomegalovirus
<b>CSO</b>	Central Statistics Office
<b>EOM</b>	Extra Ocular Motility
<b>HAART</b>	Highly Active Antiretroviral Therapy
<b>HIV</b>	Human Immuno-deficiency Virus
<b>HS</b>	Herpes Simplex
<b>HZO</b>	Herpes Zoster Ophthalmicus
<b>IOP</b>	Intraocular Pressure
<b>KPS</b>	Keratic Precipitates
<b>RVD-NR</b>	Retroviral disease-Non Reactive
<b>RVD-R</b>	Retroviral disease-Reactive
<b>SCC</b>	Squamous Cell Carcinoma
<b>TB</b>	Tuberculosis
<b>UNZA</b>	University of Zambia
<b>UNZABREC</b>	University of Zambia Biomedical Research Ethical Committee
<b>UTH</b>	University Teaching Hospital
<b>WHO</b>	World Health Organization

## CHAPTER ONE: INTRODUCTION

### 1.1 Introduction

HIV and AIDS related ocular manifestations may affect 50-75% of human immunodeficiency positive individuals (Kestelyn, 2001) . At the moment there are approximately 34 million people in the world that are living with HIV infection (Kestelyn and Cunningham Jr, 2001) and sub-Saharan region has the highest number of people living with HIV and AIDS approximating 25.8 million in 2014, it also accounts for almost 70.0% of the global total of the new infection (WHO media centre, 2015). The prevalence of HIV infection in Zambia is 13.0% among adults in a population of 13,092 666 (Central statistics, 2013). With this high prevalence it is important to know the types of ocular manifestation in these patients, because some of them can lead to blindness. This study was conducted in order to find out the prevalence of ocular manifestation of HIV/AIDS and to categorize them, as there is scanty information on the subject.

Causes of visual loss in patients with HIV/AIDS include CMV retinitis, Toxoplasma chorioretinitis, uveitis and optic nerve disease (Otit-Sengeri et al., 2010). CMV retinitis is the most common opportunistic infection, representing 90.0% of all infectious retinitis; about 20-30.0% of patients with AIDS develop CMV retinitis during the course of illness. It usually occurs in the late stages of the disease in patients with a lower limit of CD4 T-cell levels below 50cells/ $\mu$ L (Cho et al., 2010).

Prior to the introduction of Highly Active Antiretroviral Therapy (HAART), patients often experienced loss of vision due to CMV retinopathy, herpes virus retinopathy and other infectious ocular diseases such as toxoplasmosis, syphilis and cryptococcal (Holland et al., 1983). HAART has reduced the incidence of opportunistic infections, increased the time of remissions, reduced the complications of CMV and has allowed the discontinuation of anti-CMV medications and induces spontaneous regression of KS (Mowatt, 2013).



## **1.2 Rationale**

There is scanty information on the prevalence of ocular manifestations of HIV/AIDS in HIV/AIDS patients in Zambia. This study was undertaken in order to establish the prevalence on ocular manifestations of HIV/AIDS and to categorize them.

The prevalence of HIV in Zambia is estimated to be approximately 13.0% (Central statistics, 2013), and ocular manifestations in HIV are seen in 50% to 75% of patients with HIV/AIDS (Kestelyn, 2001). Therefore, it is necessary to know the types of ocular manifestations in HIV/AIDS patients. The information from the study will be used for advocacy and sensitization among health workers, policy makers and the general population on the importance of regular eye examinations of patients with HIV/AIDS.

## **1.3 Objectives**

### **1.3.1 Main objective**

To determine the prevalence of ocular manifestations of HIV/AIDS in patients attending the AIDC at the University Teaching Hospital (UTH), in Lusaka.

### **1.3.2 Specific objectives**

1. To establish the types of ocular manifestations of HIV/AIDS in adults attending the AIDC of excellence at UTH.
2. To categorize the most common ocular manifestations of HIV/AIDS at AIDC, UTH

## **CHAPTER TWO: LITERATURE REVIEW**

### **2.1 Introduction**

HIV/AIDS can affect any part of the eye namely the adnexae, anterior segment, posterior segment, orbits and neuro-ophthalmic structures. It has been noted that ocular complications in HIV and AIDS are common affecting 50-75%, of all such patients at some point during the course of their illness (Kestelyn and Cunningham Jr, 2001). Between 10-20% of HIV infected patients worldwide can be expected to lose vision, as a result of ocular CMV retinitis. Cytomegalovirus retinitis is by far the most frequent cause of vision loss in patients with AIDS. The prevalence of CMV retinitis has decreased in industrialized countries because of the widespread availability of HAART. Less frequent, but important causes of bilateral vision loss in patients with HIV/AIDS include, retinitis secondary to Varicella zoster virus, herpes simplex, HIV-related microvasculopathy, ocular syphilis, ocular TB, cryptococcal meningitis, ocular toxic and allergic reactions (Kestelyn and Cunningham Jr, 2001).

#### **Adnexal manifestations**

The ocular adnexa include the eyelids, conjunctiva and lacrimal drainage system. The most common complications affecting these structures are; Herpes zoster, KS, molluscum contagiosum, conjunctival growths and conjunctival microvasculopathy. (Cunningham Jr and Margolis, 1998). The other adnexal manifestations seen are; blepharitis, KS multiple molluscum contagiosum and herpes zoster (Kanski and Bowling, 2011).

In one study it was noted that HZO affected 5-15% of patients with HIV, while molluscum contagiosum was the most common adnexal manifestation affecting 15-18% of HIV patients (Charu et al., 2013). Another study done in India reported blepharitis occurring in 38.7% of HIV patients, followed by conjunctivitis and molluscum contagiosum at 13.6% and 6.8% respectively (Attili et al., 2006). In 2013, Lestari et al in Jakarta Indonesia found that dry eye was the most common ocular manifestation with the prevalence of 54.0% (Lestari et al., 2013).

In a study done in Ethiopia the adnexal manifestations noted were HZO, 5.6%, molluscum contagiosum, 4.8% and conjunctival squamous cell carcinoma in 4% (Assefa et al., 2016). In a cross sectional study of 409 HIV patients at two hospitals in Kenya it was discovered that,

conjunctiva squamous cell carcinoma was present in 7.8% of the patients with HIV/AIDS (Chisi et al., 2006).

### **Anterior segment manifestations**

The anterior segment includes the cornea, anterior chamber, iris and lens. Anterior segment manifestations have been noted in up to 50.0% HIV infected individuals and these are conjunctival microvasculopathy observed in up to 70.0%, SCC, keratitis and keratoconjunctivitis. (Shukla et al., 2007),

The most prevalent anterior segment manifestations of HIV include keratoconjunctivitis sicca 10-20%, keratitis caused by herpes simplex and herpes zoster viruses and iridocyclitis (Cunningham Jr and Margolis, 1998). Other anterior segment manifestations are conjunctival KS, SCC, microvasculopathy, keratitis due to herpes simplex and herpes zoster, keratoconjunctivitis sicca and anterior uveitis (Kanski and Bowling, 2011).

In a cross sectional study done in Ethiopia involving 380 HIV patients it was noted that keratoconjunctivitis was present in 11.5% and conjunctival microvasculopathy was seen in 2.3% of patients (Bekele et al., 2013). In Nigeria a study reported keratoconjunctivitis in 2.5%, corneal keratitis in 2.5% and iridocyclitis also in 2.5% of the HIV positive patients (Emina and Odjimogho, 2010).

### **Posterior segment manifestations**

The posterior segment includes the retina, choroid and optic nerve head. Diagnosis of the ocular manifestations affecting the posterior segment is usually based on characteristic clinical findings observed on dilated fundus examination with the use of either indirect ophthalmoscope or slit-lamp biomicroscope with the aid of magnifying lenses. The symptoms include floaters, flashes of light, decreased visual acuity and visual field defects.

Microangiopathy, HIV retinopathy, CMV retinitis, Progressive outer retinal necrosis (PORN), choroidal pneumocystosis, toxoplasmosis and B-cell intraocular lymphoma are among the posterior segment manifestations of HIV/AIDS (Kanski and Bowling, 2011). Other posterior segment manifestations are CMV retinitis 30-40%, varicella zoster virus reported in 1-4%, toxoplasmosis in 1-2% of patients with HIV/AIDS (Cunningham Jr and Margolis, 1998).

A study in South Korea, found that 11.5% of HIV patients had microangiopathy, 11% had CMV retinitis and 0.5% had PORN (Kim et al., 2015). In a study on ocular manifestations of HIV in Papua New Guinea and Southport in Australia, they found cotton wool spots, retinal haemorrhages, microvascular abnormalities and CMV retinitis as the most common posterior segment manifestations (“Verma N, Kearney J. ocular manifestations in AIDS. pdf - Google Search,” n.d.). In a similar study done in Malaysia, microangiopathy was reported in 89.0% and CMV retinitis in 11.0% (Loo et al., 2011). In Hungary, a study involving 348 HIV patients found that 42.0% of HIV patients had posterior segment manifestations of which 22.9% had HIV microangiopathy (Cho et al., 2010).

Studies done in the region reported common manifestations of HIV related retinopathy 24.0% and uveitis 24.0%.(Tarilah et al., 2013) while in Tanzania it was found that microvasculopathy was present in 25.0% of HIV patients, followed by CMV retinitis in 7.0% of patients. (Sahoo, 2010).

### **Orbital manifestations**

Orbital manifestations of HIV/AIDS are uncommon, the most common orbital manifestations are orbital lymphoma and orbital cellulitis (Cunningham Jr and Margolis, 1998). In a study done in India it was reported that orbital cellulitis was found in 2.3% of HIV patients (Rajkumari et al.,2013).

### **Neuro-ophthalmic manifestations**

The neuro-ophthalmic manifestations are seen in 10-15% of HIV patients (Freeman et al., 1995). These include visual field defects, nerve palsies and papilloedema. Common causes include cryptococcal meningitis, cerebral toxoplasmosis, intraocular lymphoma and neurosyphilis.

Papilloedema results from elevated intracranial pressure. Cranial nerve palsies and ocular motility disorders are other significant findings in patients with HIV/AIDS (Cunningham Jr and Margolis, 1998). The neuro-ophthalmic complications occur in 10-15% of HIV patients and develop as a result of CNS infections or neoplastic processes such as cryptococcal meningitis, cerebral toxoplasmosis and lymphoma (Kedar et al., 2012).

## **CHAPTER THREE: METHODOLOGY**

### **3.1 Methodology**

#### **3.1.1 Study design**

This was a hospital based cross-sectional study

#### **3.1.2 Study duration**

The study was conducted over a period of 4 months

1. Baseline data collection-2 months (mid-October to mid-December 2016)
2. Data analysis and presentation-2 months (January-February 2017)

#### **3.1.3 Study variables**

##### **1. Independent variables**

Age

Sex

HIV stage

CD4 T-cell count

##### **2. Dependent variable**

Ocular manifestations

#### **3.1.4 Study setting**

The study was conducted Adult Infectious Disease Centre (AIDC) of excellence which is at the University Teaching Hospital a tertiary hospital. AIDC manages HIV/AIDS adult patients (18years and above), who are mostly referred from the other hospitals and clinics. They have a data base of over ten thousand patients. Patients were enrolled and examined on the same day and in the same place. A temporary eye clinic was set up in the AIDC so that patients did not have to get an appointment for another day and also they did not have to move from place to place for the examinations.

### **3.1.5 Study population**

HIV positive patients aged 18 years and above attending the AIDC of excellence during the study period were examined.

### **3.1.6 Sample size**

The sample size was determined by the following formula.

$$n = Z^2 * P (1-P) / D^2$$

n- Sample required

Z- Z statistic (usually 1.96)

P- Expected prevalence =50%

D-Precision %

$$n = 384$$

### **3.2 Inclusion criteria**

1. All HIV/AIDS patients attending AIDC at UTH.
2. Patients who gave consent.
3. Adult patients 18 years and above, this is the age group of patients attending AIDC

### **3.3 Exclusion criteria**

1. Diabetic patients due to similarity in the retinopathy with HIV retinopathy
2. Hypertensive patients

### **3.4 Resource personnel**

The following people were involved at various stages of the study:

Registrar ophthalmology, ophthalmic nurse, Clerk, Theatre personnel, Histopathologist, Biostatistician and Typist. Consultant ophthalmologists confirmed the findings in case of doubt.

### **3.5 Data collection procedure**

Patient recruitment was done on each clinic day, by simple random sampling. This was done using a web-based tool for simple random sampling.

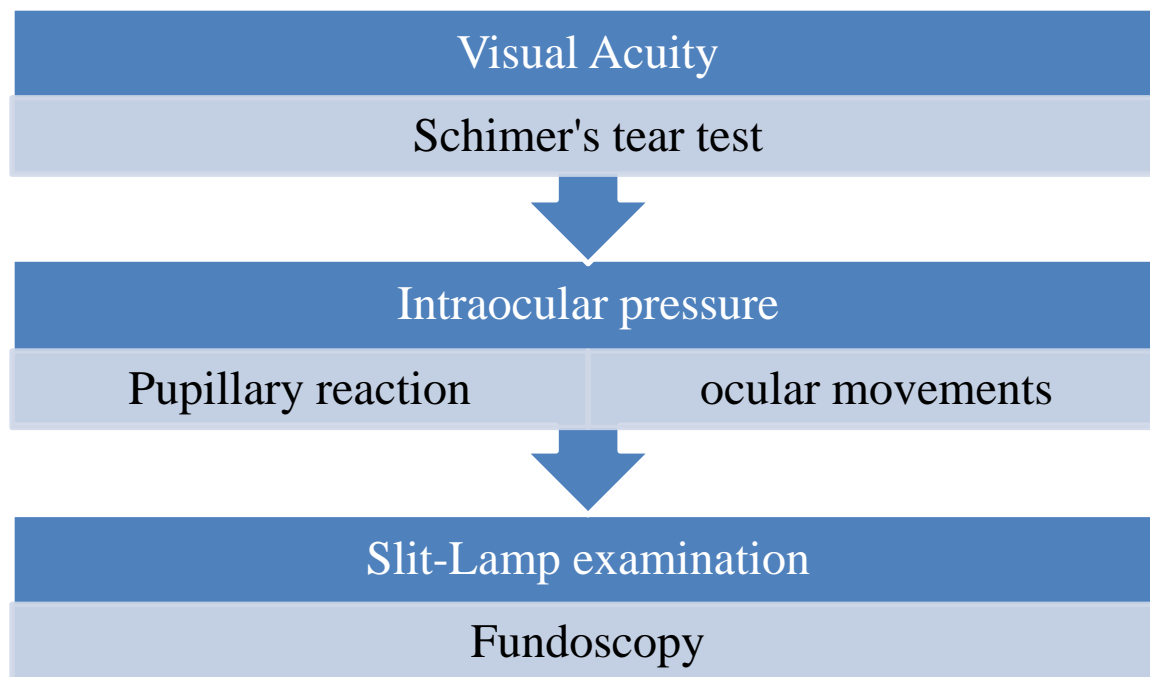
Informed consent was obtained from each study participant prior to participation in the study. The study was explained to the participants in the language they understand (chinyanja) to those who do not understand English. They were given a chance to ask any questions they had regarding the study.

Data was collected using interview, clinical examination and laboratory investigation. The interview was conducted by the principle investigator. The tools used for examination included Snellen's visual acuity charts, Shirmer's test strip, non-contact tonometry (pulsair), slit-lamp biomicroscope, 20D volk lens, 90D volk lens and a binocular indirect ophthalmoscope.

For funduscopy, the eyes were dilated using Tropicamide 1.0% with and without Phenylephrine. Histopathologic examinations were conducted in suspected cases of ocular squamous cell carcinoma.

Demographic data, HIV status, CD4-Tcell count and HIV stage were collected from medical records and as well as direct interviews.

### 3.6 Eye examination flow chart



The above figure shows how patient's examination was conducted

### 3.7 Data management and analysis

The data was collected using a well structured questionnaire (closed ended). The statistical package for social sciences (SPSS) version 22 was used to store and analyze the data. A P value of less than 0.05 was considered statistically significant.

### 3.8 Ethical approval

Ethical approval for the study was obtained from the University of Zambia Biomedical Research Ethics Committee. Permission letters to carry out the study were obtained from UTH and AIDC.

### 3.9 Data confidentiality

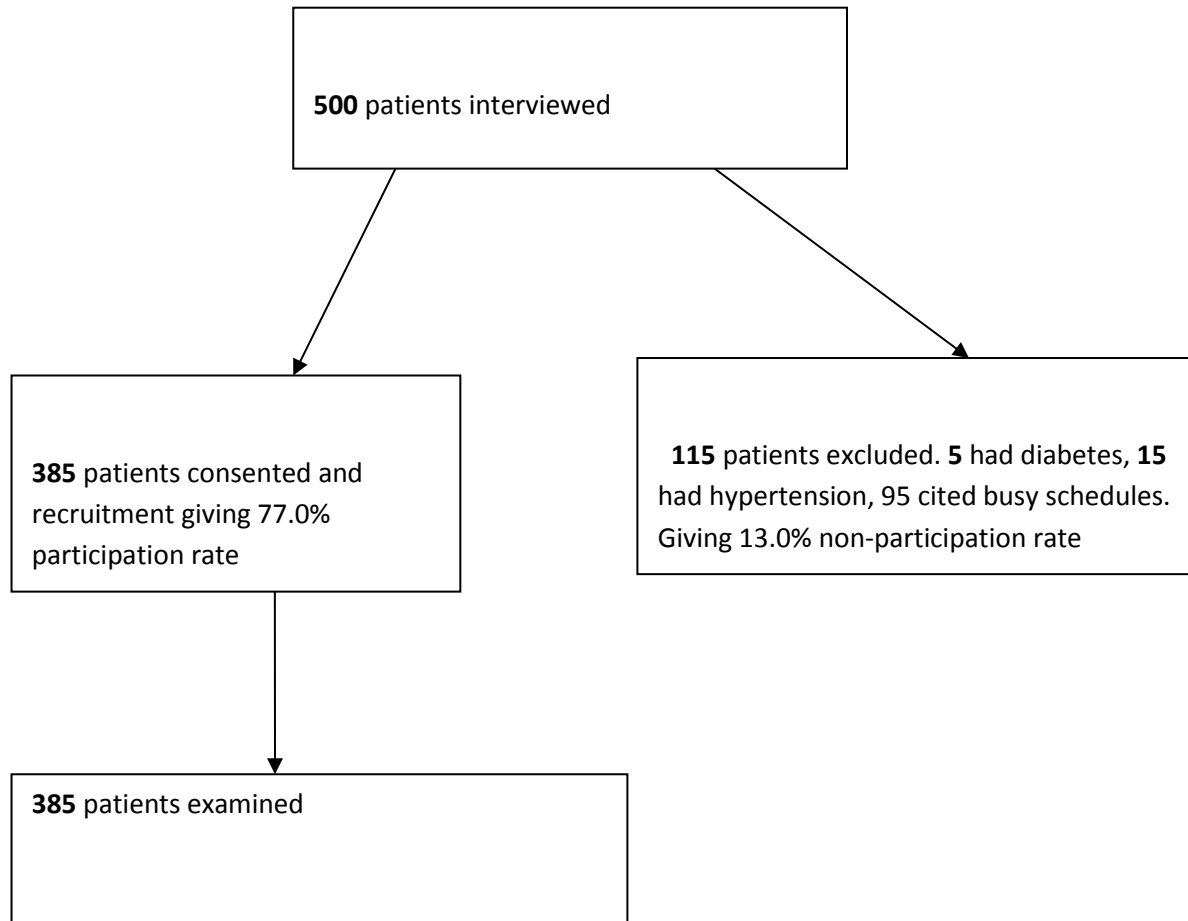
Data collected from the patients throughout the process was kept confidentially in a lockable cabinet, and only the principal investigator had access to it. Patient names and file numbers were not used when collecting data.



## CHAPTER FOUR - RESULTS

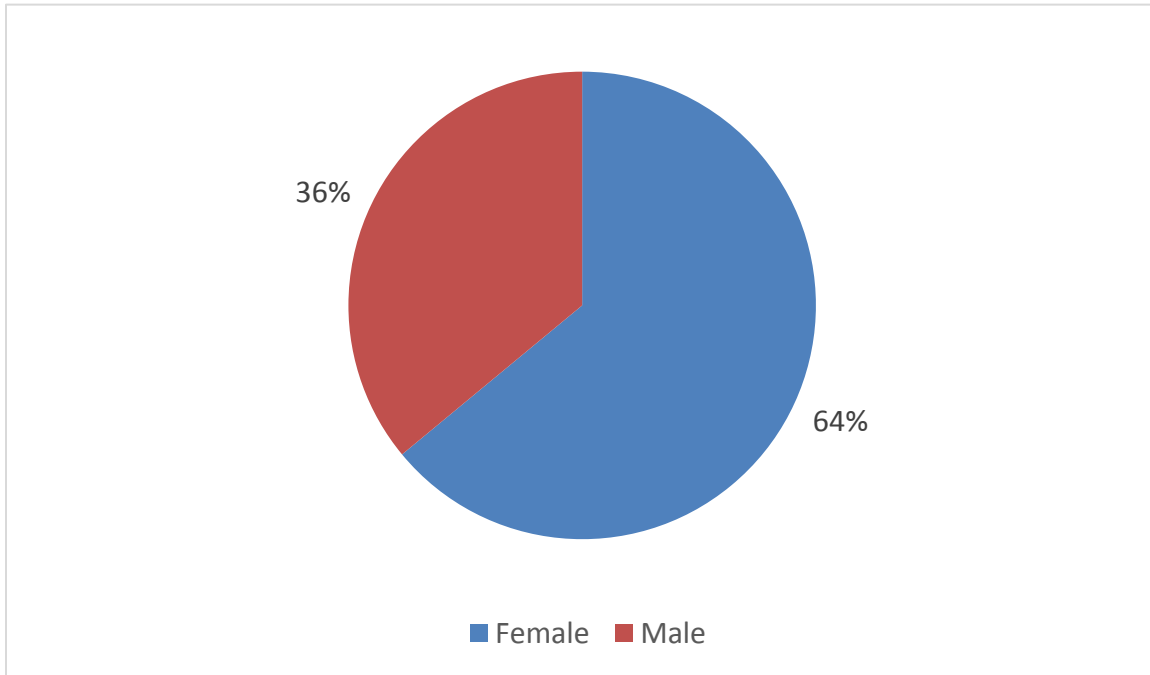
### 4.1 Results

In this study a total of 385 patients, attending AIDC at UTH were enrolled between October, 2016 to December, 2016.



**Figure 1: Flow chart diagram showing response rate of the participants.**

A total of 500 patients were enrolled but only 385 consented giving a response rate of 77.0%.



**Figure 2: Biographical characteristics of the participants**

The pie Chart above shows sex distribution. There were more females 64.0% than males.

**Table 1: Characteristics of the participants**

<b>Characteristics n=385</b>	<b>n (%)</b>
<b>Marital Status</b>	
Married	196 (50.9%)
Widowed	83 (21.6%)
Single	59 (15.3%)
Divorced	47 (12.2%)
<b>Level of education</b>	
None	14 (3.6%)
Primary	56 (14.5%)
Secondary	191 (49.6%)
Tertiary	124 (32.2%)
<b>Employment Status</b>	
Employed	294 (76.4%)
Unemployed	30 (7.8%)
Students	11 (2.8%)
Retired	50 (13%)

The table above shows the demographic characteristics of the participants. Majority of the study participants were married 50.9%. About 49.6% of the participants had attained secondary education and about 76.4% were employed.

**Table 2: Visual acuity**

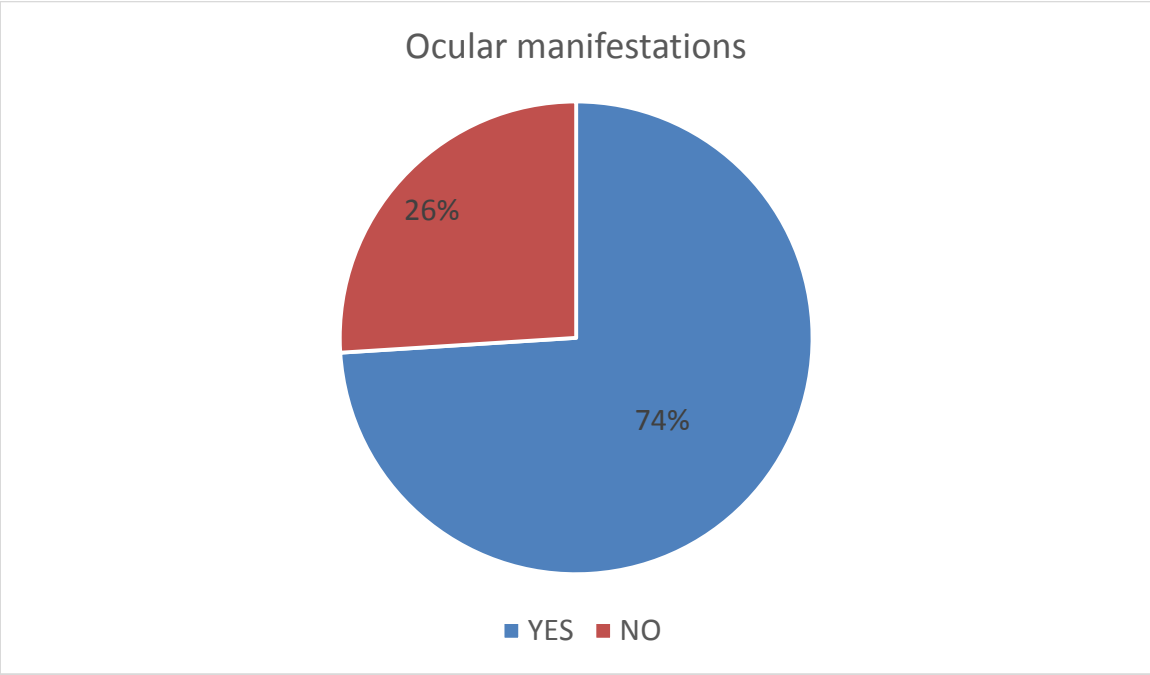
<b>Best corrected VA with pinhole</b>		<b>n (%)</b>
Normal VA	6/6-6/18	357 (92.7%)
Visual impairment	<6/18-6/60	14 (3.6%)
Severe visual impairment	<6/60-3/60	8 (2.1%)
Blindness	<3/60	6 (1.6%)

The above table shows the results of visual acuity. With regard to VA corrected 357 (92.7%) of the participants had normal vision, while a total of 14 (3.6%) participants had moderate visual impairment; 8 (2.1%) had severe visual impairment; and 6 (1.6%) were blind.

**Table 3: Other parameters**

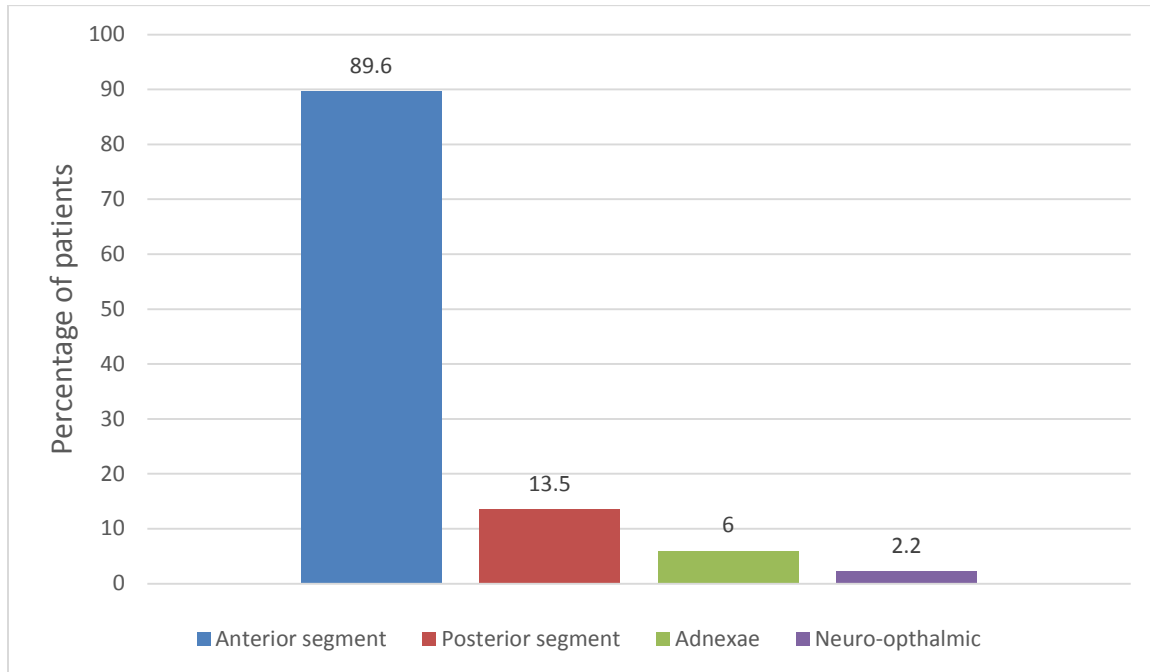
<b>Parameter</b>	<b>Normal</b>	<b>Abnormal</b>
Pupillary reaction	380 (98.7)	5 (1.3%)
Extra ocular motility	382 (99.2%)	3 (0.8%)
Intraocular pressure	381 (99%)	3 (0.8%)

Pupillary reaction in 1.3% of participants was abnormal due to posterior synechiae secondary to uveitis. Extra ocular motility was restricted in 0.8% participants, 0.5% had lateral rectus palsy while 0.3% had isolated medial rectus palsy. IOP was raised in 0.8% patients, due to glaucoma. Patients had cup-disc ratio of 0.9 and they had visual field defects on peripheral visual fields. IOP in one patient could not be done due to extensive HZO eruptions with swollen eyelids.



**Figure 3: Distribution of ocular manifestations**

The figure above shows the prevalence of ocular manifestations in the study population at 74.0%.



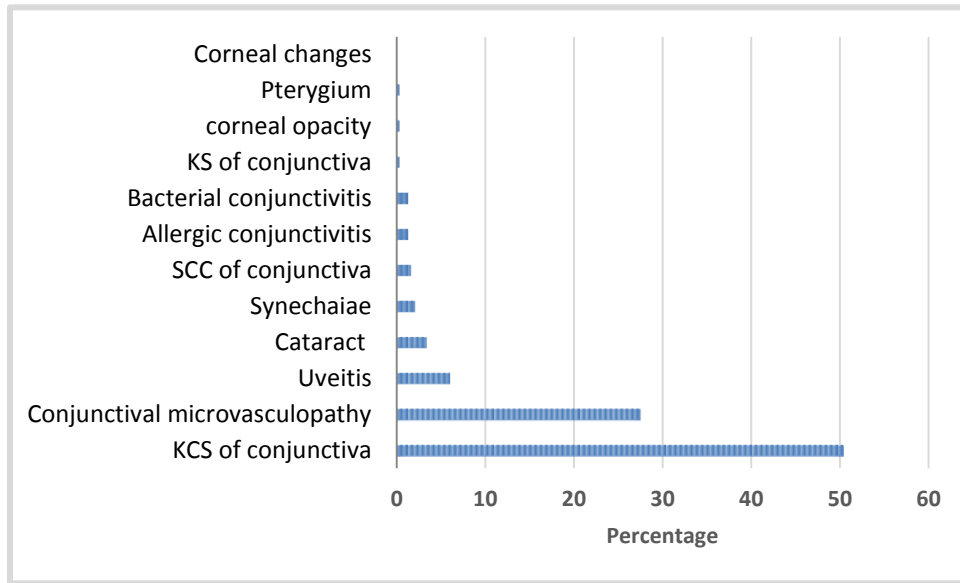
**Figure 4: The categories of ocular manifestations**

The figure above shows the categories of ocular manifestations. Anterior segment manifestations were the most common (89.6%) while neuro-ophthalmic were the least prevalent (2.2%)

**Table 4: Adnexal manifestations**

Type of manifestation	n (%)
HZO	11 (2.9%)
Blepharitis	3 (0.8%)
Molluscum contagiosum	2 (0.5%)
Herpes simplex	2 (0.5%)
Kaposi sarcoma	1 (0.3%)
Squamous cell carcinoma	1 (0.3%)

Adnexal manifestation presented as shown in the table above of which the most common presentation was HZO at 2.9%.



**Figure 5: Distribution of anterior segment ocular manifestations**

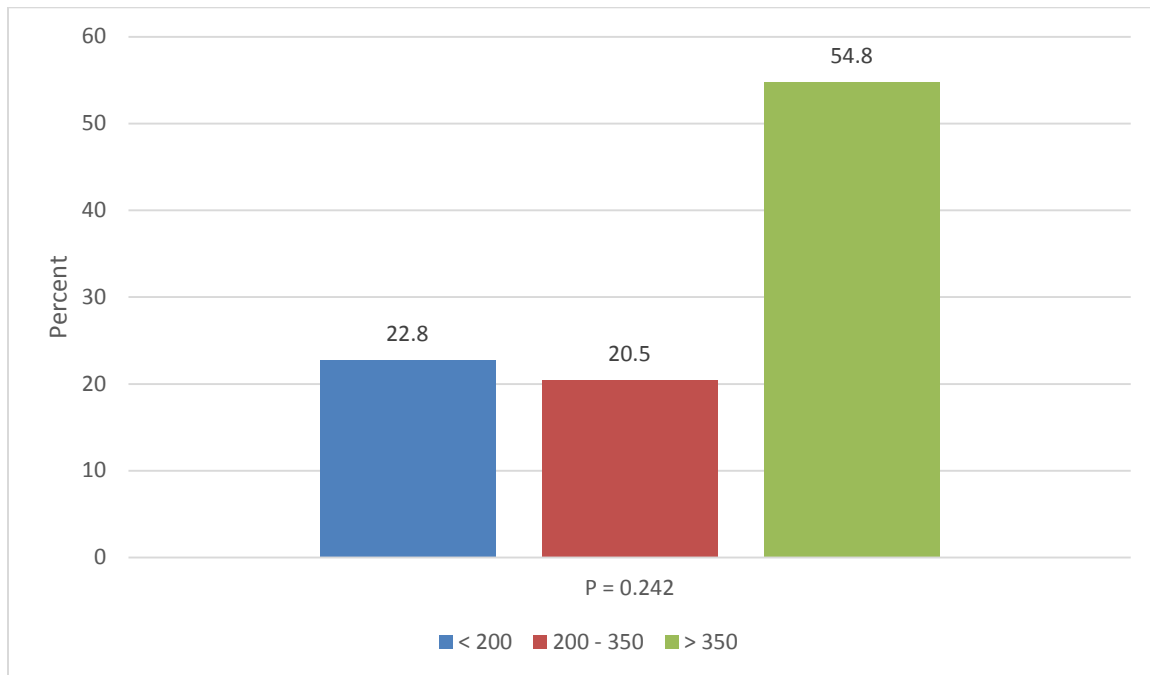
The anterior segment manifestations were noted in 89.6% of the participants. The above table shows the types of presentations reported in this study of which the most common manifestations were keratoconjunctivitis sicca at 50.4% and conjunctival microvasculopathy at 27.5%. Other anterior segment manifestations were posterior synechiaiae at 2.8%, severe allergic conjunctivitis at 1.4%, bacterial conjunctivitis at 1.4%. Anterior uveitis was present in 6.0% of the patients, and one of these patients had increased IOP secondary to the active uveitis with posterior synechiaiae causing pupillary block glaucoma.

**Table 5: Posterior segment ocular manifestations**

Type of manifestation	n (%)
Retinal microvasculopathy	34 (8.8%)
CMV retinitis	8 (2.1%)
Toxoplasmosis	2 (0.5%)
Choroiditis	2 (0.5%)

Other posterior segment manifestations seen were chorioretinitis 0.5%, CRAO in 0.5%, and Panuveitis in 0.3%. Retinal detachment was noted at 0.3% and PORN at 0.3%.

The neuro-ophthalmic manifestations were nerve palsies in 3 (0.8%) of which 0.5% presented as lateral rectus palsy while 0.3% presented as an isolated medial rectus palsy. Optic nerve atrophy was seen in 3 (0.8%) of the participants.



**Figure 6: Distribution of CD4 – T cell count categories**

The figure above shows the categories of CD4 levels.

The minimum CD4-T cell count was 1cell s/ $\mu$ L while the maximum was 1524 cells/ $\mu$ L, the average CD4-T cell count was 417.8 cells/ $\mu$ L (SD=169.587). Eighty eight 88 (22.9%) participants had CD4-T cell count less than 200 cells/ $\mu$ L, while 79 (20.5%) had between 200-350 cells/ $\mu$ L CD4-T cell counts and 211 (54.8%) had CD4-T cell count greater than 350 cells/ $\mu$ L. A total of 7 (1.8%) patients did not have CD4-T cell count results as the laboratory had operational challenges at the time of the study.



**TABLE 6: SUMMARY STATISTICS ON HAART DURATION AND CD4-T CELL COUNT**

	Mean	Median	Mode	Std. Deviation	Range	Minimum	Maximum
HAART (months)	7.7805	7.0000	12.00	16.23334	308.95	.05	309.00
CD4-T cell count	417.87	400	332	169.587	1524	1	1524

Three hundred and seventy-seven (97.9%) participants were on HAART while 8 (2.1%) were not on HAART. The duration of HAART ranged from less than one month to 309 months. Most participants 96.9% had been on HAART for 12 months for an average of 7.8 months, and this may be the reason why the study noted high prevalence of ocular manifestations

**Table 7: Distribution of the frequency of ocular manifestations by age**

		Is there ocular manifestation?			
		Yes	No	Total	
Age	18-40	Frequency	69	43	112
		Expected Count	83.1	28.9	112.0
		% within Age	61.6%	38.4%	100.0%
		Standardized Residual	-1.5	2.6	
	41+	Frequency	216	56	272
		Expected Count	201.9	70.1	272.0
		% within Age	79.4%	20.6%	100.0%
		Standardized Residual	1.0	-1.7	
Total		Frequency	285	9	384
		Expected Count	285.0	99.0	384.0
		% within Age	74.2%	25.8%	100.0%

**Table 8: Chi-Square Tests of age by ocular manifestations**

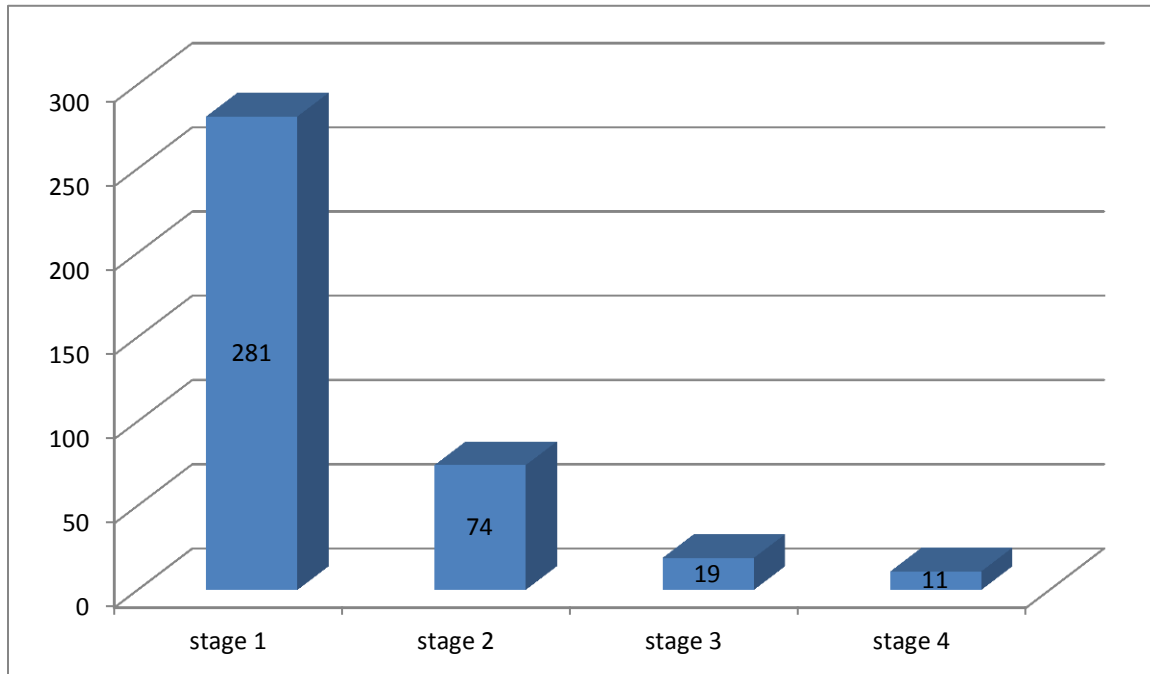
	Value	df	Asymptotic Significance (2- sided)	Exact (2-sided)	Sig. (1-sided)	Exact (1-sided)	Sig. Point Probability
Pearson Square	Chi- 13.143 <sup>a</sup>	1	.0002886	.0003622		.0003039	
Continuity Correction <sup>b</sup>	12.229	1	.0004705				
Likelihood Ratio	12.570	1	.0003919	.0004835		.0003039	
Fisher's Test	Exact			.0004835		.0003039	
Linear-by-Linear Association	13.109 <sup>c</sup>	1	.0002939	.0003622		.0003039	.000
N of Valid Cases	385						
a. 0 cells (0.0%) have expected count less than 5. The minimum expected count is 28.88.							
b. Computed only for a 2x2 table							
c. The standardized statistic is -3.621							

The table above show that age above 40 years was a significantly associated with ocular manifestations

**Table 9: Summary of the study variables analysis**

Study variable	Chi square
Sex	$\chi^2=0.27$ ; df=1; p>0.867
Age	$\chi^2=13.143$ ; df=1; p<0.0002886
HIV stage	$\chi^2=1.266$ ; df=3; p>0.737
CD4 T-cell count	$\chi^2=2.835$ ; df=2; p>0.242

The results were not significant with regard to sex, HIV stage and CD4 T-cell count. The results were significant with regards to age.



**Figure 7: HIV stage and ocular manifestations**

Figure 7 above shows that most of the study participants were in HIV stage 1 and 2. The stage of HIV was not significantly associated with ocular manifestations.

## CHAPTER FIVE: DISCUSSION

### 8.1 Discussion

This study was aimed at finding out the prevalence of ocular manifestations of HIV/AIDS among HIV/AIDS patients, to establish the types of ocular manifestations, and to categorize the common ocular manifestations at the AIDC at the University teaching hospital in Lusaka Zambia. The majority of the participants in this study were females at 64% while males were 36%. Approximately 50.9% of the participants were married. With regard to education level most had attained secondary education 49.6% and the majority of the patients were employed 76.4%.

This study revealed that the prevalence of ocular manifestation in HIV/AIDS patients is high among patients attending the AIDC of excellence at UTH (74%). This is higher than that reported in studies done in the region, in Ethiopia, Nepal and Tanzania where it was recorded at 60%, 38.8% and 41.9% respectively (Assefa et al., 2016; Cunningham Jr and Margolis, 1998; Yusufali et al., 2015). This high prevalence is nevertheless lower than that in a study done in India, where the prevalence rate was 94.2% (Rajkumari et al., 2013.). The high prevalence of ocular manifestations in this study could be due to the fact that most of the patients had not been on HAART for a long enough period. This is consistent with a study done in Ethiopia where patients who were on HAART for a short duration had more ocular manifestations (Amsalu and Nigussie, 2017). The mean time of HAART treatment was only 7.8 months. Even though patients are started on HAART and their CD4 T-cell count increases, the newly formed populations of lymphocytes are not associated with functional maturity of the immune system hence patients are not protected (Jacobson et al., 1997; Turner et al., 1994). Patients in our study were on HAART for an average of 7.8 months. This is not enough time for functional maturity of the immune system as stated by Pakker et al (Pakker et al., 1999), only a few patients demonstrate immune reconstitution close to the normal range after two years.

The anterior segment manifestations were the commonest at 89.6%, followed by posterior segment at 13.5%. The reported high prevalence of anterior segment manifestations in this study

was similar to reports that noted that up to 50.0% of patients with HIV have anterior segment complications (Shukla et al., 2007). In one study done within the region (Tanzania) anterior segment manifestations were reported in 12.5% which is lower than reported in this study (Yusufali et al., 2015).

Keratoconjunctivitis sicca was seen in 50.4% of the patients in this study which was similar to what was reported in a study done in Indonesia which noted that keratoconjunctivitis was seen in 54% (Lestari et al., 2013). It should be noted that few studies have reported on the prevalence of keratoconjunctivitis sicca and for this reason it is not possible to make extensive comparisons and conclude decisively. The exact pathogenesis of keratoconjunctivitis is unknown in HIV patients (Jeng et al., 2007). Research has suggested that this condition is attributed to HIV-mediated inflammation which leads to damage to the accessory and major lacrimal glands (Sahu et al., 2008), and lymphocytic lacrimal gland infiltration (Biswas and Sudharshan, 2008).

Conjunctival microvasculopathy was noted in 27.5% with most patients presenting with sausage and comma shaped vasculopathy. The microvasculopathy although it is thought to be secondary to increased plasma viscosity and immune-complex deposition, the specific etiology is not yet fully known (Copeland and Phillipotts, 2009). This could also be the result of direct infection of the conjunctival vascular endothelium. The prevalence seen in the pre-HAART era was up to 75% (Feich, 1987; Geier et al., 1994; Shuler et al., 1989). The results of this study are higher 50.4% than those seen in Indonesia at 2.9% (Lestari et al., 2013). Bekele et al. 2013 in Ethiopia reported 2.3% of patients having conjunctival microvasculopathy.

Retinal microvasculopathy was seen in 8.8% of the participants in this study. These findings on the retina had no effect on the visual acuity of the affected participants in this current study. This prevalence of retinal microvasculopathy is lower than seen in a study done in India, where it was reported to be 50% (Purushottam et al., 2012). The reason why our study reported a lower prevalence could be that our sample size was small and this calls for a further study with a bigger sample size to be conducted.

Uveitis is one of the early signs of various chronic intra ocular infections seen in HIV/AIDS patients (Govender et al., 2010). Uveitis was present in 6.0% of the patients in our study, and one of these patients had increased IOP secondary to the active uveitis with posterior synechiae.

In a study done in South Korea it was seen in 0.8% of the participants (Kim et al., 2015), while in a study done in India it was noted to be 13% (Upadhyay and Vichare, 2010).

**Table 10: Comparison of results in this study with studies done in other African countries**

<b>Ocular manifestations</b>	<b>Current study</b>	<b>Tanzania study by Sahoo S</b>	<b>Nigeria study by Azinoobi et al</b>	<b>Ethiopia study by Bekele et al</b>
Sample size	385	124	150	348
Prevalence of ocular manifestations	74%	70%	14%	25.3%
Keratoconjunctivitis sicca	50.4%	Not available	Not available	11.3%
Conjunctival microvasculopathy	27.5%	Not available	Not available	2.3%
Retinal microvasculopathy	8.8%	25%	24%	0.6%
Uveitis	6%	8%	24%	0.3%
HZO	2.9%	5%	9.6%	1.2%
CMV-retinitis	2.1%	4.8%	7%	Not available

The table above shows the results of the current study in comparison to studies done in other African countries.

**Table 11: Comparison of results in this study with studies done elsewhere.**

<b>Ocular manifestation</b>	<b>Current study</b>	<b>South Korea study by Kim et al</b>	<b>Indonesia study by Lestari et al</b>
Sample size	385	127	311
Prevalence of ocular manifestations	74%	48%	64%
Keratoconjunctivitis sicca	50.4%	18%	54%
Conjunctival microvasculopathy	27.5%	9.4%	Not available
Retinal microvasculopathy	8.8%	15%	2.9%
Uveitis	6%	0.8%	1.6%
HZO	2.9%	2.4%	Not available
CMV-retinitis	2.1%	3.1%	5.8%

The above table shows the results of this study in comparison to the results seen in other parts of the world.

HZO manifests as painful vesicobullous dermatitis which occurs as a result of reactivation of primary varicella zoster virus infection and could be the first clinical manifestation of HIV infection, as well as pointer in predicting the increased risk for the development of AIDS (Margolis et al., 1998). In our study HZO was noted in 2.9%. This prevalence is much lower than that seen in Nigeria where HZO was reported at 9.6% (Tarilah et al., 2013). The discrepancy in the results could be the different stages of the disease in patients. In these studies, in our study most patients were in stage HIV 1, while in the study by Tarilah et al most patients (85.7%) of their patients were in HIV stage 3.

CMV retinitis was seen in 2.1% of the participants and was the cause of blindness in 76.0% of the patients with CMV. CMV usually presents as necrotizing retinitis with white granular areas and retinal haemorrhages and vasculitis (Culbertson, 1989) also called crumbled cheese and

ketchup appearance. The prevalence in this study is much lower than in the pre-HAART era where 30% of AIDS patients developed CMV retinitis at some point in their life (Varani et al., 2000). The use of HAART is seen to be effective in reducing the rate of CMV (Varani et al., 2000) as is seen in this study. In India a high prevalence of 30.3% was noted (Upadhyay and Vichare, 2010) while in Uganda the prevalence was reported at 8.3% which is also consistent of HAART era. The high prevalence in the study in India could be due to the fact that 36.84% patients had CD4 T-cell count below 50 cells/ $\mu$ L and in our study most patients had CD4 T-cell count above 100 cells/ $\mu$ L.

SCC of the conjunctiva was seen in (6) 1.6% of the participants. The patients underwent surgery of the suspicious lesions and all were confirmed squamous cell carcinoma (SCC insitu) and they continued to be followed up at the eye clinic. In Sub-Saharan Africa the incidence of SCC is seen in 3.8-7.8% of HIV patients, it presents at an earlier age and is more aggressive in HIV patients (Spitzer et al., 2008). And SCC cell is considered to be AIDS defining in younger patients in Sub-Saharan region (Liche et al., 2009)

Cataracts were present in 3.6% of the patients and they were found to cause visual impairment. These were in patients aged between 29-45 years of age and they were referred to the Eye Clinic for cataract surgery and further follow up. Thus it is important to screen HIV/AIDS patients for cataracts. These results are similar to a study done in Tanzania, where the prevalence of cataracts was 4.2% (Yusufali et al., 2015).

Adnexal manifestations seen included herpes simplex infection of the upper eyelids 0.3%. Kaposi sarcoma, 0.3%, seen as a solitary purplish vascular lesion on the lower eyelid, blepharitis, 0.8%, (seen in 3 patients presented with crusting at the lash roots with ulcerations), flat warts 0.5% which presented as disseminated discolored camouflage-like lesions on the whole face, molluscum contagiosum 0.5%. Molluscum contagiosum presents as discrete, elevated, pearly white umbilicated lesions of the eyelids and can be the initial presenting ocular feature of HIV disease (Robinson et al., 1992). It occurs in 1% of HIV patients as extensive disseminated and aggressive course compared to its normal appearance (Calista et al., 1999). The patient in this study with molluscum contagiosum had very extensive lesions affecting eyelids, forehead and part of the cheeks.



In this study there was no significant association between the level of CD4 T-cell count and the ocular manifestation of HIV/AIDS, this is could be due to the fact that most of the patients in this study were HIV stage 1 and 2. Another study needs to be done with two arms, involving patients on HAART and those not on HAART. Age was found to be clinically significant risk factor, as most participants above 40 years of age had ocular manifestations, this is similar with the results found in Tanzania were patients between 31-50 years had ocular manifestations in 68% (Yusufali et al., 2015). This age group is affected most, as it is the group that is more sexually active.

## CHAPTER SIX: CONCLUSION

### 6.1 Conclusion

- The prevalence of ocular manifestations was 74.0% among the HIV/AIDS patients attending AIDC at UTH, Lusaka, Zambia.
- Anterior segment manifestations were the most common seen in 89.6%, followed by posterior segment, 13.5%. Adnexae manifestations were in 6%, while neuro-ophthalmic were seen in 2.2% of the participants.
- The types of ocular manifestations included keratoconjunctivitis sicca, conjunctival microvasculopathy, SCC, KS, HZO, molluscum contagiosum, uveitis, cataracts, CMV-retinitis, toxoplasmosis, retinal microvasculopathy, choroiditis, nerve palsies and optic atrophy.
- Age above 40 years old was associated with high occurrence of ocular manifestations.
- CMV was seen in 2.1% and of those 76.2% were blind due to CMV retinitis.

### 6.2 Recommendations

The study has demonstrated that there is high prevalence of ocular manifestation among HIV/AIDS patients. Therefore the following recommendations:

1. Routine and regular eye checks should be carried out on all HIV/AIDS positive patients.
2. All HIV/AIDS patients with ocular manifestations must be managed promptly.
3. At community, people should be sensitized on the various types of ocular manifestations.
4. Double-armed study is recommended in order to compare the ocular manifestations in HIV stages 1-2 and 3-4.
5. The results of this study may not be applicable countrywide, but provides a reference point for future studies.

### 6.3 Limitations

1. Bias could not have been totally eliminated as the same person sampling was the examiner
2. The examiner new the medical history of the patients before examining them.

## REFERENCES

- Amsalu, A., Nigussie, D., 2017. ocular manifestation and their associated factors among HIV/AIDS patients receiving highly active antiretroviral therapy in southern Ethiopia. *Int J Ophthalmol* 18, 776–781.
- Assefa, Y., Melese, A., others, 2016. Ocular manifestations of HIV/AIDS patients in Gondar University Hospital, north west Ethiopia. *Ethiop. J. Health Dev. EJHD* 20.
- Attili, V., Singh, P., Reddy, A., 2006. Ocular manifestation and Human Immunodeficiency Virus retinopathy in patients with acquired Immunodeficiency syndrome in North India. *Asian J Ophthalmol* 8, 139–142.
- Bekele, S., Gelaw, Y., Tessema, F., 2013. Ocular manifestation of HIV/AIDS and correlation with CD4+ cells count among adult HIV/AIDS patients in Jimma town, Ethiopia: a cross sectional study. *BMC Ophthalmol.* 13, 20. <https://doi.org/10.1186/1471-2415-13-20>
- Biswas, J., Sudharshan, S., 2008. Anterior segment manifestations of human immunodeficiency virus/acquired immune deficiency syndrome. *Indian J. Ophthalmol.* 56, 363–375.
- Calista, D., Boschini, A., Landi, G., 1999. Resolution of disseminated molluscum contagiosum with Highly Active Antiretroviral Therapy (HAART) in patients with Acquired Immunodeficiency Syndrome. *Eur J Dermatol* 9, 211–3.
- Central statistics, 2013. zambia Demographic and Health Survey.
- Charu, J., Malik, V.K., Malik, K.P.S., Kirti, J., Sanjeev, K., Sandeep, K., 2013. Ocular manifestations of AIDS. *J. Adv. Res. Biol. Sci. Peer Rev. Index. Med. J.* 5, 429–435.
- Chisi, S.K., Kollmann, M.K.H., Karimurio, J., 2006. Conjunctival squamous cell carcinoma in patients with human immunodeficiency virus infection seen at two hospitals in Kenya. *East Afr. Med. J.* 83, 267.
- Cho, M., Lu, Z., Lee, C., 2010. This is an Open-Access article distributed under the terms of the Creative Commons Attribution Non-Commercial License.
- Copeland, R., Phillpotts, B., 2009. ocular manifestations of HIV.
- Culbertson, W., 1989. infections of the retina in AIDS. *Int Ophthalmol Clin* 29, 108.
- Cunningham Jr, E.T., Margolis, T.P., 1998. Ocular manifestations of HIV infection. *N. Engl. J. Med.* 339, 236–244.
- Emina, M.O., Odjimogho, S.E., 2010. Ocular problems in HIV and AIDS patients in Nigeria. *Optom. Vis. Sci.* 87, 979–984.
- Feich, S., 1987. conjunctival vascular changes in Acquired Immunodeficiency Syndrome and AIDS-related complex. *Am J Ophthalmol* 103(3 pt 1), 332–3.
- Freeman, W., Lerner, C., Mines, 1995. A prospective study of the ophthalmologic findings in the acquired immune deficiency syndrome. *Am J Ophthalmol* 97, 133–42.
- Geier, S., Klauss, V., Goebel, F., 1994. Ocular microangiopathic syndrome in patients with Acquired Immunodeficiency Syndrome and its relationships to alterations in cell adhesion and blood flow. *Ger J Ophthalmol* 3, 414–21.
- Govender, P., Hansraj, R., Naidoo, K., 2010. ocular manifestation of HIV/AIDS. A literature review. *S Afr Optom* 69, 193–9.
- Holland, G., Pepose, J., Petit, T., 1983. Acquired Immune Deficiency Syndrome. Ocular manifestations. *Ophthalmomolgy* 90, 859–873.
- Jacobson, M., Zegans, M., Pavan, P., 1997. Cytomegalovirus retinitis after the initiation of highly active antiretroviral therapy. *lancet* 349, 1443–5.

- Jeng, B., Holland, G., Lowder, C., 2007. Anterior segment and external ocular disorders associated with Human Immunodeficiency Virus disease. *Surv ophthalmol* 52, 329–368.
- Kanski, J., Bowling, B., 2011. *Clinical Ophthalmology 7th Ed - Kanski.pdf*, 11th ed.
- Kedar, S., Sudhakar, Berger, 2012. The neuro-ophthalmology of HIV-AIDS review of Neurobehavioral HIV Medicine. *Neurobehav. HIV Med.* 99. <https://doi.org/10.2147/NBHIV.S24204>
- Kestelyn, P.G., 2001. HIV/AIDS and blindness.
- Kestelyn, P.G., Cunningham Jr, E.T., 2001. HIV/AIDS and blindness. *Bull. World Health Organ.* 79, 208–213.
- Kim, Y.S., Sun, H.J., Kim, T.H., Kang, K.D., Lee, S.J., 2015. Ocular Manifestations of Acquired Immunodeficiency Syndrome. *Korean J. Ophthalmol. KJO* 29, 241–248. <https://doi.org/10.3341/kjo.2015.29.4.241>
- Lestari, Y.D., Sitompul, R., Edwar, L., Djoerban, Z., 2013. Ocular diseases among HIV/AIDS patients in Jakarta, Indonesia. *Southeast Asian J. Trop. Med. Public Health* 44, 62.
- Liche, F., Kollmann, M.K.H., Mutati, G., 2009. The occurrence and pattern of squamous cell carcinoma of the conjunctiva in HIV/AIDS patients with conjunctival growths seen in two tertiary hospitals in zambia. unpublished.
- Loo, A.V., Sujaya, S., Peyman, M., Florence, S., Subrayan, V., 2011. Retinal manifestations of patients with human immunodeficiency virus, a multiethnics study in Malaysia. *Int. J. Ophthalmol.* 4, 641–643. <https://doi.org/10.3980/j.issn.2222-3959.2011.06.13>
- Margolis, T.P., Milner, M., Shama, A., 1998. Herpes Zoster Ophthalmicus in patients with Human Immunodeficiency Virus infection. *Am J Ophthalmol* 125, 285–91.
- Mowatt, L., 2013. Manifestaciones oftálmicas del VIH en la era de la terapia antiretroviral altamente activa. *West Indian Med. J.* 62, 305–312.
- Otiti-Sengeri, J., Colebunders, R., Kempen, J.H., Ronald, A., Sande, M., Katabira, E., 2010. The prevalence and causes of visual loss among HIV-infected individuals in Uganda. *JAIDS J. Acquir. Immune Defic. Syndr.* 53, 95–101.
- Pakker, N., Kroon, E., Roos, M., 1999. Immune restoration does not invariably occur following long-term HIV-1 suppression during antiretroviral therapy. *AIDS* 13, 203–12.
- Purushottam, J., Thakur, A.K., Choudhary, M., Sharma, S., Shah, D.N., 2012. Ocular Manifestations in HIV Positive and AIDS Patients in Nepal. *Int. J. Clin. Med.* 03, 14–21. <https://doi.org/10.4236/ijcm.2012.31003>
- Rajkumari, V., Singh, K.K., Devi, B.R., Singh, O.T., Devi, S.N., Nongthongbam, T., 2013. Ocular manifestations of Human Immunodeficiency Virus/Acquired Immune deficiency syndrome in Manipur.
- Robinson, M., Udell, I., Garber, P., 1992. Molluscum contagiosum of the eyelids in patients with Acquired Immunodeficiency Syndrome. *Ophthalmology* 99, 1745–7.
- Sahoo, S., 2010. HIV- and AIDS-related Ocular Manifestations in Tanzanian Patients. *Malays. J. Med. Sci. MJMS* 17, 12–16.
- Sahu, D., Namperumalsamy, P., Walimbe, P., 2008. Ocular manifestations of HIV infection/AIDS in South Indian patients. *Indian J Ophthalmol* 47, 79–85.
- Shukla, D., Rathinam, S., Cunningham Jr, E., 2007. Contribution of HIV/AIDS global Blindness. *Int Ophthalmol Clin* 47, 27–43.
- Shuler, J., Engstrom, R.J., Holland, G., 1989. External ocular disease and danterior segment disorders associated with Acquired Immunodeficiency Syndrome. *Int Ophthalmol Clin* 29, 98–104.
- Spitzer, M., Batumba, N., Chirambo, T., 2008. Ocular surface squamous neoplasia as the first apparent manifestation of the HIV infection in Malawi. *Clin Experiment ophthalmol* 36, 422–5.

- Tarilah, T., Ezenwa, U., Ifeanyi, A.R., others, 2013. Ocular manifestation of HIV/AIDS infection among patients receiving highly active anti retro viral therapy (HAART) in a tertiary eye care centre. *J. AIDS HIV Res.* 5, 322–327.
- Turner, B., Hecht, F., Ismail, R., 1994. CD4+T-lymphocyte measure in the treatment of individuals infected with human immunodeficiency virus type 1; a review for clinical practitioners. *Arch Intern Med.*
- Upadhyay, A.K., Vichare, N., 2010. Ocular lesions associated with human immunodeficiency virus infection. *Med. J. Armed Forces India* 66, 235–238.
- Varani, S., Spezzacatena, P., Manfredi, R., 2000. The incidence of cytomegalovirus (CMV) antigenemia and CMV disease is reduced by highly Active Anti-retroviral Treatment. *Eur J Epidemiol* 16, 433–7.
- Verma N, Kearney J. ocular manifestations in AIDS. pdf - Google Search [WWW Document], n.d. URL  
[https://www.google.co.zm/search?q=Verma+N%2C+Kearney+J.+ocular+manifestations+in+AIDS.+pdf&rlz=1C1SAVU\\_enZM643ZM644&oq=Verma+N%2C+Kearney+J.+ocular+manifestations+in+AIDS.+pdf&aqs=chrome..69i57.35476j0j9&sourceid=chrome&ie=UTF-8](https://www.google.co.zm/search?q=Verma+N%2C+Kearney+J.+ocular+manifestations+in+AIDS.+pdf&rlz=1C1SAVU_enZM643ZM644&oq=Verma+N%2C+Kearney+J.+ocular+manifestations+in+AIDS.+pdf&aqs=chrome..69i57.35476j0j9&sourceid=chrome&ie=UTF-8) (accessed 2.3.17).
- WHO media centre, 2015. WHO facts sheet no. 360, HIV/AIDS.
- Yusufali, M., Mafwiri, M.M., Sanyiwa, A.J., 2015. Ocular manifestation among HIV/AIDS patients; a case of muhimbili national Hospital. *J Ophthalmology Eastern, Central and southern Africa* 19.

## APPENDICES

### Appendix I: Patient information sheet

I, Phyllis Moonga, a master of medicine in ophthalmology student in the school of medicine at the University of Zambia, hereby request your participation in the above mentioned study. I would like you to fully understand the purpose of this study and what is expected of you. Kindly note that there is no monetary gain in this study, participation in this study is absolutely voluntary, you are free to refuse to answer questions you deem too personal or otherwise. You are also, free to refuse participation in the study and may withdraw at anytime without any consequences. If you agree to participate in this study you will be asked to sign a consent form, and I will require some information from you, like your age, level of education, sex, marital status. Your medical records will be used to get information on, systemic diseases, CD4-Tcell count, duration of HAART and WHO staging of HIV.

HIV/AIDS affect any part of the eye, some of these diseases you may see in the eyes are: Dry eyes ( this usually gives a sandy sensation in the eyes and there is tearing), Kaposi's Sarcoma, varies cancers, herpes zoster, cytomegalovirus retinitis( it's a viral infection that affect the back of the eye, and leads to blindness if not seen in time and treated appropriately) it is important to have regular eye checks once per year, so that if you have any ocular disease it could be treated appropriately. If you feel that your sight is going down, you should immediately seek medical attention.

Thereafter I will examine your eyes here at AIDC. First I will check you sight, this will be done using some special chart, which are put at a distance of 6 meters from you and you will be sitting in a well lit area. Then the front part of your eyes will be examined with a pen touch and by a special microscope, then I will check how much tears your eyes are producing (dry eyes is one of the most common ocular manifestation of HIV/AIDS) using special pieces of paper called tear strips. After this, I will add some more drops, this are for opening the pupils, so that I examine the back of the eye. The back of eye will be examined using the microscope of the eye and indirect ophthalmoscope. The drops may course some tingling sensation and after the eyes open, you may experience a feeling of too much light entering your eyes. The feeling of too much light in the eyes will last for 4 hours. The ophthalmoscope has a very bright light and this may cause some discomfort, but it is not harmful for your eyes.

The benefit of this study to you, whether you agree to participate or not are: if you have any ocular manifestations of HIV/AIDS e.g. cancer appropriate investigations and treatment will be initiated immediately. If you don't have any ocular manifestation, you will be aware of various ocular effects HIV/AIDS on the eyes, such that you or anyone you know develops them, you will be able to seek early and appropriate intervention.

The findings of the examinations will be communicated to you, if you need treatment, you will be advised. The results from the laboratory where necessary, will be communicated to you and any further treatment if needed will be advised and initiated appropriately.

All the information collected is strictly confidential. Information that will be collected will not include your name and therefore cannot be traced to you.

Your participation in this study is absolutely voluntary.

I'm grateful to you for considering participation in this study.

For concerns and clarifications please contact:

Dr Phyllis Moonga or the University of Zambia Biomedical Research Ethics Committee on the following addresses:

Dr. Phyllis Moonga,

University Teaching Hospitals,

Private Bag RW 1X,

Lusaka, Zambia

Phone: +260979575675

E-mail: phyllmm@yahoo.co.uk

Or

Dr G Chipalo-Mutati

University Teaching Hospitals

P/Bag RW 1X,

Lusaka, Zambia.

Phone: +260977345944

E-mail:gcm.mutati@gmail.com

Or

The Chairperson  
Biomedical Research Ethics Committee (UNZABREC),  
The University of Zambia  
School of medicine,  
Ridgeway Campus,  
P.O Box 50110  
Lusaka, Zambia  
Phone: 260-1-256067  
E-mail: unzarec@unza.zm



**Appendix II: Consent form**

I, -----, do hereby confirm that the nature of this clinical study has been sufficiently explained to me. I'm aware that there is no monetary gain and that my personal details will be kept confidential. And that I may voluntarily, at any point withdraw my participation from the study without any consequence, and I'm free to skip questions that I deem too personal or otherwise. I have been given sufficient time to ask questions and clarifications, and of my own free I declare my participation in this study. I have also received a signed copy of this agreement.

-----	-----	-----
Name of participate	signature/thumb print	Date

-----	-----	-----
Witness	signature/ thumb print	Date

## **Appendix I**

### **PEPALA YA DZIWITSO KWA ODWALA PA PHUNZILO LA; ZOPEZEKA MU MASO YA ODWALA HIV/AIDS KU AIDC YA PA UTH MU LUSAKA, ZAMBIA.**

Ine Phyllis Moonga wa pamaphunzilo ya pa mwamba yona pa za maso mu University of Zambia, sukulu ya madotolo, nipempha kuti mutengeko mbali mu maphunzilo yalembedwa pa mwamba. Nifuna kuti mudziwe chilingo cha ma phunzilo ya kafukufuku ndi zamene zizayembekezeka kuchokela kwa imwe. Chonde mudziwe kuti muma phunzilo awa mulibe phindu la ndalama, ndipo kutengako mbali ni mwa ufulu ozifunila. Komanso mukhoza kuleka kutengako mbali pa nthawi ili yonse mukafuna, komanso mukhoza kukana ku yankha mafunso yamene muona monga alowapo ngako pa za umoyo wanu wobisika. Ngati muzabvomela kutengako mbali mumaphunzilo awa, muzapemphedwa ku saina pepela ya chilolezo ndipo ndiza funako kudziwa zina zaimwe monga zaka zanu zobadwa, pomwe munafika sukulu, kuti ndimwe amuna kapena akazi, mu ukwati kapena yayi. Chi kadi chanu cha kuchipala chizatipatsako zina pa imwe monga matenda ena yamuthupi, nambala ya CD4, nthawi yamene mwakhala pa ma ARVs komanso stegi ya matenda kulingana na WHO.

Matenda ya HIV / AIDS yamapezeka mu mbali zonse za maso. Matenda ena yopezeka mu maso di awa; kuuma m' maso (nthawi yambiri kumvera monga m' maso mwalowa mchenga nakuchotsa misozi), Kaposi sarcoma na makhansa yosiyanasiyana yamene yamaononga ku mbuyo kwa maso kotero kuti ngati simuonewa ndi kuthandiziwa mwa msanga, maso ya kufa ndipo mukhala akhungu kapena akufa maso. Nichofunika kuti maso anu akazionewa pafupipafupi monga kamodzi pa chaka kuti ngati mwapezewa na bvuto kapena matenda ya m' maso, muthandidziwe mwamsanga munjira yoenela. Ngati muona kuti maso ya yamba kubvuta, mupite ku chipatala mwa m' sanga kuti muthandizike.

Pambuyo pake, ndizakupimani m' maso ku AIDC. Poyamba ndiza pima mwamene muyang'anira, pakugwiritsa nchito chi pepala chamene chizaikiwa pa 6 mita pa tsogolo panu mu malo owala bwino. Maso yanu yazapimidwa ndi ka laiti ndi microscope, pambuyo pake muzaikiwa mankwala m' maso kuti tione misozi yotulukamo (kuuma m' maso ndi matenda ya modzi yopezeka pafupipafupi mu HIV/AIDS). Pa mbuyo pake, nizaikamo twina tumankwala

kuti mutsegule maso kuti nipime kumbuyo kwa maso ndi microscope ya maso komanso ophthalmoscope. Tumankwala twa m'maso tungakumvetseni kunyereza kapena kuwawila pang'ono potsegula maso. Muzamvera monga laiti yachuluka monga nyengo ya ma ola 4 chifukwa laiti ya ophthalmoscope kapena chopimila maso ni yochulukirapo, koma siononga maso.

Phindu yamaphunzilo awa, olo mutengeko mbali olo yayi, niyakuti, ngati muzapezewa na bvuto ya m'maso ya HIV/AIDS, muzathandiziwa mwansanga, ngati mulibe, muzadziwa za matenda ya m'maso ya HIV/AIDS. Komanso muzadziwa pa inu nokha kapena kudziwitsa anzanu za matenda a m'maso kuti ngali ya bwela, mukafune thandizo mwamsanga kuchipatala. Muzauziwa zopezeka popimiwa ndipo ngati muzapezeka na bvuto kapena matenda ya m'maso, muzapatsiwa thandizo yoyenela.

Zopezeka mu maphunzilo awa zizasunguwa mwachisinsi. Dzina lanu sizatengewa kotelo kuti musakadziwike. Kutengako mbali mu maphunzilo awa ni moziipeleka. Niyamika kuti mwa bvomela kutengako mbali mu maphunzilo awa.

Ngati muzakhala na mafunso yaliyonse, mufunse a Dr Phyllis Moonga olo Aku University of Zambia Biomedical Research and Ethics Committee pama keyala yopatsidwa pansu;

Dr. Phyllis Moonga,  
University Teaching Hospital,  
Private Bag RW 1X,  
Lusaka, Zambia  
Phone: +260979575675  
E-mail: [phyllmm@yahoo.co.uk](mailto:phyllmm@yahoo.co.uk)

Or

Dr. G. Chipalo-Mutati  
University Teaching Hospital  
P/Bag RW 1X,  
Lusaka, Zambia.  
Phone: +260977345944  
E-mail: [gcm.mutati@gmail.com](mailto:gcm.mutati@gmail.com)

Or

The University of Zambia  
Biomedical Research Ethics Committee (UNZABREC),  
School of medicine,  
Ridgeway Campus,  
P.O Box 50110,  
Lusaka, Zambia  
Phone: 260-1-256067  
E-mail: unzarec@unza.zm

## Appendix II

### PEPELA YA CHILOLEZO

Ine-----, nibvomela kuti nauzidwa mbali zonse za maphunzilo aya yakafukufuku. Nadziwa kuti palibe phindu ya ndalama ndipo zaine zizasungwa mwachisinsi. Nikhoza kulekeza panjira kutengako mbali mumaphunzilo aya nthawi iliyonse ngati nafuna popanda chifukwa chilichonse ndipo ndine omasuka kusiya kapena kusayankha mafunso ena yamene sinimasuka nayo. Napatsiwa nthawi yokwana bwino kuti nifunsepo mafunso. Mwaine nekha komanso modziwa, ndizipeleka kutengako mbali mu maphunzilo yakafukufuku aya. Nalandila pepela yosainiwa ya kubvomela

kwanga.

-----	-----	-----
Dzina la otengako mbali	kusaina/kudinda na chala	Tsiku
-----	-----	-----
Ochitira umboni	kusaina/kudinda na chala	Tsiku

## Appendix III: Questionnaire

### A. Demographic data

1. File number \_\_\_\_\_
2. Age \_\_\_\_\_
3. Sex M [ ] F [ ]
4. Marital status: Married [ ] Single [ ] widow/er [ ] Divorced [ ]
5. Highest level of education attained. Primary [ ] Sec [ ] Tert [ ]
6. Occupation \_\_\_\_\_
7. Residential area \_\_\_\_\_

### B. Medical records

1. HAART yes [ ] no [ ]
2. If yes, duration [ ]
3. Most recent CD4-Tcell count \_\_\_\_\_
4. WHO HIV stage \_\_\_\_\_

### C. Ocular examination

1. VA best corrected with pinhole
  - a. Normal vision [ ]
  - b. Visual impairment [ ]
  - c. Severe visual impairment [ ]
  - d. Blindness [ ]
2. Pupillary reaction
  - a. Round and reacting to light
  - b. Not reacting to light
3. EOM
  - a. Free [ ]
  - b. Restricted [ ]

4. IOP

a. Normal [ ]

b. high [ ]

5. Adnexal manifestations (eyelids)

a. HZO: Yes [ ] No [ ]

b. HS: Yes [ ] No [ ]

c. KS: Yes [ ] No [ ]

d. SCC: Yes [ ] No [ ]

e. Others \_\_\_\_\_

6. Anterior segment manifestations

a. KCS of conjunctiva Yes [ ] No [ ]

b. SCC of conjunctiva: Yes [ ] No [ ]

c. KS of conjunctiva Yes [ ] No [ ]

d. Conjunctival microvasculopathy: Yes [ ] No [ ]

e. Corneal changes.....

f. Uveitis: Yes [ ] No [ ]

g. Others \_\_\_\_\_

7. Posterior segment manifestation

a. Retinal microvasculopathy: Yes [ ] No [ ]

If yes indicate findings: \_\_\_\_\_

b. Papillitis: Yes [ ] No [ ]

c. CMV retinitis: Yes [ ] No [ ]

d. Toxoplasmosis: Yes [ ] No [ ]

e. Choroiditis: Yes [ ] No [ ]

g. others \_\_\_\_\_

8. Neuro-ophthalmology manifestations

a. Nerve palsy: Yes [ ] No [ ]

b. Optic atrophy Yes [ ] No [ ]

#### **Appendix IV: WHO visual impairment classification**

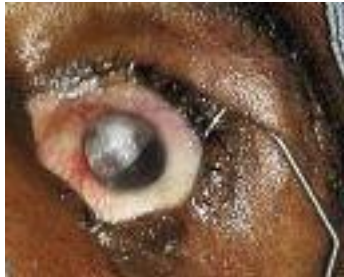- |                             |            |
|-----------------------------|------------|
| 1. Normal vision            | 6/6-6/18   |
| 2. Visual impairment        | <6/18-6/60 |
| 3. Severe visual impairment | <6/60-3/60 |
| 4. Blindness                | <3/60      |



## **Appendix V**

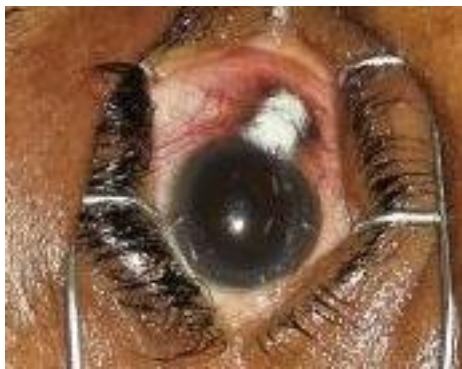### **Photographs showing some of the encountered ocular manifestations**

#### **Image 1**



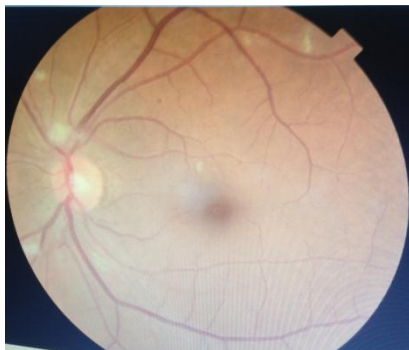The image above is of a male aged 45 years who noticed a whitish growth in his left eye for 4 months. He underwent excision biopsy and the histopathology result confirmed SCC.

#### **Image 2**



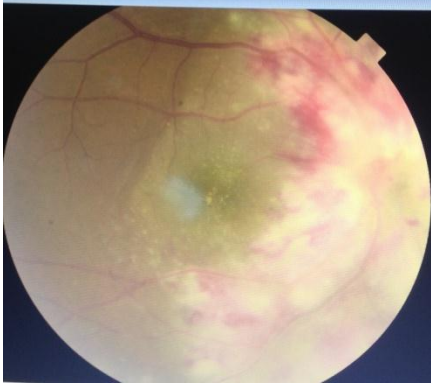
This is an image of the right eye of a female aged 55years, who had this growth in the right eye for 5months. Excision was done and it confirmed SCC on histopathology.

#### **Image 3**



The fundus image of a 52 year old female showing HIV retinopathy (cotton wool spots)

#### Image 4



The image above depicts the fundus of a 46 year old male with CMV retinitis; the patient was treated with Intravitreal Ganciclovir.

**Note:** All photos were taken with consent by Dr Phyllis Moonga