

Assessment of Transvenous Right Atriography in the Diagnosis of Pericardial Effusion

Dr. B. C. Umerah, MB., B. CH., BAO (Belf), DMRD, FRCR & Dr. I.Y.E. Yikona,
B. Sc., MB, Ch.B (UNZA) Dept. of Radiology U.T.H. Lusaka.

(Received for publication: 21st May 1976)

SUMMARY

From our results, we feel that transvenous right atriography is a reliable confirmatory investigation of pericardial effusion. The procedure is simple and can be carried out in any hospital. Spurious positive results may arise from faulty technique or due to

marked pericardial thickening whilst false negatives may be encountered with viscid, inspissated or loculated pericardial effusion.

INTRODUCTION

There is no absolute sign of pericardial effusion in the plain chest radiograph. Very suggestive features

like alteration of cardiac configuration with posture, including filling in of the vascular pedicle in the supine position, can be seen in for example gross cardiac failure.

Diminution of the amplitude of cardiac pulsation (fluoroscopy) is not pathognomonic and can be seen in gross cardiac failure, cardiomyopathy and Ebstein's anomaly.

Whilst echography, intracardiac contrast examination, right atriopneumography (with carbon dioxide) are reliable confirmatory investigations, special care, skill and equipment are required.

Transvenous right atrigraphy is an old simple method of delivering positive contrast into the right atrium (Kreel, 1971). It was also described in a paper read to the East and Central African Physicians Association in Lusaka 1971 by Dr. Cameron of Kenyatta National Hospital, Nairobi. The value of this procedure in the diagnosis of pericardial effusion is presented.

MATERIAL & METHOD

Of the 33 patients referred to us for this investigation there were three children aged 10, 12 and 13 years. The adult age range was between 25-50 years. No significance was attributed to the sex distribution.

Procedure

A plain posterior-anterior film of the chest is taken with the patient lying on the right side. The X-Ray tube is operated from the horizontal position so that the beam is tangential to the patient (ie. the right horizontal decubitus position). A grid cassette is normally used to enhance definition, which has to be sharp to delineate the cardiac or pericardial outline. Using an 18 SWG canula, a high density contrast medium (conray 420) is rapidly delivered into an antecubital vein and three sequential films taken. The first film is taken when two-thirds of the contrast has been delivered and subsequent films taken at 3 second intervals.

Criteria for Diagnosis

Absolute:- Separation of over 1cm between the margin of the right atrium and the outer edge of the cardiac shadow, represents significant pericardial effusion or gross thickening of the pericardium.

Relative

- (a) Reflux of contrast into the great veins.
- (b) Convexity of the contrast margin in the right atrial wall.

RESULTS

The results are summarised in tables 1, 2 and 3 of the 33 patients studied. 12 showed a separation of over 5 mm between the right atrial wall (i.e the margin of the contrast medium) and the outer border of the cardiac shadow. Of these 8 showed a separation of over 1cm and in 4, the separation was less than

TABLE I

Total number of patients examined right atriograms	33
Number showing separation of contrast layer from dependent margin of cardia shadow	12
Number of right atriographs in which contrast layer formed the most dependent margin	21

TABLE II

Number of atriographs showing separation of contrast layer from the right (dependent) cardio pericardial border	12
No showing separation of over 1cm	8
Number showing separation less than 1 cm	4

TABLE III

False Positive	False Negative
1	1

1cm. The remaining 21 showed no separation. There was 1 false positive and 1 false negative.

DISCUSSION

The examination is done in the right lateral decubitus position in order to facilitate gravitation of pericardial effusion to the most dependent part and in this position there is maximal separation between the right atrium and the parietal pericardium in the presence of pericardial effusion. Using a high density contrast medium "streaming" is accentuated due to gravity and the margin of the right atrium is usually sharply outlined.

We consider a minimal separation of 1cm as an absolute sign of pericardial collection. This may however be due to gross pericardial thickening which may be seen in constrictive pericarditis.

In our criteria for diagnosis, we included convexity of the outer margin of the right atrium in pericardial effusion (Kreel,1971). We consider this sign as invalid and misleading since over 50% of our cases with pericardial effusion showed a straight right atrial border, normally described in pericardial thickening (Kreel,1971).

Reflux filling of the great veins occurs in any condition where there is increase of the filling pressure of the right atrium and is therefore not a useful diagnostic sign.

In our opinion the false positive result was partly due to rotation, for example in the left anterior border of the right ventricle forms a continuous straight line with the ascending aorta (Meschan, 1959 and personal observation). In this position, the measurement is no longer valid.

The false negative was found in a 12 year Indian girl who had a suppurative staphylococcal pericardial effusion with cardiac tamponade. Whilst grossly dilated veins were a marked feature reflecting the severity of the increase of the filling pressure, the contrast margin did not show any separation from the periphery of the cardiac silhouette. On the other hand, the pulmonary conus and left heart border were filled out. We suggest that the pus did not gravitate easily due to viscosity of inspissation. The condition was diagnosed by paracentesis and confirmed at necropsy.

Fig. 1 shows separation of the atrial wall from the parietal pericardium in a case of pericardial effusion.

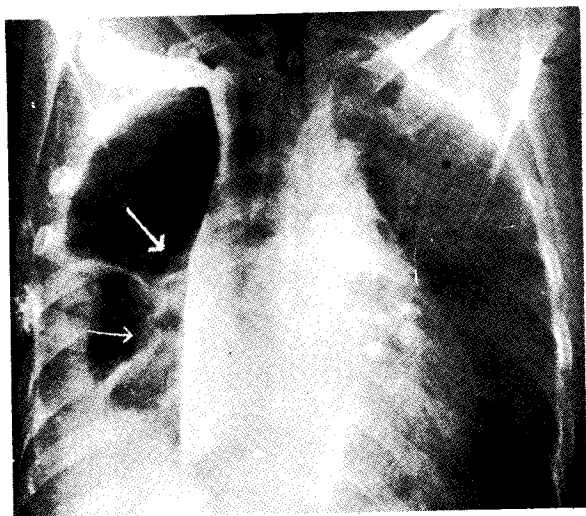
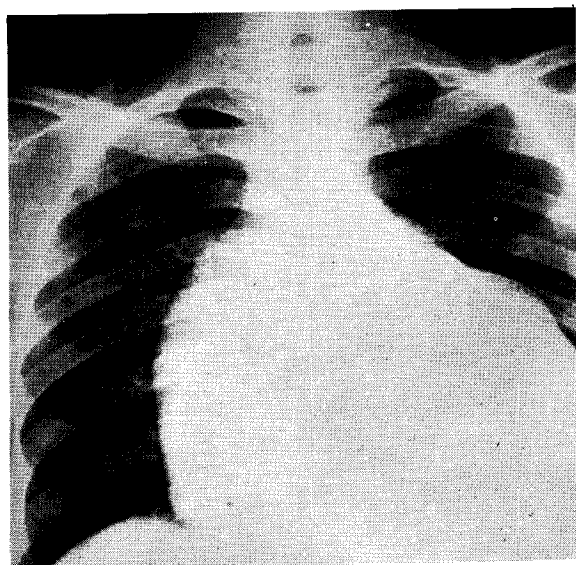


Fig. 2A is a plain chest radiograph showing a grossly enlarged heart, provisionally diagnosed as a case of pericardial effusion.

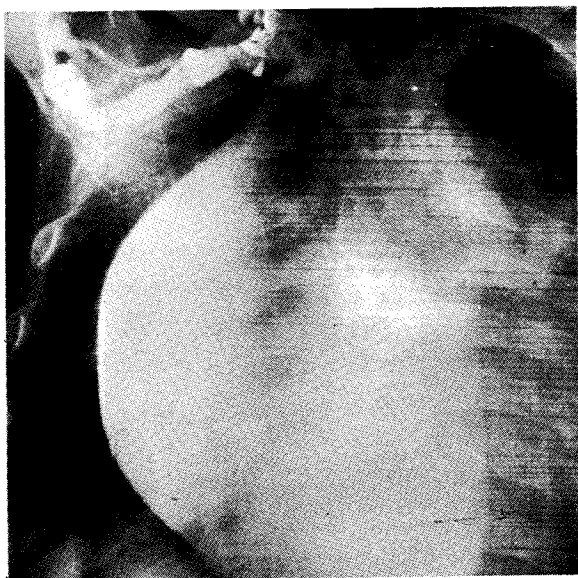

Fig. 2B the same case after injection of contrast medium showing no separation of the atrial wall from the pericardium to suggest an effusion. The arrows point at the edge of the pericardium.



REFERENCES

- CAMERON — *Personal Communication*, 1975.
- KREEL, Louise — *Outline of Radiology Heinemann* 1971, Page 54.
- MESCHAN, Isadore — *Normal Radiographic Anatomy* 2nd edition. 1959. Page 538.

ACKNOWLEDGEMENT

We thank Miss E.J. Phiri for typing the script and the Department of Medical Illustration for the photographs.